


---

**U.S. ARMY MEDICAL DEPARTMENT CENTER AND SCHOOL  
FORT SAM HOUSTON, TEXAS 78234-6100**

---



# **STANDARD POSITIONING TECHNIQUES I**

**SUBCOURSE MD0961    EDITION 200**

## **DEVELOPMENT**

This subcourse is approved for resident and correspondence course instruction. It reflects the current thought of the Academy of Health Sciences and conforms to printed Department of the Army doctrine as closely as currently possible. Development and progress render such doctrine continuously subject to change.

## **ADMINISTRATION**

Students who desire credit hours for this correspondence subcourse must enroll in the subcourse. Application for enrollment should be made at the Internet website: <http://www.atrrs.army.mil>. You can access the course catalog in the upper right corner. Enter School Code 555 for medical correspondence courses. Copy down the course number and title. To apply for enrollment, return to the main ATRRS screen and scroll down the right side for ATRRS Channels. Click on SELF DEVELOPMENT to open the application; then follow the on-screen instructions.

For comments or questions regarding enrollment, student records, or examination shipments, contact the Nonresident Instruction Branch at DSN 471-5877, commercial (210) 221-5877, toll-free 1-800-344-2380; fax: 210-221-4012 or DSN 471-4012, e-mail [accp@amedd.army.mil](mailto:accp@amedd.army.mil), or write to:

NONRESIDENT INSTRUCTION BRANCH  
AMEDDC&S  
ATTN: MCCS-HSN  
2105 11TH STREET SUITE 4191  
FORT SAM HOUSTON TX 78234-5064

Be sure your social security number is on all correspondence sent to the Academy of Health Sciences.

## **CLARIFICATION OF TERMINOLOGY**

When used in this publication, words such as "he," "him," "his," and "men" are intended to include both the masculine and feminine genders, unless specifically stated otherwise or when obvious in context.

## **USE OF PROPRIETARY NAMES**

The initial letters of the names of some products may be capitalized in this subcourse. Such names are proprietary names, that is, brand names or trademarks. Proprietary names have been used in this subcourse only to make it a more effective learning aid. The use of any name, proprietary or otherwise, should not be interpreted as endorsement, deprecation, or criticism of a product; nor should such use be considered to interpret the validity of proprietary rights in a name, whether it is registered or not.

## TABLE OF CONTENTS

<b><u>Lesson</u></b>		<b><u>Paragraphs</u></b>
	INTRODUCTION	
1	BODY MECHANICS, PATIENT HANDLING, AND POSITIONING	
	Section I. Protecting Your Back	1-1—1-8
	Exercises	
	Section II. Moving and Transporting the Patient	1-9—1-20
	Exercises	
2	THE ORDER OF PROCEDURE	
	Section I. Order of Procedure (Steps 1 and 2)	2-1—2-7
	Exercises	
	Section II. Order of Procedure (Step 3 through 5)	2-8—2-10
	Exercises	
3	POSITIONING TERMINOLOGY	
	Section I. General Terms and Body Part Terms	3-1—3-6
	Exercises	
	Section II. Positioning and Projection Terminology	3-7—3-20
	Exercises	
	Section III. Projection, Central Ray, and Breathing Technique Terminology	3-21—3-23
	Exercises	
4	FILM IDENTIFICATION AND CAPTIONING	
	Section I. The X-ray Request Form	4-1—4-9
	Exercises	
	Section II. Film Identification	4-10—4-13
	Exercises	
5	POSITIONING FOR EXAMS OF THE UPPER EXTREMITIES	
	Section I. Radiographic Projection of the Hand	5-1—5-8
	Section II. The Wrist and Forearm	5-9—5-14
	Section III. The Elbow	5-15—5-16
	Section IV. The Humerus	5-17—5-18
	Section V. The Shoulder	5-19—5-21
	Section VI. The Scapula	5-22—5-23
	Section VII: The Clavicle and Acromioclavicular Joints	5-24—5-25
	Exercises	
	APPENDIX, GLOSSARY OF TERMS	

**CORRESPONDENCE COURSE OF  
THE U.S. ARMY MEDICAL DEPARTMENT CENTER AND SCHOOL**

**SUBCOURSE MD0961**

**STANDARD POSITIONING TECHNIQUES I**

**INTRODUCTION**

As an X-ray technologist, positioning the patient is one of the most routine, yet critical, aspects of your job. You may have to position up to fifty patients in the course of any given day. Though you may come close to knowing the steps for positioning a patient almost without thinking, you should never let positioning procedures become a mindless part of your job. Failure to position a patient correctly could cause harm to the patient. It could also involve the hospital and/or health care team in needless litigation. If you fail to position the patient correctly for a particular study, the radiologist may end up with an incomplete study and, thus, inadequate or inaccurate information to formulate a valid diagnosis.

If you fail to take proper precautions in handling, moving, and/or positioning the patient, you may contribute to a slip-and-fall injury or a radiation therapy injury, two of the four principal categories of patient injuries and the cause of malpractice suits in the radiology department. Therefore, although you may position many patients in a given day or week, you must never let the steps of the various positioning procedures become rote or mechanical. You must think about and put all of your attention into what you are doing at all times.

**Subcourse Components:**

The subcourse instructional material consists of five lessons and a glossary as follows:

- Lesson 1, Body Mechanics, Patient Handling, and Positioning.
- Lesson 2, The Order of Procedure.
- Lesson 3, Positioning Terminology.
- Lesson 4, Film Identification and Captioning.
- Lesson 5, Positioning for Exams of the Upper Extremities.
- Appendix, Glossary of Terms.

Here are some suggestions that may be helpful to you in completing this subcourse:

--Read and study each lesson carefully.

--Complete the subcourse lesson by lesson. After completing each lesson, work the exercises at the end of the lesson, marking your answers in this booklet.

--After completing each set of lesson exercises, compare your answers with those on the solution sheet that follows the exercises. If you have answered an exercise incorrectly, check the reference cited after the answer on the solution sheet to determine why your response was not the correct one.

**Credit Awarded:**

Upon successful completion of the examination for this subcourse, you will be awarded 12 credit hours.

To receive credit hours, you must be officially enrolled and complete an examination furnished by the Nonresident Instruction Branch at Fort Sam Houston, Texas.

You can enroll by going to the web site <http://atrrs.army.mil> and enrolling under "Self Development" (School Code 555).

A listing of correspondence courses and subcourses available through the Nonresident Instruction Section is found in Chapter 4 of DA Pamphlet 350-59, Army Correspondence Course Program Catalog. The DA PAM is available at the following website: <http://www.usapa.army.mil/pdffiles/p350-59.pdf>.

## LESSON ASSIGNMENT

### LESSON 1

Body Mechanics, Patient Handling, and Positioning.

### LESSON ASSIGNMENT

Paragraphs 1-1 through 1-20.

### LESSON OBJECTIVES

After completing this lesson, you should be able to:

- 1-1. Identify definitions of the base of support, center of gravity, and body mechanics.
- 1-2. Identify general rules for lifting and carrying heavy objects.
- 1-3. Identify criteria for assessing patient mobility.
- 1-4. Identify procedures for moving a patient who is able/unable to assist from:
  - a. Wheelchair to X-ray table.
  - b. Stretcher to X-ray table.
- 1-5. Identify procedures for positioning a patient in the supine, lateral, and prone positions.
- 1-6. Identify special precautions for handling trauma patients, and patients with casts.

### SUGGESTION

After reading and studying the assignment, complete the exercises at the end of this lesson. These exercises will help you to achieve the lesson objectives.

## LESSON 1

### BODY MECHANICS, PATIENT HANDLING, AND POSITIONING

#### Section I. PROTECTING YOUR BACK

##### 1-1. INTRODUCTION

a. According to registered occupational therapist, Kathryn Ryan, in 1989, work-related injuries in California reached "epidemic proportions" (over 370,000 injuries were reported, with 100,000 back-related). Ryan says that the combined occurrence of back pain at work and home means that "eight out of ten of us will suffer back pain sometime in our lives".

b. Common injuries, such as acute sprains and strains, cause back injury. Everyday stress and wear and tear can cause chronic muscle and joint strain that slowly builds up. Actual case load and specific duties play a role in the incidence of back injury. But, the job of a radiologic technologist (RT) is somewhere in the middle as compared to other jobs for susceptibility to back injury (somewhere between light office work and heavy labor).

c. Most back injuries affect the discs, cushions of the spine, ligaments connecting the vertebra, and muscles of the lumbar area. Bad habits like excessive bending can weaken the wall of the back discs causing disc strain or bulge." The worst problem, nucleus protrusion; can require surgery. Protrusion occurs when the disc nucleus projects beyond the discs outer shell and onto the spinal cord or nerve roots. Loss of bladder control and paralysis can result. Bad posture, poor body mechanics, high stress, poor physical condition, and erratic sleep habits increase the risk of back injury. Bad posture can cause you back pain. Soft mattresses do not support the spine. Sleeping on your stomach can strain the neck and back

##### 1-2. AN OUNCE OF PREVENTION

a. **Avoiding Injury and Lawsuits.** As stated earlier slip-and-fall injuries, which account for malpractice suits in the radiology department, are one category of injury which the radiologic technologist often has direct responsibility. You do not want to be responsible for malpractice suits. So, you must do your best to prevent injury while moving or lifting the patient, especially when the patient needs assistance. By preventing injuries resulting from negligence, you will also help reduce the number of malpractice suits in the radiology department.

b. **Avoiding Injury to Oneself.** Patients are not the only ones who incur injury in the radiology department; technologists also suffer injury themselves, especially through abuse of the spine. You are most likely to do this while lifting or moving a patient. Have you ever tried to lift a 350-pound patient? You may suffer injury if you fail to apply the principles of good body mechanics in performing tasks that require stooping, lifting, pushing, pulling, and carrying. The injury will not only cause you discomfort, but it will cause you to function at a reduced level of efficiency. This will place a greater burden on your colleagues or even result in injury to the patient.

c. **The Importance of Good Body Mechanics.** For the reasons stated above, you must know and apply the principles of good body mechanics, which include proper body alignment, proper movement, and proper use of balance. Doing so will help minimize patient injury and costly litigation that may result, as well as injury to yourself. This lesson outlines key concepts of body mechanics and patient handling.

NOTE: Body mechanics is the safe and efficient use of the body in movement.

### 1-3. BODY ALIGNMENT

a. **Lining Up the Major Body Parts.** Correct body alignment is essential to the safe and efficient use of good body mechanics. As the term suggests, good alignment means lining up the major body segments (pelvis, thorax, and head) in proper relationship to one another. When body segments are properly lined up, it becomes easier to maintain body balance (see figure 1-1). With good balance, the body is stable, and steady. Thus, you are less likely to tip over or fall.

NOTE: Body alignment is the lining up the pelvis, thorax, and head in proper relationship to each other so as to maintain body balance.

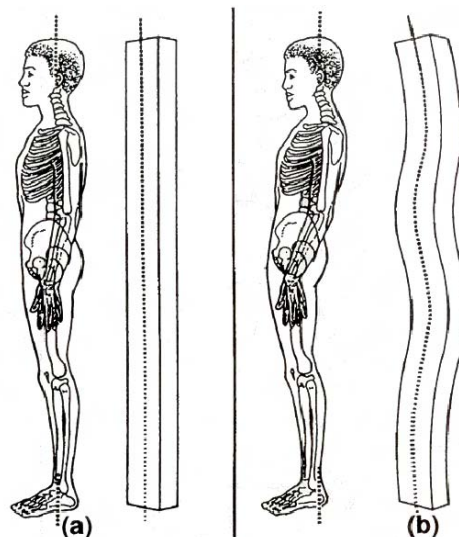


Figure 1-1. (a) Good alignment—pelvis, thorax, and head lined up in proper relationship to each other.  
(b) Poor body alignment.



b. **Small Structures Support Main Body Segments.** Relatively small vertebrae in the spinal column support the main body segments, small neck bones support the head, and small bones in the feet support the pelvis. Your ligaments and muscles must, therefore, be used properly in order for these small structures to correctly support the right relationship and balance among anatomical parts.

#### 1-4. BASE OF SUPPORT

a. **Your Contact With the Ground.** The base of support, the part of the body in contact with the ground (or other horizontal surface), may be represented by an imaginary line. When standing, your feet provide the base of support. An imaginary line drawn between your feet would represent your base of support.

b. **The Base of Support.** If you were lying on your back, with the entire length of your body in contact with the bed, that imaginary line would now run the entire length of your body. The base of support keeps you from toppling and provides stability for lifting, pushing, or pulling.

NOTE: Base of support is an imaginary line created by body parts that are in contact with the ground or other horizontal surface.

c. **The Broader the Base of Support, the Better.** When lying down, for example, your body is very stable because you have a broad base of support. Conversely, it is harder to maintain your balance if your feet are close together because your base of support is narrow. Remember, when moving or lifting a patient, spread your feet slightly for improved stability. See figures 1-2, 1-3, and 1-4.




Figure 1-2. A stack of film cassettes has a broad base of support

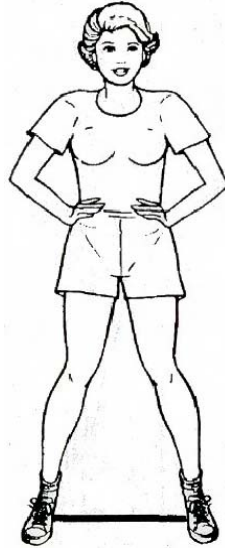


Figure 1-3. Spreading your feet broadens the base of support, providing greater stability.

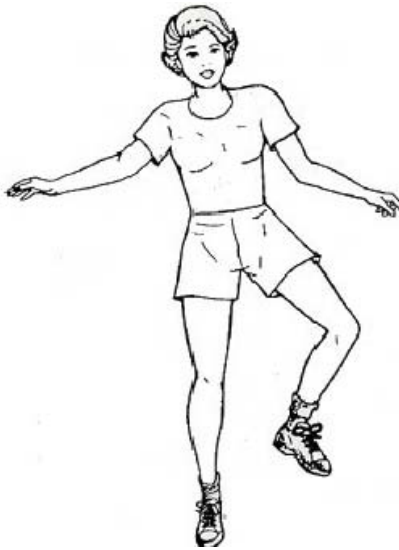

Figure 1-4. Standing on the tip of one foot provides only a narrow, thus, less stable base of support.

## 1-5. THE LINE OF GRAVITY

a. The **line of gravity** is an imaginary vertical line that passes through the center of gravity (figure 1-5). Follow the line of gravity in the profile shot (left half) of figure 1-6. When erect, the line of gravity passes behind the ear. It continues just behind the center of the hip joint. Then the line descends along the knee and ankle joints. (The exact location of the line of gravity will, of course, vary according to individual differences in body build and the curvature of the spine.)

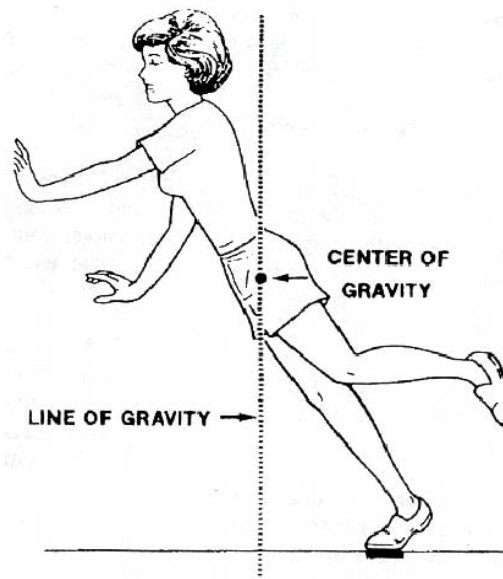


Figure 1-5. The line of gravity and center of gravity do not cross the base of support, making it hard to keep oneself in a stable position.

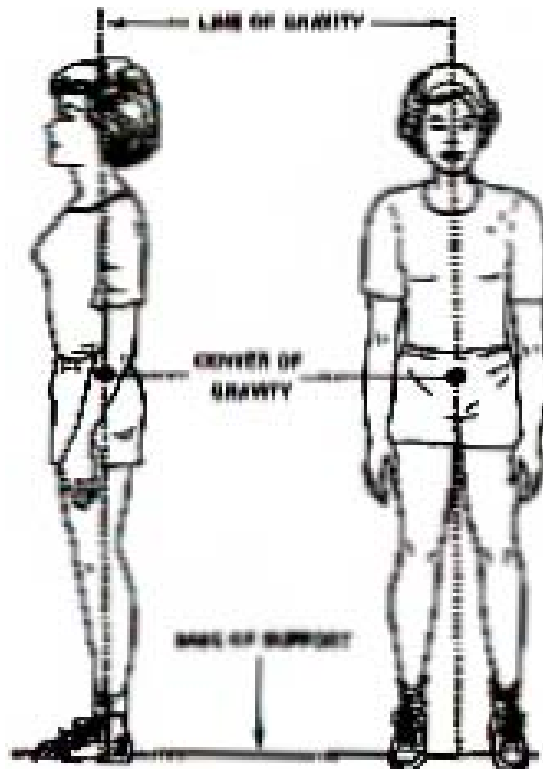


Figure1-6. The ideal interrelationship of the line of gravity, the center of gravity and the base of support, when good body mechanics is practiced.

b. As you can see from figure 1-6, when good body mechanics is practiced, the center of gravity is low. Note, too, that the line of gravity crosses the center of gravity and the base of support. Consider the frontal pose (right-hand portion, figure 1-6). Note that the base of support is wide, since the feet are spread apart.

c. The body is most stable when the line of gravity bisects the base of support. You can protect your back while carrying heavy objects by maintaining good posture and holding your load close to the body (figure 1-7). When the load is held close to the body, the line of gravity will bisect the base of support. Did you notice that one foot is placed slightly in front of the other? This provides the advantage of added front-to-back stability.

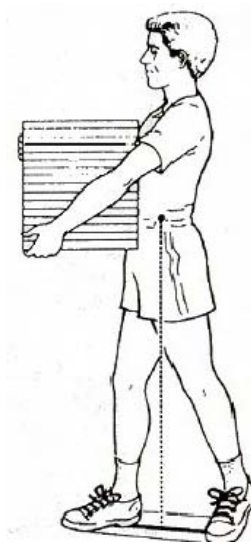


Figure 1-7. Carry the load close to your body. Keep feet apart, with one foot slightly in front of the other.

d. Figure 1-8 is an example of what **not** to do! You are inviting back injury, if you hold the load away from your body. The line of gravity will not bisect the base of support. The consequence of this technique is suffering fatigue, strain, and possible injury. This will not only mean personal discomfort, but a heavier workload for colleagues who might have to fill in for you if you are not able to work because of an injury. Do not allow failure to practice common sense body mechanics place you out of commission. Take a moment to think before acting in order to plan your movements for maximum ease and efficiency and minimum strain.

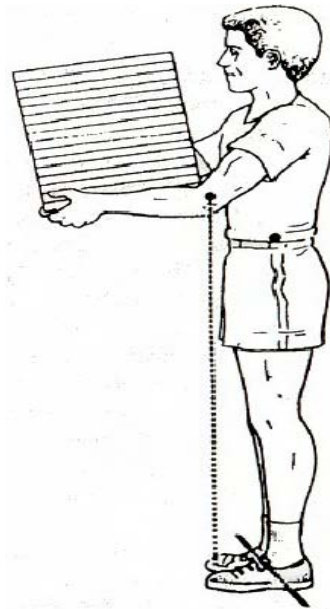


Figure 1-8. Avoid this! Holding the load away from the body will cause strain, fatigue, and possible injury

## 1-6. THE CENTER OF GRAVITY

a. **Located at Mid-Pelvis or Lower Abdominal Area.** The center of gravity (or center of body weight) is the point around which the weight of your body is balanced. Allowing for some variation based on body build, the center of gravity is generally located at the mid-pelvis region (about the level of the second sacral vertebrae) or in the lower abdominal region. (See figure 1-6.)

NOTE: The **center of gravity** is the point around which the weight of the body is balanced (mid-pelvis or lower abdomen, depending upon body build).

b. **About Half Your Weight Above, Half Below.** About half of your body weight is distributed above the center of gravity and half below that point. Your center of gravity is affected by the size and position of the load you are carrying. The size and location of the load add to the weight placed on the base of support. This, in turn, effects the location of the center of gravity.

c. **A Broad Base of Support and a Low Center of Gravity Desirable.** Stable objects have a broad base of support and a low center of gravity. The recumbent figure and the box of chemicals in figure 1-9 are very stable because they have a broad base of support and a low center of gravity. The body is most stable when the center of gravity is nearest the center of the base of support. By carrying a load close to your body rather than away from your body, the load will be close to your center of gravity. You will expend less energy, feel less strain, and be less likely to suffer injury.

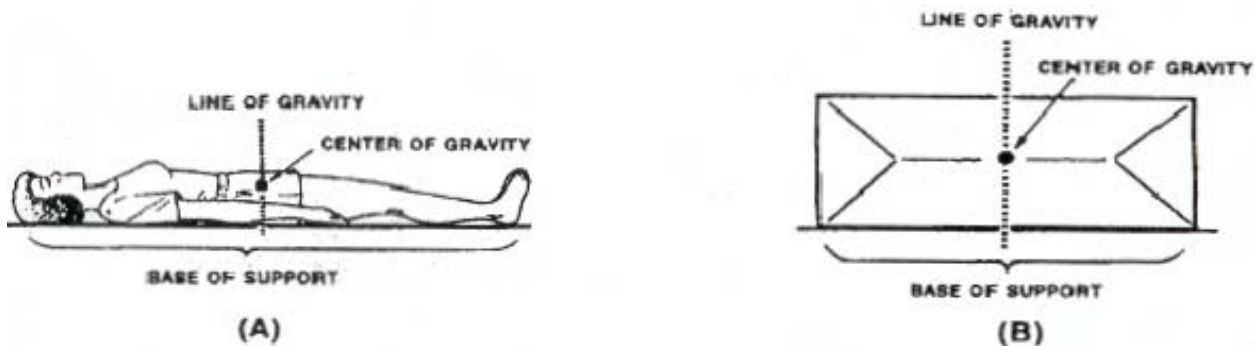


Figure 1-9. Factors promoting stability: a broad base of support, a low center of gravity, a line of gravity that intersects the base of support.

d. **Keeping the Center of Gravity Over the Base of Support.** Note that in figure 1-10, the line of gravity does not pass through the base of support. However, in figure 1-11, the line of gravity passes through the base of support. This is a desirable configuration that should be applied when lifting objects. When lifting an object, bend at the knees and hips and keep your back straight (figure 1-11). Positioned in this manner, the center of gravity will remain over the base of support (the feet) as it ought to be, making it easier to keep your balance.

## 1-7. RULES FOR LIFTING AND CARRYING HEAVY OBJECTS

a. The tips for good body mechanics and six common-sense rules for lifting and carrying heavy objects, outlined below, recap the highlights of good body mechanics. By applying these principles, you will minimize strain on the weakest part of your muscular system, the muscles of the back. You rely, instead, more heavily on the stronger muscles of the thighs, arms, and abdomen.

### TIPS FOR GOOD BODY MECHANICS

Center of gravity is low.  
 Base of support is wide.  
 Line of gravity passes through base of support.  
 Body parts are in good alignment.

## RECAP: APPLIED BODY MECHANICS

Feet wide apart.

When lifting or carrying:

1. Load balanced close to rille body (and the center of gravity),
2. Back straight trunk not twisted (line of gravity bisecting base of support).
3. Greater use of leg and abdominal muscles.
4. Less reliance on back muscles.

When picking up objects from the floor.

1. No bending from the waist.
2. Whole body lowered (squatting position), with knees bent.

b. The radiologic technologist shown in figure 1-10 is straining his back muscles needlessly. He has forgotten to apply the simple principles of good body mechanics. The line of gravity falls outside the base of support because he is bending over from the waist.

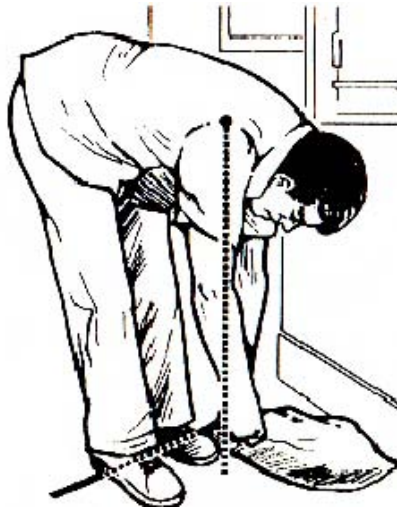

Figure 1-10. Poor body mechanics.

c. The RT shown in figure 1-11 is applying principles of good body mechanics. Instead of straining the weaker back muscles, he is relying on the long and strong muscles of the legs and arms. He is also holding the object close to his body so that the line of gravity falls within the base of support.



Figure 1-11. Good body mechanics.

## 1-8. AVOIDING BACK INJURY ON THE JOB

a. Everything you do of work can put you at risk for back injury. A common mistake is lifting with the back bent and legs straight using last jerky movements. Bending increases the pressure on the discs and twisting applies even more pressure to them.

b. If reading this section has made you want to change your ways, keep in mind that it will take of least two weeks of concerted effort both at home and at work before new work habits became second nature.

c. Key suggestions are to use body momentum, keep the back neutral, get help, use assisting devices, keep loads close to the body, and avoid twisting activities.

**Continue with Exercises**



## EXERCISES, LESSON 1, SECTION I

When you have completed all of the exercises to your satisfaction, turn to the solutions that follow to check all of your answers.

**MATCHING.** For exercises 1 through 4, match the term in the left-hand column with the applicable definition in the right-hand column. Enter the letter you have selected in the space provided (One definition will not be selected.)

- |                             |   |
|-----------------------------|---|
| 1. _____ Body mechanics.    | a. Imaginary line created by body parts in contact with horizontal surface. |
| 2. _____ Base of support.   | b. The safe and efficient use of the body in movement.                      |
| 3. _____ Center of gravity. | c. Imaginary vertical line that passes through center of gravity.           |
| 4. _____ Line of gravity.   | d. Point around which body weight is balanced.                              |
|                             | e. Severe muscle strain resulting from misalignment of body parts.          |

**MULTIPLE-CHOICE.** For exercises 5 through 11, select the ONE word or phrase that BEST completes the statement or BEST answers the question.

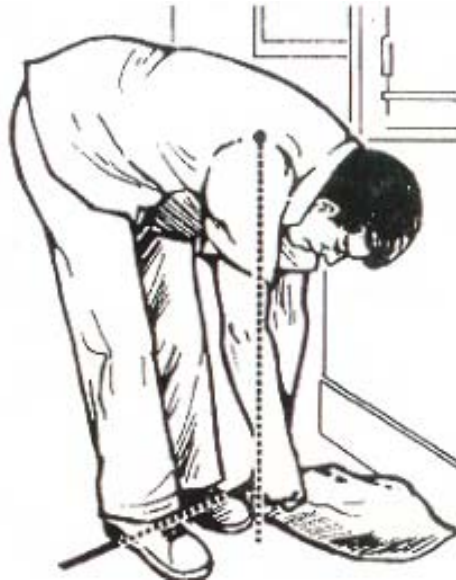5. It is important to know and apply the basic principles of good body mechanics in order to avoid \_\_\_\_\_ in the radiology department.
- a. Moving, lifting, and carrying patients.
  - b. Ethically questionable behavior.
  - c. Patient/self injury and malpractice suits.
  - d. Damage to equipment.

6. When carrying a load close to your body, the line of gravity should:
  - a. Bisect the base of support.
  - b. Fall in front of the base of support.
  - c. Fall behind the base of support.
  
7. A wide and stable base of support is obtained by:
  - a. Standing with your feet apart.
  - b. Lunging forward.
  - c. Rounding your shoulders slightly.
  - d. Limbering up before using your muscles.
  
8. You will protect your back most effectively if you carry a load:
  - a. Extended approximately 12 inches from the waist.
  - b. Close to the body.
  - c. Unevenly balanced, favoring your dominant side.
  - d. Above your head.
  
9. When the pelvis, thorax, and head are properly \_\_\_\_\_, it is easy to keep the body stable and steady and to prevent tipping or falling over.
  - a. Shaped.
  - b. Joined.
  - c. Aligned.
  - d. Exercised.

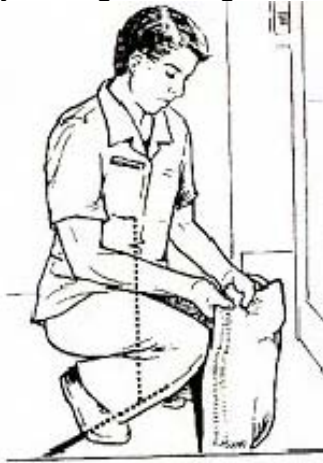10. Which of the following is NOT a principle of good body mechanics
- a. Maintain a wide stance with the load held close to the body.
  - b. Rely on your back muscles as much as possible when lifting and moving heavy objects.
  - c. Keep your back straight when lifting or carrying objects.
  - d. Avoid twisting the trunk of your body when lifting or carrying objects.
11. When moving, lifting, or carrying heavy objects you should NOT:
- a. Bend your knees and lower your body when picking up objects.
  - b. Use leg and abdominal muscles.
  - c. Roll or push heavy objects.
  - d. Bend from the waist when reaching near the floor.

**IDENTIFICATION.** For exercises 12 through 15, indicate whether the illustration shows good or bad body mechanics by entering a "yes" or "no" in the space provided.

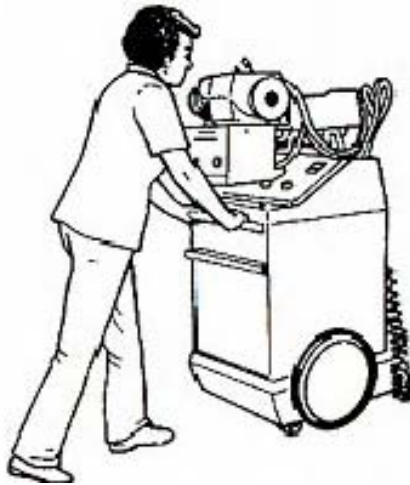12. Retrieving an object from the waist. \_\_\_\_\_



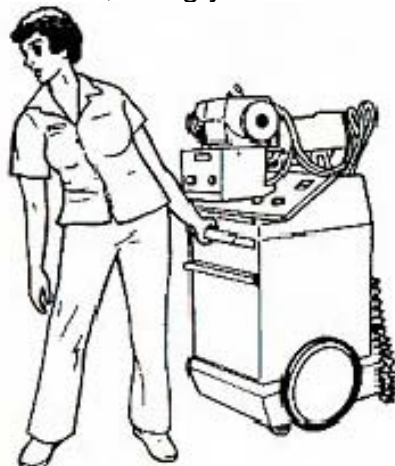13. Retrieving an object using your leg and thigh muscles. \_\_\_\_\_



14. Pushing a portable X-ray machine using your arm and chest muscles. \_\_\_\_\_



15. Pulling a portable X-ray machine, using your back muscles. \_\_\_\_\_



**Check Your Answers on Next Page**

## **SOLUTIONS, LESSON 1, SECTION I**

Be sure to re-read and study the paragraph(s) pertaining to any exercises you might have answered incorrectly. The relevant paragraph(s) is (are) listed after each of the answers below.

1. b para 1-2c)
2. a (para 1-4)
3. d (para 1-5)
4. c (para 1-6a)
5. c (para 1-2)
6. a (para 1-6b)
7. a (para 1-4)
8. b (para 1-5c)
9. c (para 1-3a)
10. b (para 1-7)
11. d (para 1-7, chart: "Applied Body Mechanics," rule number five.)
12. no para 1-7; chart, rule no. 5)
13. yes para 1-7; chart, rule no. 6)
14. yes para 1-7; chart, rule no. 2)
15. no para 1-7)

## Section II: MOVING AND TRANSPORTING THE PATIENT

### 1-9. ASSESSING THE PATIENT

a. **Weight.** Have you ever moved a 350 pound patient? Although weight is one consideration, the assessment that you make before moving and/or transporting a patient involves a number of factors besides weight. The patient's physical and mental condition, mobility, strength and endurance, balance, and ability to understand must be determined as well.

b. **Condition.** Assuming that you have verified the patient's identity, the first step in assessment is to talk to the patient to get an overall impression of his condition. How is the patient feeling? Is the patient coherent? How well or poorly is he functioning?

c. **Mobility.** Can the patient walk around on his own? Is the patient's movement limited in any way? You need to determine whether or not the patient will need any assistance and, if so, the extent of the assistance needed.

d. **Strength and Endurance.** If the patient seems mobile, does he, for example, have the necessary strength and endurance to walk all the way down the hall unassisted?

e. **Balance.** Is the patient steady on his own feet? Can he sit and stand for long periods, as required? Or, is there a chance that the patient could collapse halfway down the hall?

f. **Responsiveness and Alertness.** What about the patient's mental state? Does the patient understand what you are asking? Is he alert and responsive? Would the patient be able to warn you if he suddenly felt dizzy?

g. **General Rules.** Figure 1-12 outlines helpful hints for preparing the patient to be moved or transported.

#### HELPFUL TIPS IN PREPARING THE PATIENT

1. Provide only the assistance needed to ensure the patient's comfort and safety.
2. Always transfer the patient across the shortest distance.
3. Lock all wheels on beds and gurneys.
4. Tell the patient what you plan to do.
5. Encourage the patient to help within his own capabilities.
6. Provide short, simple instructions to the patient.

Figure 1-12. Tips for moving and transporting the patient.

## 1-10. AN ON-THE-JOB INJURY

a. A civilian RT injured his back during a failed attempt to lift a patient. The technologist, a slight man of 5 foot 4 inches, did not want to take the time to get help in moving his patient, a rather heavy-set, but mobile individual. The RT had already experienced some difficulty in assisting the patient with the initial move from wheelchair to X-ray table, which was supposed to have been patient-assisted.

b. The mishap occurred when the partially-mobile patient was stepping down from a step stool. He lost his footing and toppled over the RT. As a result of this fall, the technologist injured his back, suffering nerve damage and rupturing his L-5 disc. The injury resulted in chronic pain and discomfort, which led to absenteeism. This, in turn, caused a personnel shortage within the department for a full six months. The RT, who loved his job, ended up getting Workmen's Compensation and being medically retired. He wanted to work, but no longer could because of one hasty decision based on a mistaken notion about saving time.

c. The fall was, almost literally, the straw that broke the camel's back. This radiologic technologist's back had already been weakened by years of misuse resulting from poor body mechanics. As a secondary observation, if he had known how to take the fall, his injury might have been less serious.

## 1-11. TRANSFERRING A PATIENT FROM A WHEELCHAIR TO AN X-RAY TABLE

a. **Patient Able to Assist.** Even a mobile patient must be given some help in making the transfer from wheelchair to X-ray table, or from the X-ray table to the wheelchair. While it is desirable to let the patient assist to the extent possible, the patient might, in fact, not be as strong as he thinks. A sudden movement, for example, may make the patient dizzy and fall. So, you must be on the alert, ready to provide the assistance needed. The next series of figures shows what you need to do for a patient who is able to assist from properly positioning the wheelchair in relation to the table (figure 1-13), helping the patient to stand up (figure 1-14), helping the patient onto the step stool (figure 1-15), easing the patient onto the table (figure 1-16), positioning the patient on the table (figure 1-17), and placing him in the supine position (figure 1-18).

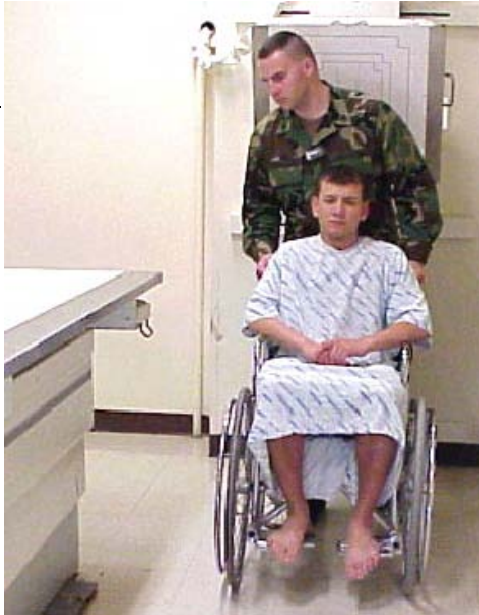

Figure 1-13. Positioning the wheelchair.

- Steps:
1. Wheelchair, parallel to table.
  2. Brakes locked.
  3. Footrest out of the way.
  4. Step stool nearby.

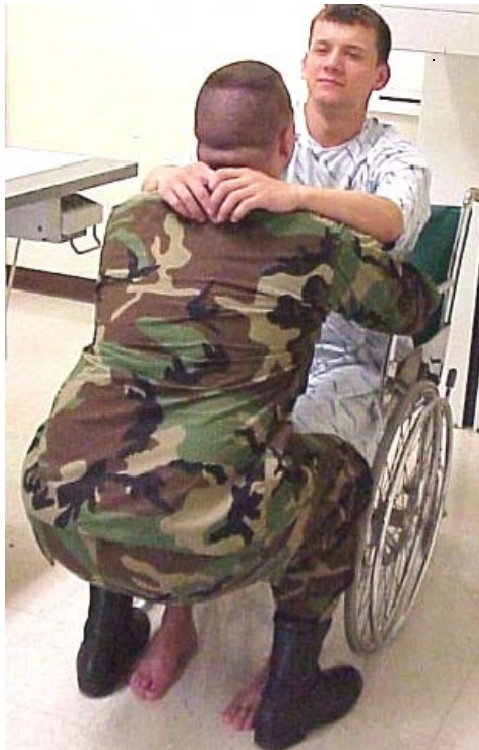

Figure 1-14. Helping the patient to stand up.

- Steps:
1. Patient's hands on your shoulder.
  2. Your hands under patient's arms, in axilla.
  3. You lift as patient stands.
  4. You pause, so patient can regain balance.



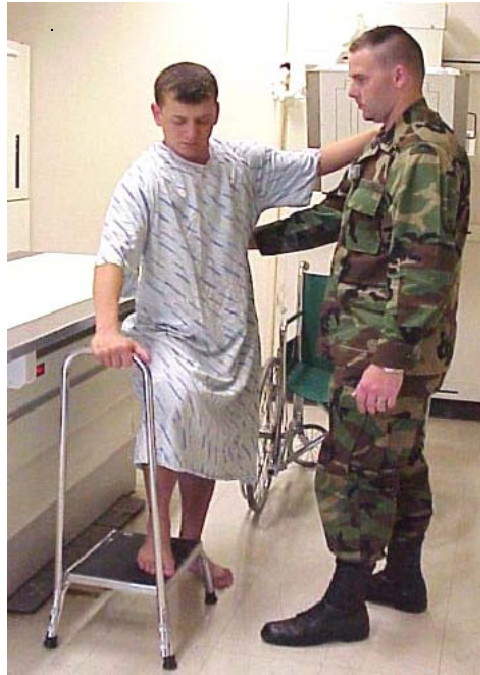

Figure 1-15. Onto the step stool.  
Steps: 1. Patient places one hand on stool.  
2. Places other arm across your nearest shoulder.

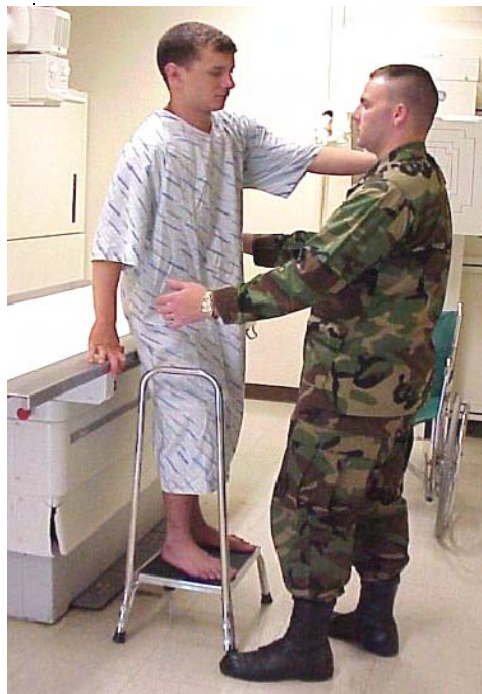

Figure 1-16. Help patient onto table.  
Steps: 1. Patient pivots so back is to X-ray table.  
2. You support patient, as he eases into sitting position.

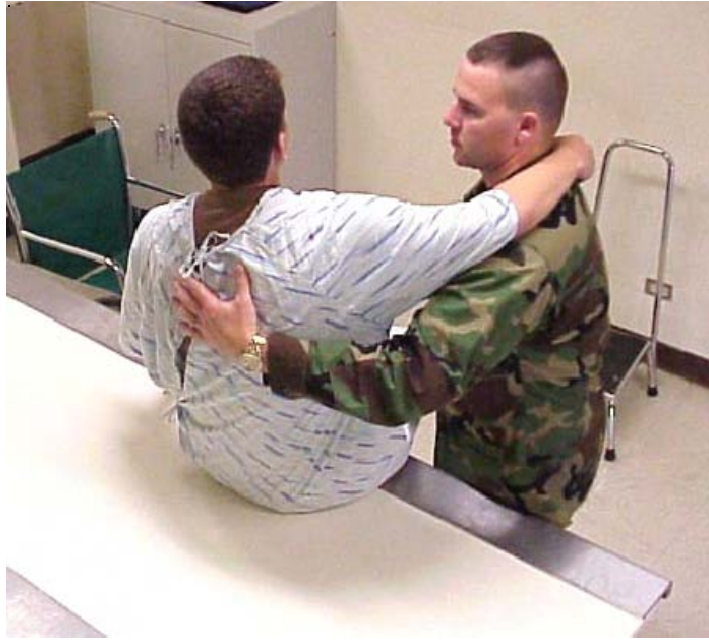

Figure 1-17. Position patient on table.

Step: Place one arm around patient's shoulder, the other under knees.

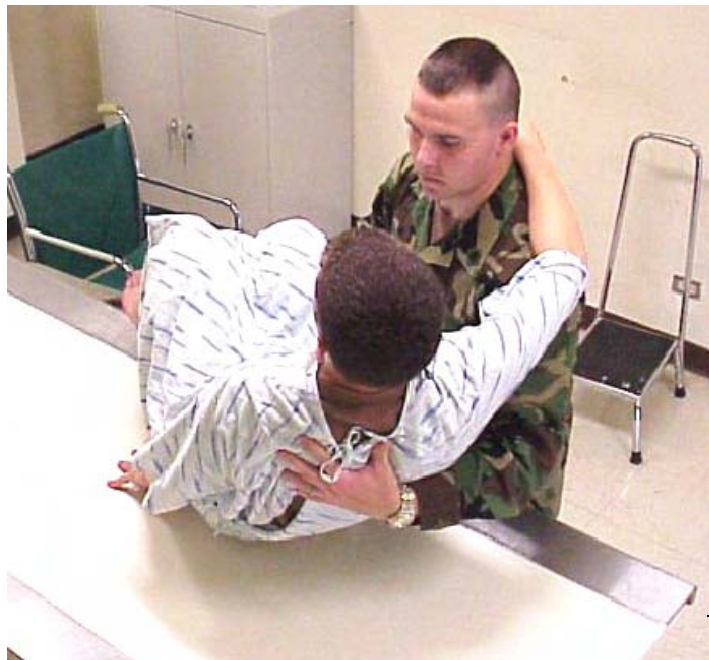

Figure 1-18. Place patient in supine position.

Steps: 1. In one single motion, place patient's legs on table.

2. Lower the head and shoulders on to table.

b. **Patient Unable to Assist.** If the patient cannot assist, find someone else to help you. Two movers are needed when a patient cannot provide assistance. Follow the procedures given in figures 1-19 through 1-24.

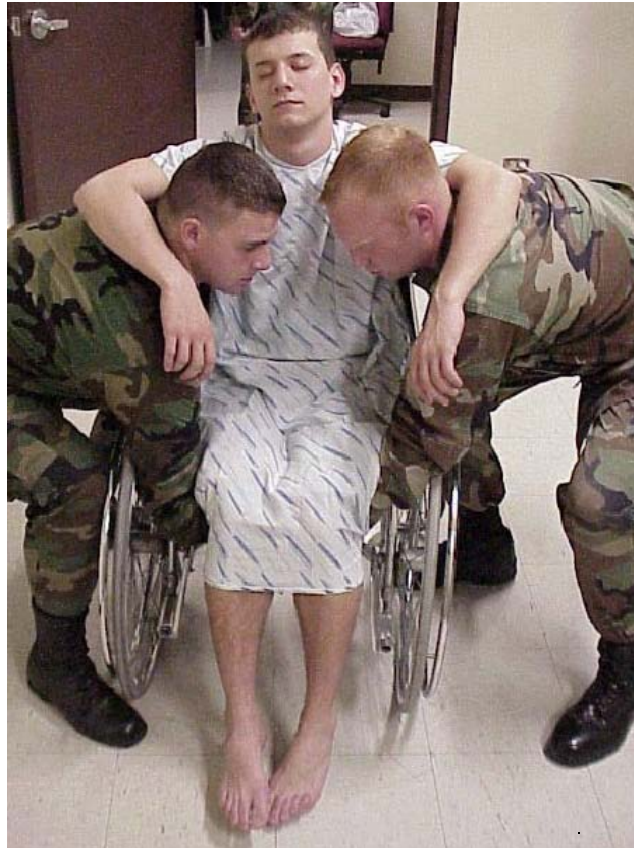

Figure 1-19. Two movers in position, one on each side of the wheelchair, shoulder to axilla.

- Steps:
1. The mover on the left places right shoulder under patient's left axilla and places left arm under patient's thighs,
  2. The mover on the right places left shoulder under patient's right axilla and places right arm under patient's thighs.

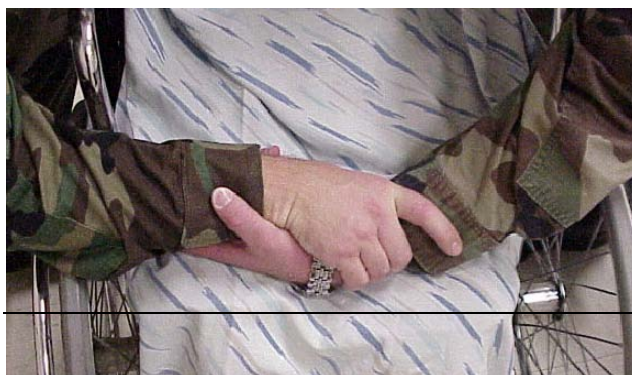

Figure 1-20. The wrist grasp. Step: Grasp each other's wrist.

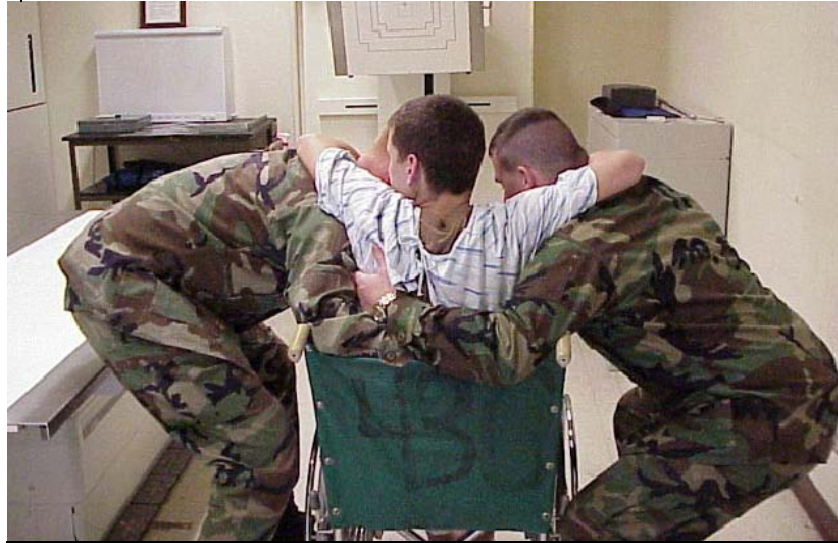

Figure 1-21. Hands across the back.  
Step: Wrap your free hand around the patient's back, to provide support.

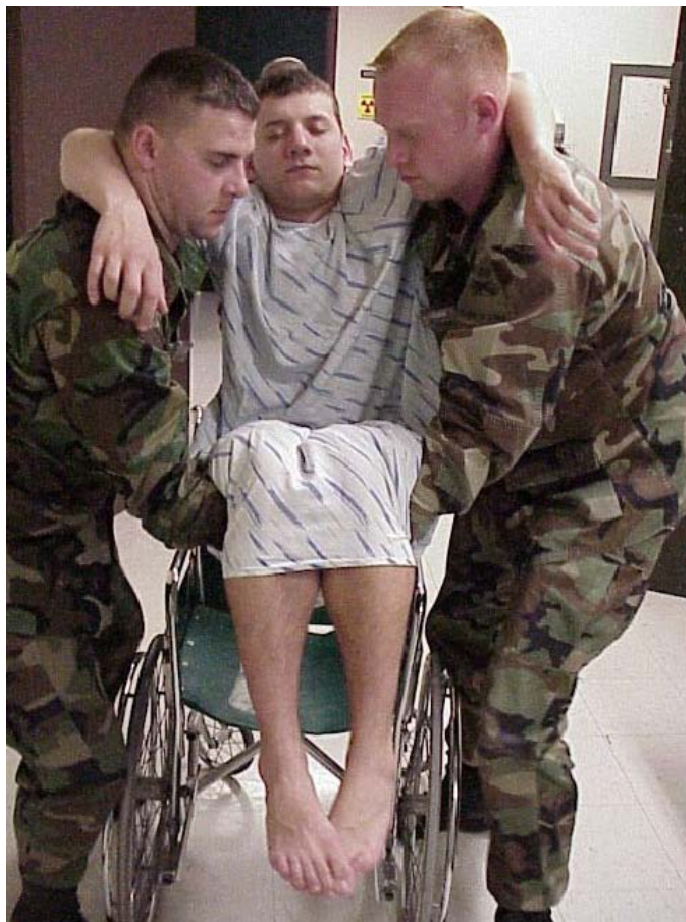

Figure 1-22. The lift begins.  
Step: Lift the patient at the leader's signal, generally, "One, two, three, lift."

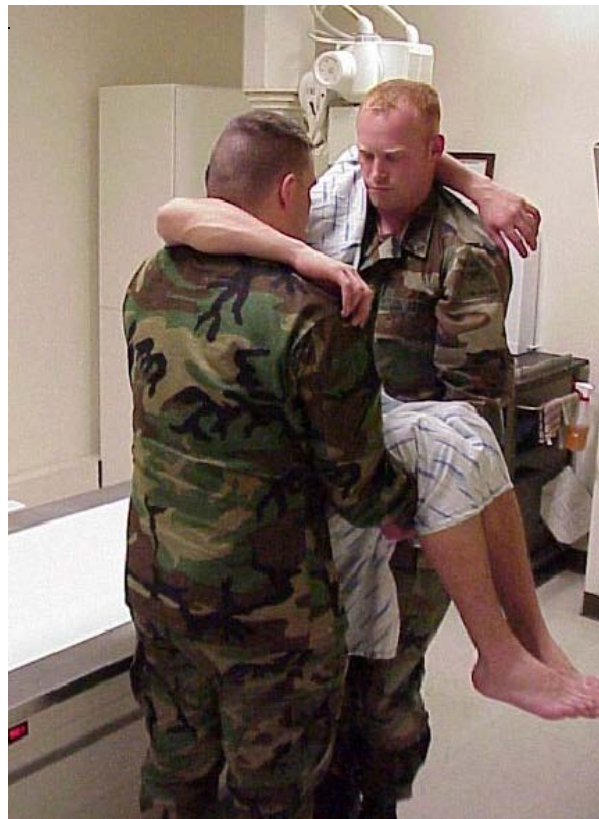

Figure 1-23. Place patient on table.  
Step: Turn sideways to place the patient on the X-ray table.

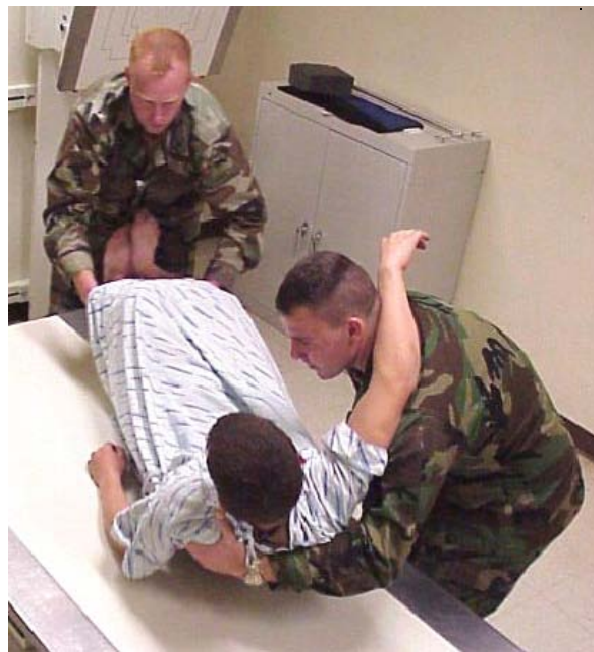

Figure 1-24. Place in supine position.  
Step: Assist the patient to lie down.

## 1-12. TRANSPORTING FROM STRETCHER TO X-RAY TABLE (PATIENT ASSISTED)

a. **Advantages of Stretcher.** A patient coming to the radiology department may have to wait some time in the department before or after an exam. If the patient cannot stand safely or sit comfortably for extended periods, a stretcher should be selected as the method of transport. A patient can be moved more easily to an X-ray table from a stretcher than from a wheelchair. (Table height can't be adjusted.)

b. **Patient Able to Assist.** If the patient is not too heavy and is able to assist, you may be able to transfer the patient from the stretcher to the X-ray table by yourself. It is always desirable, however, to allow the patient to assist to the extent possible (figures 1-25 and 1-26). If the patient is able to assist, place yourself on the outer side of the table to hold the stretcher in place, flush against the table as the patient moves onto the stretcher. If the patient is too heavy for you or too weak, do not hesitate to seek assistance. Again, take special note of the warning to place the stretcher flush up against the X-ray table with no space in between (figure 1-25). If there is the slightest space between the stretcher and the X-ray table, the stretcher could swing away as the patient attempts to hoist himself onto the table, causing the patient to fall to the floor and, quite possibly, get hurt.

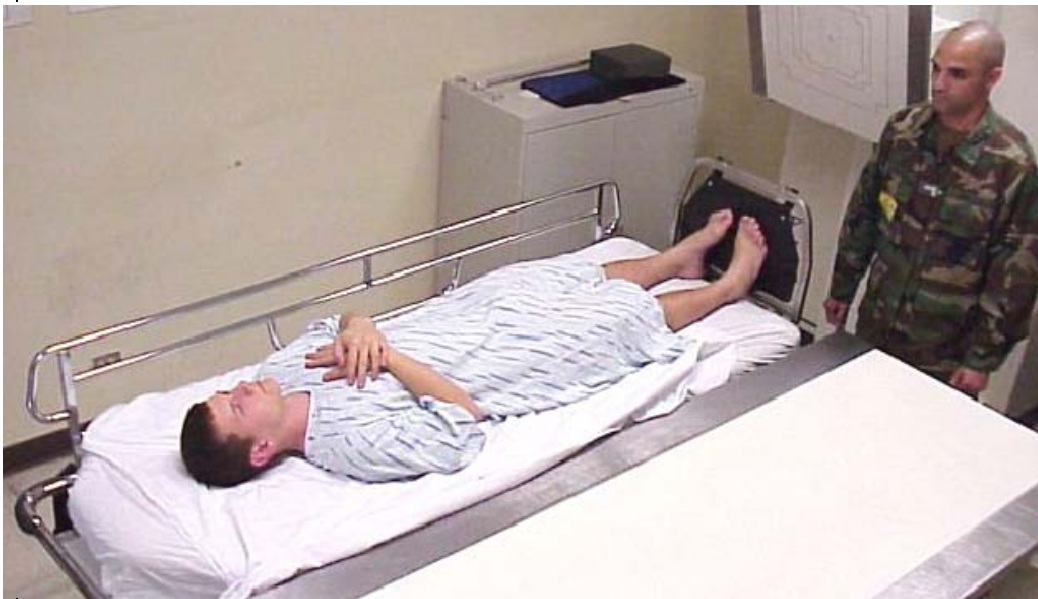

Figure 1-25. Equipment preparation.

- Steps: 1. Stretcher is parallel and flush against the table. There is no space in between.
2. Stretcher wheels are locked.

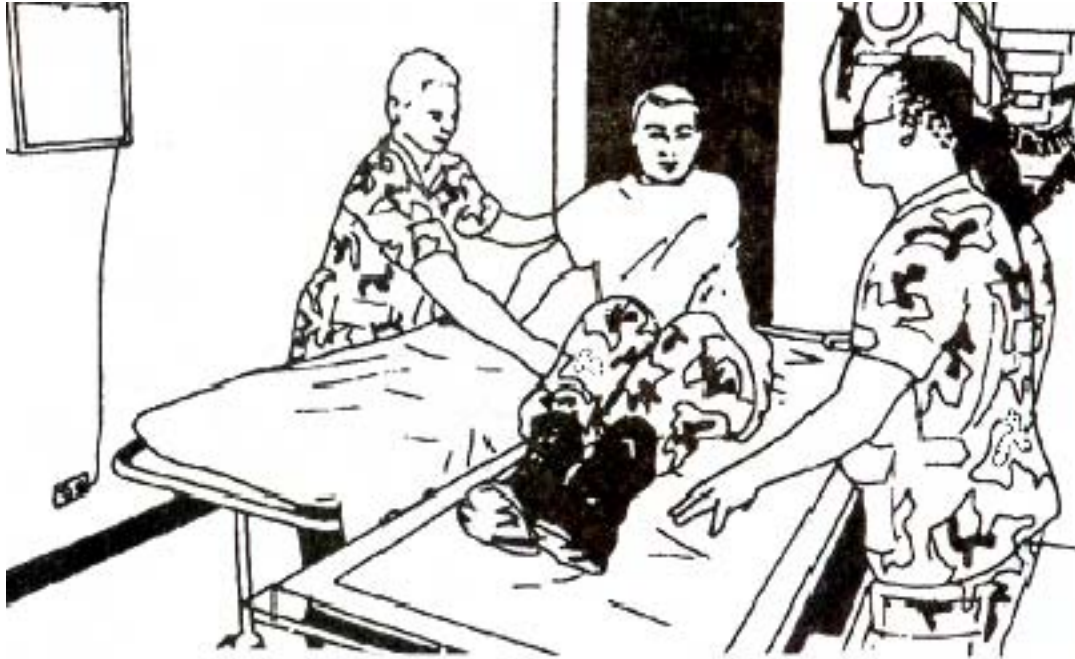

Figure 1-26. The move.

Step: The patient hoists himself by moving the hips, shoulders and legs, thus completing the move to the X-ray table. Throughout this move, make sure that the stretcher is flush up against the X-ray table with no space in between.

### 1-13. CONSIDERATIONS: MOVING A PATIENT WHO CANNOT ASSIST

a. **Minimize Movement and Never Lift Patient Alone.** A patient who is too sick to assist must be handled differently. Such a patient should be moved as little as possible for the patient's protection. Never try to lift a helpless patient alone. When moving a relatively heavy, helpless patient to the X-ray table, move the patient on a sheet with four to six movers assisting. (Two to three movers generally suffice for a light patient.)

b. **Practice Good Body Mechanics.** Think, too, about protecting yourself by practicing good body mechanics. To avoid straining the muscles of your back when lifting a heavy patient, flex the knees, straighten the back, and bend from the hips (figure 1-27). Some of the steps in the draw-sheet pull and three-person carry (paras 1-14 and 1-15) illustrate these important principles.

c. **Protecting the Patient During the Move.** When lifting a patient's shoulders, be sure to support his head. While holding the patient's head with one hand, slide the opposite arm under his shoulders and grasp the axilla so that the head can rest in the crook of your elbow when the patient is raised. When you must move the patient's hips, first flex the patient's knees. The flexing may make it possible for the patient to raise himself. If not, it will, at least, make it easier to lift the body when the knees are bent.

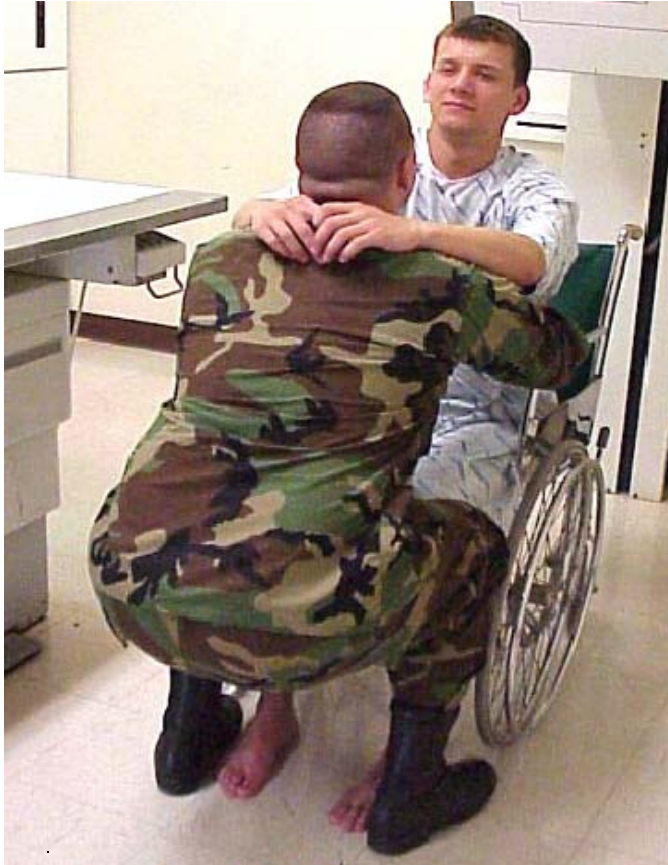

Figure 1-27. Technologists with knees flexed and back straight to avoid back injury.

#### 1-14. THE DRAW SHEET PULL (PATIENT UNABLE TO ASSIST)

a. **Patient Unable to Assist and Height Disparity.** If the patient is unable to assist in the move or is unconscious, the draw sheet pull method is a convenient means of moving the patient (figure 1-28). The draw sheet pull is also useful when there is a height disparity between the stretcher and the X-ray table that cannot be adjusted. Older stretchers are not adjustable, and even one of the newer adjustable stretchers that can be pumped up and down may be broken. In some cases, it may be undesirable to adjust the stretcher. The jarring motion of pumping the stretcher up and down could aggravate a patient's condition, depending on the nature of the illness.

b. **Seeking Assistants.** Depending upon the weight, size, and condition of the patient, you will need to seek the help of one or more assistants (movers). As a rule of thumb, there should be two to three movers for a light patient and four to six movers for a heavy patient. When the patient is unconscious or unable to assist, special care must be taken to fully support the spine, head, and extremities as you move the patient. The movers must act in unison to ensure that the patient's head and feet move safely with the trunk.



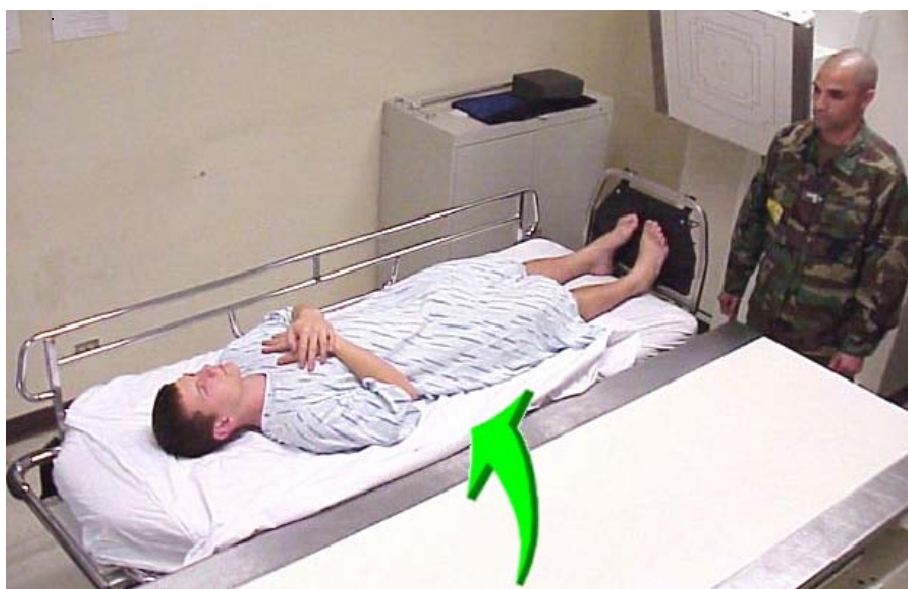

Figure 1-28. Draw sheet is a single sheet that is folded in half and placed under the patient and over the middle third of the bed.

**NOTE:** Get an additional mover to hold the intravenous infusion (IV) pole, if applicable.

c. **Preparing the Sheet.** The draw sheet pull method requires the use of a sheet that is slipped under the patient in order to slide the patient from one surface to another (figure 1-28). You will need a heavy draw sheet or a full sheet folded in half for this purpose. Normally, there will already be a full sheet folded in half on the stretcher. A draw sheet is a single sheet folded in half. It is placed under the patient and over the middle third of the bed. A draw sheet is used, as a matter of routine, for those patients who need frequent help in order to move about. Just before moving the patient, the edges of the draw sheet are loosened from the bed and rolled up close to the patient's body to form handholds.

d. **Padding and Other Precautions.** If the X-ray table is the stationary cradle type, extra padding will be needed to protect the patient from the metal parts of the table's edge. For cradle tables with a floating surface, move the tabletop as far forward as possible toward the stretcher to prevent injury to the patient. Move tube housings above the radiographic table out of the way to protect both the patient and the movers. Instruct the patient not to sit up in order to avoid bumping into the unit.

e. **Moving the Lighter Patient.** After you have prepared the draw sheet and assembled your movers as described above, you are ready to follow the steps shown in figures 1-29 through 1-31.

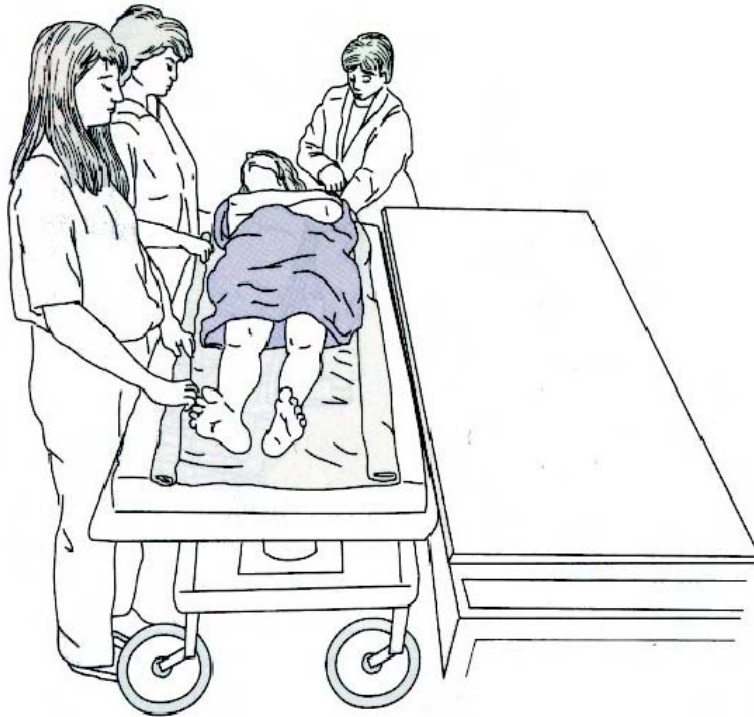


Figure 1-29. Equipment preparation.

- Steps:
1. Mover 1 holds stretcher flush against table with wheels locked.
  2. Movers loosen their side of draw sheet and roll it toward patient to form handholds.
  3. Mover three supports patient's head.

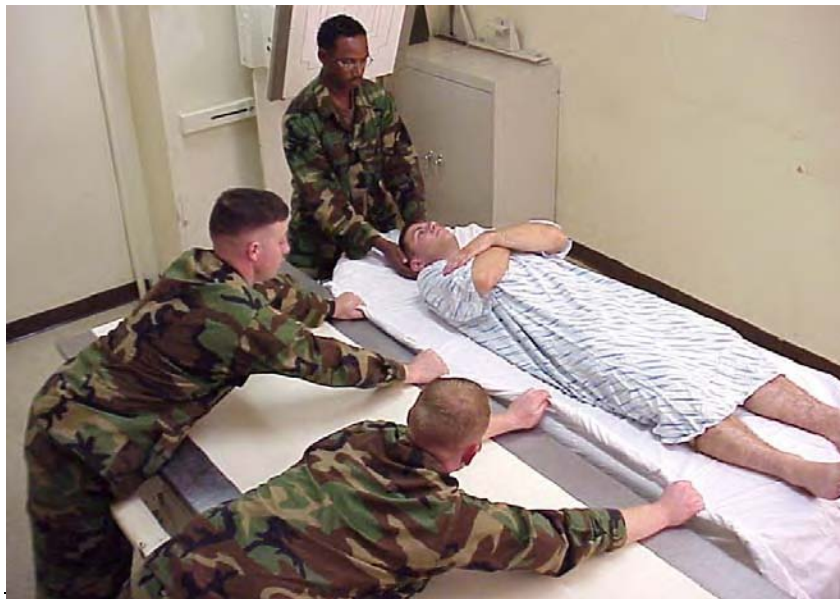

Figure 1-30. Grasping handholds and beginning the move.

- Step: Movers 1 and 2 grasp the handholds and slide the patient onto the X-ray table while mover 3 supports the patient's head.

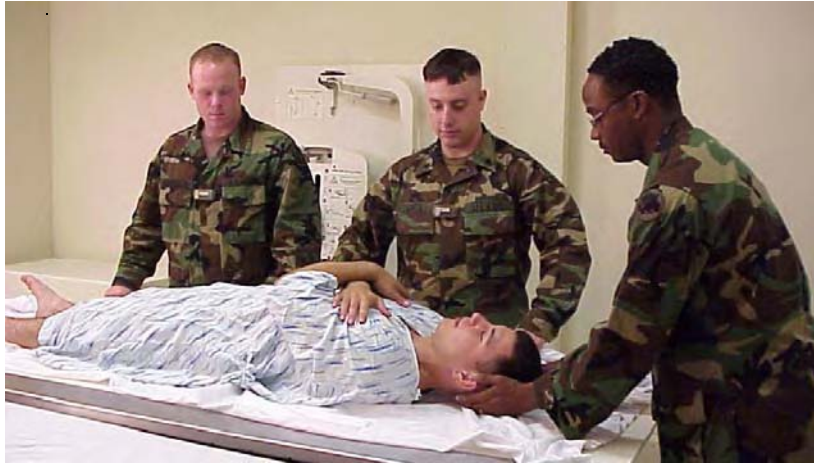

Figure 1-31. Completing the move.

Step: With the patient safely transferred to the X-ray table, the move is completed.

f. **Moving the Heavier Patient.** After you have prepared the draw sheet and assembled your four to six movers, you are now ready to follow the steps shown in figures 1-32 and 1-33.

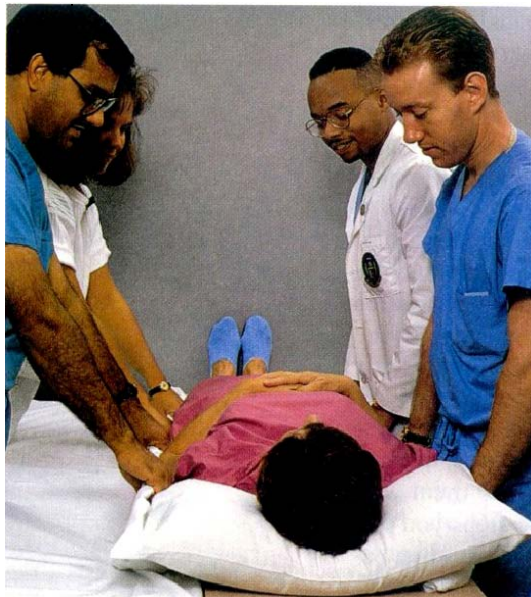


Figure 1-32. Positioning and preparing for the move.

- Steps:
1. Movers (on stretcher side) hold stretcher flush against the table with stretcher wheels locked.
  2. Movers loosen and roll each side of the draw sheet toward patient to form handholds.
  3. Mover (at head of table) supports patient's head.

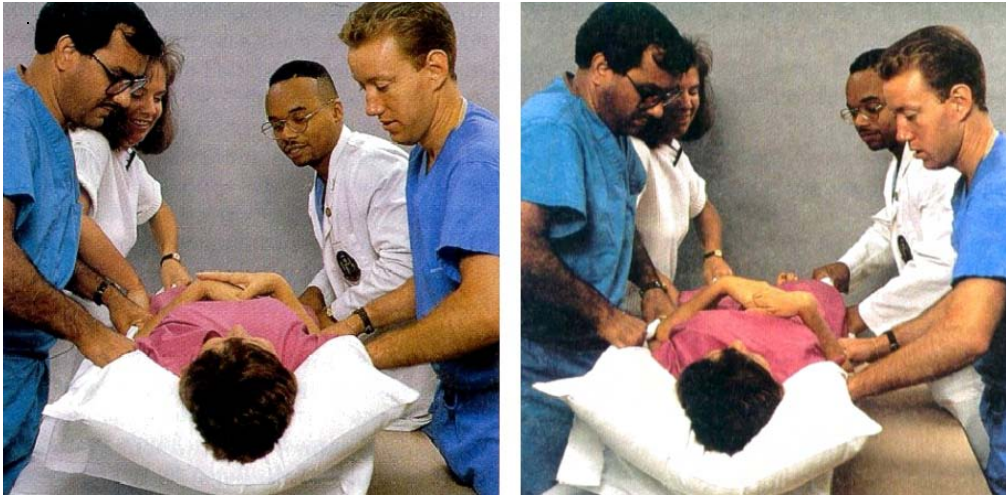

Figure 1-33. Moving in unison.

Steps: Moving in unison to the leader's count of three, movers use handholds to hoist patient while ensuring that the head and feet move safely in unison with the trunk.

#### **Recap--Draw-Sheet Pull**

1. Place stretcher parallel to and flush up against X-ray table (no space between stretcher and table).
2. Lock stretcher wheels.
3. On the stretcher side, loosen the edges of the draw sheet from the bed and roll the up close to the patient's body to form a handhold.
4. Similarly, leaning across from the X-ray table side, make a handhold from the loosened sheet on the other side of the patient.
5. With one or more persons at head and shoulder level and the others at hip level, firmly grasp the sheet close to the patient's body.
6. If necessary, have an additional mover to support patient's head.
7. In unison, drag the patient across the stretcher and onto the X-ray table.

## 1-15. PLACTIC SLIDE-BOARD IN LIEU OF DRAW SHEET

In some hospitals, a plastic slide-board is used in lieu of the draw sheet (figure 1-34). The slide-board (with a sheet on top) is placed under the patient. The slide-board has three handholds on each side that are built into the board. These handholds are grasped by the movers to accomplish the move. Using the slide-board requires less effort because the surface is smoother and, thus, produces less friction. The board, itself, is thin, slightly pliable, and very lightweight. It is a little wider and longer than the patient.

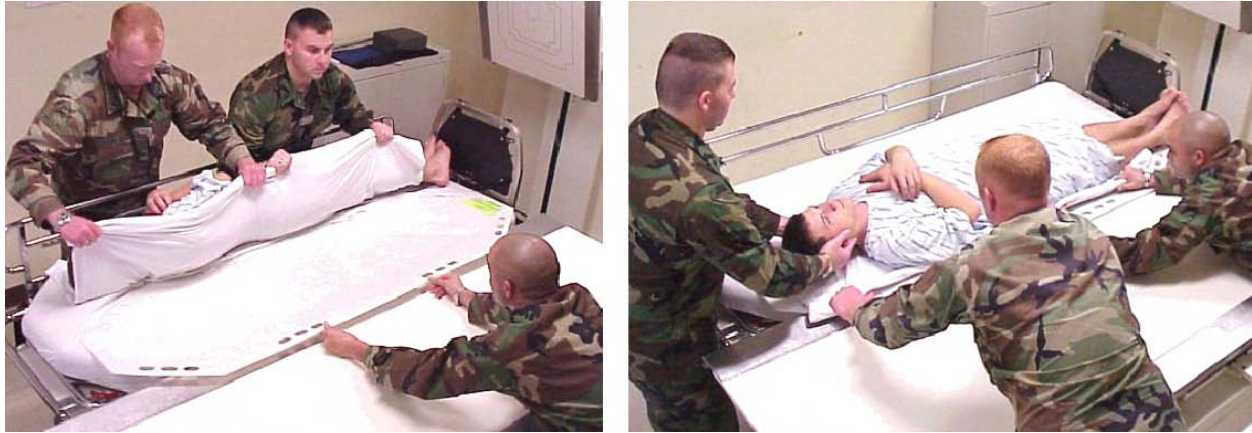

Figure 1-34. Using a slide-board.

## 1-16. THE THREE-PERSON LIFT AND CARRY

a. **An Alternative to the Draw Sheet Pull Method.** The three-person lift together with the three-person carry constitutes an alternative to the draw sheet pull. Like the draw sheet pull, the three-person carry permits you to move a patient who cannot assist and compensates for any disparity in height between the stretcher and the X-ray table. Like the draw sheet pull method, the three person carry permits you to move a helpless or unresponsive patient while keeping him in a horizontal position with the back straight. As the name suggests, you will need the help of two other movers (carriers) for this method. For ease of understanding, the preliminary lift and the subsequent carry are described separately. But, in fact, they are both part of the same method of moving a helpless patient, known as the three-person carry.

### THREE PERSON CARRY

1. A suitable alternative to the draw sheet pull.
2. Used for unresponsive or helpless patients.
3. Compensates for differences in height between stretcher and table.

b. **Position of Carriers.** Those assisting with the carry should position themselves in order of height (figure 1-35). The tallest, carrier 1, should be standing near the patient's head. (The reason is that a tall individual is more likely to have long arms that can fully support the patient's head and shoulders.) Carrier 2, the next tallest, should stand in the middle, facing the patient's midsection. Carrier 3, the shortest, stands facing the patient's legs.

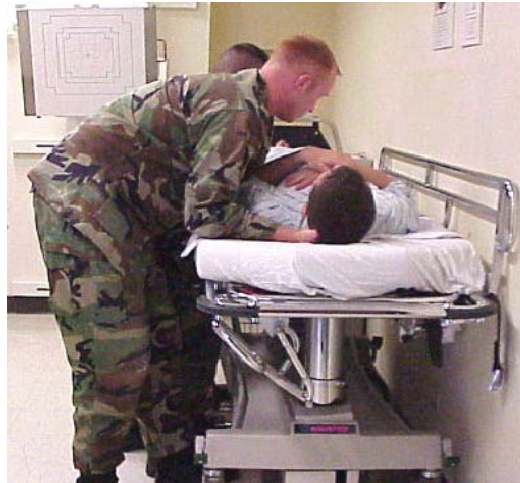

Figure 1-35. Carriers in order of height, with the tallest at the patient head.

c. **Preparing for the Lift.** Equipment safety precautions with regard stretcher wheels are the same for this method of transporting a helpless or unresponsive patient as for other methods of transporting a patient discussed so far. As with previous methods, make sure that the wheels of the stretcher are locked. Then, place the stretcher appropriately in relation to the X-ray table: at right angles, in tandem, or parallel. The limitations of the room and the patient's condition will determine how you place the stretcher in relation to the X-ray table. (Placement of the stretcher will be discussed in more detail in paragraph 1-17.)

d. **Arm Placement of Carriers.** The way that the carriers place their arms under the patient's body is crucial to correctly supporting the patient during the lift and carry. Carriers should place their arms as shown in figure 1-36. Here, carrier 1 appears on the far left of the figure shown, but still near the patient's head.

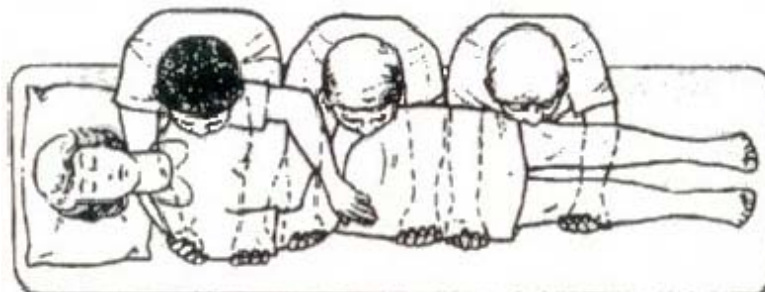


Figure 1-36. Carrier arm placement. (L to R—C1, C2, C3)

**C1:** One arm under patient's neck/shoulders. Other arm under patient's mid-trunk.

**C2:** One arm under patients, pelvis Other arm under patients mid -thighs.

**C3:** One arm against carrier 2's arm. Other arm under leg.

e. **Carry.** See figures 1-37 through 1-41 for procedures for the carry.

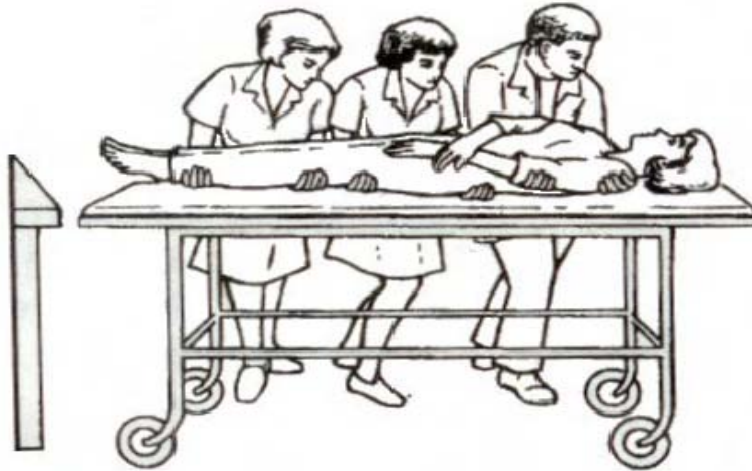


Figure 1-37. Equipment preparation and arm placement.

Steps: 1. Wheels locked.

2. Stretcher appropriately placed in relation to table.

3. Carriers lean forward and slide hands under patient's body

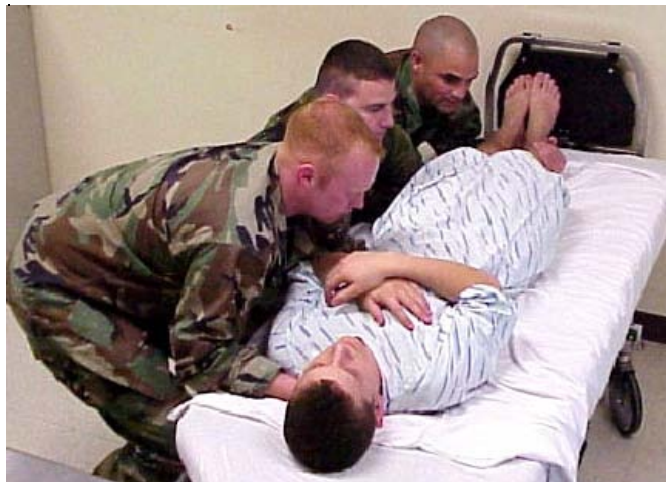

Figure 1-38. Arm/equipment preparation seen from a different angle.

Carriers have placed their arms appropriately. They are ready to execute the three-person lift (and carry).



Figure 1-39. Lifting the patient.

Carriers rock back, lift the patient, and logroll the patient. Carriers logroll the patient toward their chest. Note that the patient's weight is borne by the carrier's arms and chest.



Figure 1-40. Carriers pivot toward the table.



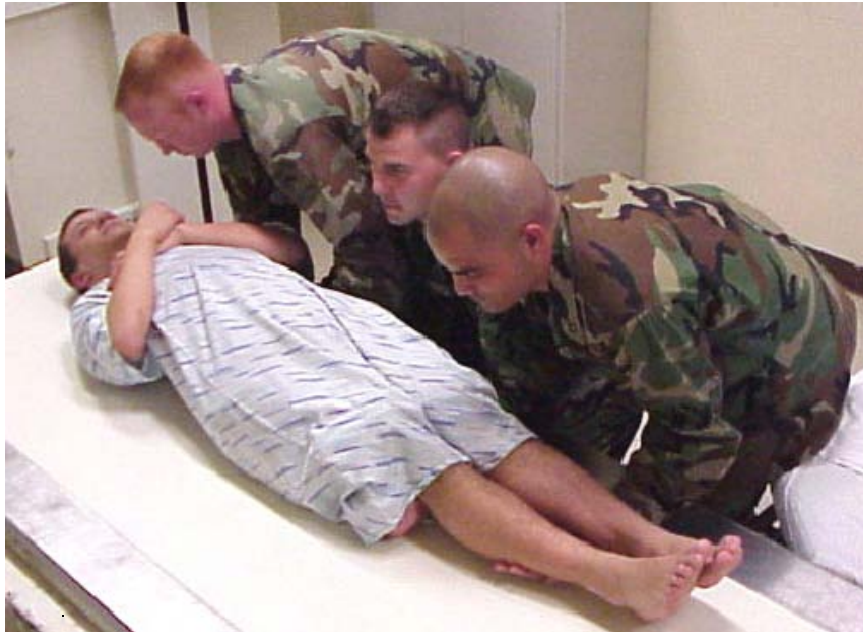

Figure 1-41. Lowering patient.

Carriers move in unison to lower the patient onto the table to complete the carry.

### 1-17. STRETCHER PLACEMENT IN THE THREE-PERSON CARRY

a. **Order of Events for the Three Person Lift and Carry.** The mechanics of the lift and, to some extent, the carry were explained in the previous paragraph. In this segment, the placement of the stretcher in relation to the X-ray table and the carry itself is explained in more detail. Note that when actually performing this carry, you begin by placing the stretcher appropriately and locking the wheels. Then, you proceed to the lift and carry. The moves of the carry will vary somewhat according to the placement of the stretcher. See the chart below for the actual order of events.

#### ORDER OF EVENTS: THREE-PERSON LIFT/CARRY

1. Place stretcher appropriately in relation to table lock stretcher wheels.
2. Rock back and simultaneously lift and logroll patient toward you (three-person lift).
3. Carry the patient to the table (three-person carry).

b. **Three Options on Placing the Stretcher.** You have three different options in placing the stretcher in relation to the X-ray table. The stretcher and table may be: (1) at right angles, (2) in tandem with each other, or (3) parallel. The placement option you choose will depend on the configuration of the room, the type of X-rays you will be taking, and the special equipment that the patient might have to take into the room, such as an IV pole or oxygen tank.

c. **Stretcher at Right Angles to the X-ray Table.** This placement is the most practical if you have a lot of equipment with which to contend. You might be taking a cervical (C)-spine on a patient who needs the use of an oxygen tank and an IV pole. In that case, the wide open L-shaped area formed by the stretcher and the X-ray table when placed at right angles to each other (figure 1-42) would be suited to your special needs.

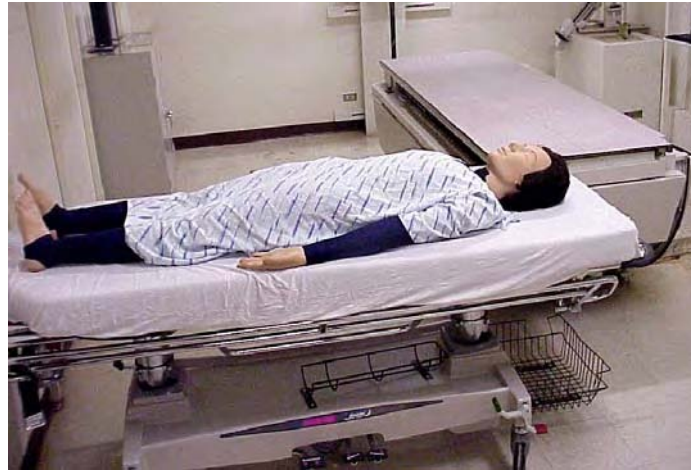

Figure 1-42. Placement option 1. Stretcher at right angles to X-ray table.

d. **Stretcher in Tandem with the Table.** In a mass casualty situation in which many X-rays must be taken quickly and in assembly-style fashion, you would place the stretcher in tandem with the table (figure 1-43). For such a mass casualty situation, you would place the stretcher in tandem with the table, to get the job done as quickly and efficiently as possible.

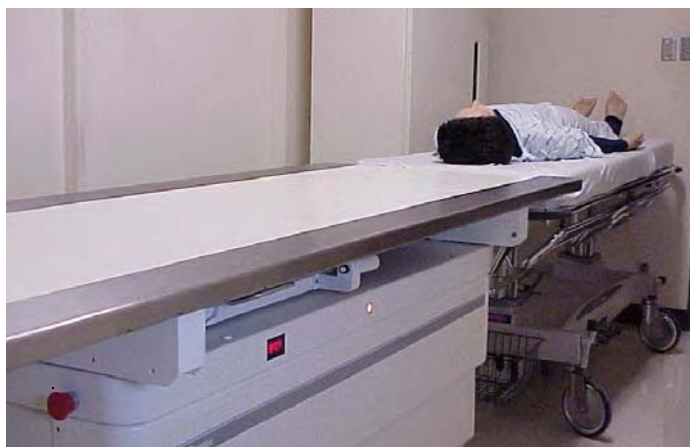

Figure 1-43. Placement option 2. Stretcher in tandem with table.

e. **Stretcher Parallel to and a Short Distance from the Table.** This placement is suitable for a patient undergoing surgery who must be X-rayed just before or after the operation. Since the X-ray rooms used for this purpose are very small, parallel placement (figure 1-44), which makes the best use of a confined area, would be your placement choice for this type of situation.

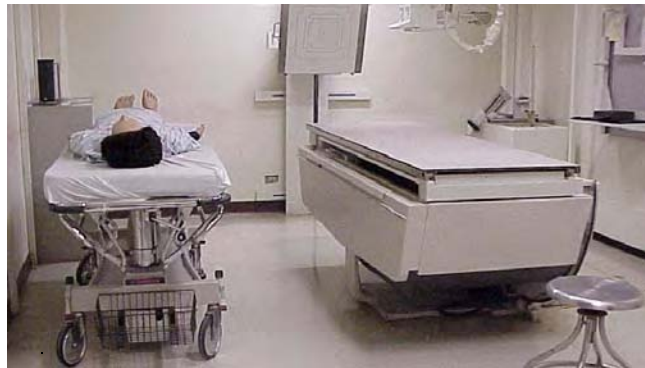

Figure 1-44. Placement option 3. Stretcher parallel to X-ray table.

f. **How Placement Affects the Moves of the Carry.** Depending on which placement option you have selected, you will have a different set of final moves to make in getting the patient from the stretcher to the X-ray table. These specific moves relate to the last part of the three-person carry. You have already lifted the patient off the stretcher as you rocked back and you have log rolled him toward your chest. You are now ready to move away from the stretcher and toward the table to actually place the unresponsive patient on the table. You have moved away from the stretcher with the limp and helpless patient weighing heavily in your arms and your arms be getting tired. You don't want to mess things up at this point, when you are two-thirds of the way through. Depending on which stretcher-to-table placement you have chosen, you will have slightly different final moves. These final moves of the three-person carry are described in figures 1-45 through 1-47.



Figure 1-45. With a right angle placement, carriers turn through 90 degrees in the final moves of the three-person carry.

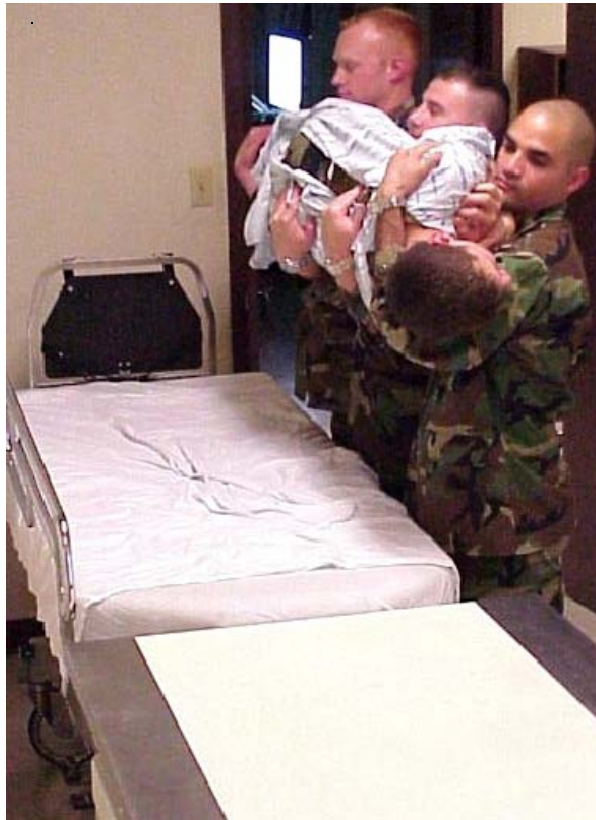

Figure 1-46. With a tandem placement, carriers step sideways in the final moves of the three-person carry.

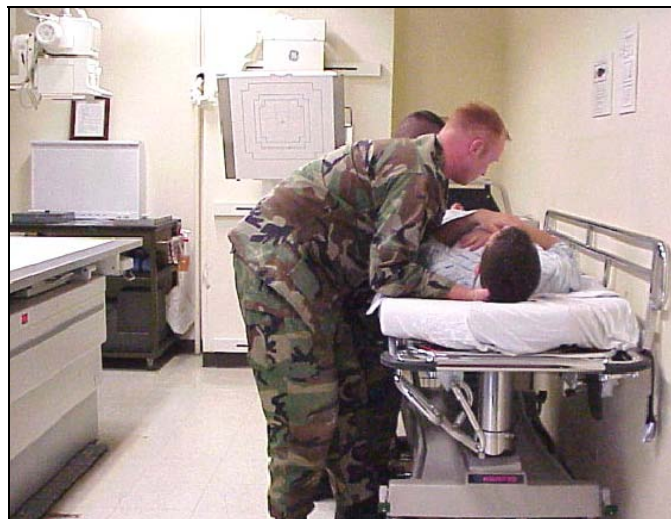

Figure 1-47. With the parallel placement, carriers turn in formation through 180 degrees, in the final moves of the three-person carry.

NOTE: Stretcher is a short distance from table (head of stretcher to foot of table.)

## 1-18. USING GOOD BODY MECHANICS THROUGHOUT THE THREE-PERSON CARRY

Don't lose sight of the principles of good body mechanics discussed earlier. They do apply to all the carries (also to every move you make, on and off the job, for that matter). The illustrations show that the three carriers preparing to lift the patient have their arms well under the patient, with the greatest support given to the patient's heaviest part, the midsection. Each corner has a relatively wide base of support (the legs are open). Each person is leaning in close to the patient in preparation for the lift. Knees are bent to prevent possible back strain. A wide base of support and flexed knees are also maintained, as the patient is lowered to the X-ray table. The carriers make sure to follow the patient down to the table with their bodies for greater support.

## 1-19. POSITIONING THE PATIENT ON THE X-RAY TABLE

a. **Good Alignment Critical.** With the three-person carry completed, the patient is now ready to be positioned in preparation for the X-rays that you will be taking. When positioning the patient, it is essential to ensure that the entire body is in good alignment with the X-ray table. The entire body, including the extremities, must be solidly positioned on the table so that the head, spinal column, and the pelvis are in a straight line.

b. **The Supine Position.** In this position, the patient is lying flat on his back (figure 1-48).

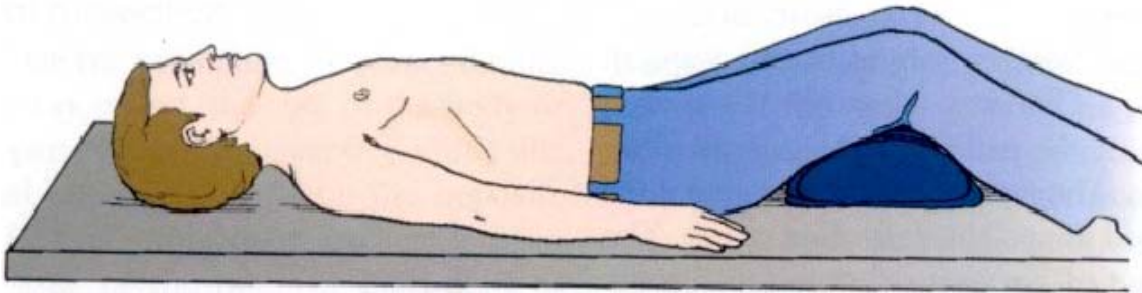


Figure 1-48. The supine position.

### STEPS TO ASSIST PATIENT TO ASSUME SUPINE POSITION

1. Patient's head, neck, and spine in a straight line.
2. Arms and legs parallel to body and hips.
3. Knees and feet straight.

c. **The Lateral Position.** In the lateral position, the patient is made to lie on his side (figure 1-49). For most X-rays, patients are customarily placed in the left lateral position. To help the patient assume this position, follow the steps outlined below.

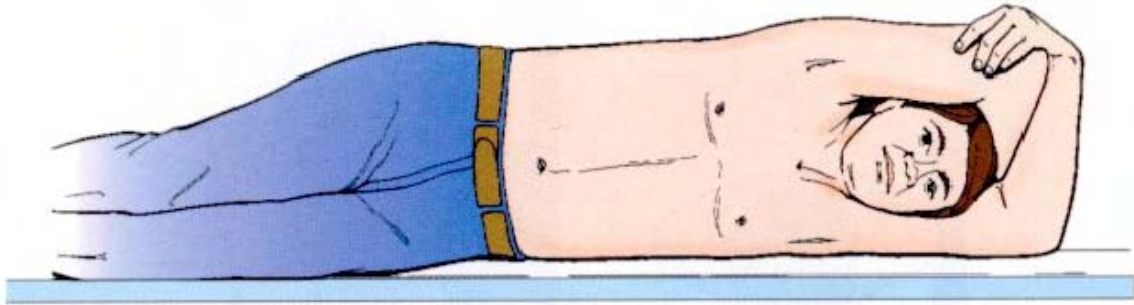


Figure 1-49. The left lateral position.

#### **STEPS TO ASSIST THE PATIENT TO ASSUME LATERAL POSITION**

1. Slide patient to side of the table to which back will be turned.
2. Abduct left arm (bring it away) from shoulder.
3. Flex right leg at knee and hip.
4. Bring right arm forward and across chest.
5. From left side of patient:
  - a. Grasp behind shoulders and pelvis.
  - b. Roll patient up, lean backwards and press thighs and knees against table.
6. Ensure that patient is in a good lateral recumbent (lying down) position.
  - a. Head, neck, and back are in straight line.
  - b. Patient is not lying on left arm.
  - c. Spinal column is parallel to tabletop.

d. **The Prone Position.** In the prone position, the patient is lying face down on his abdomen. Make sure that the patient's body is positioned as shown in figure 1-50.

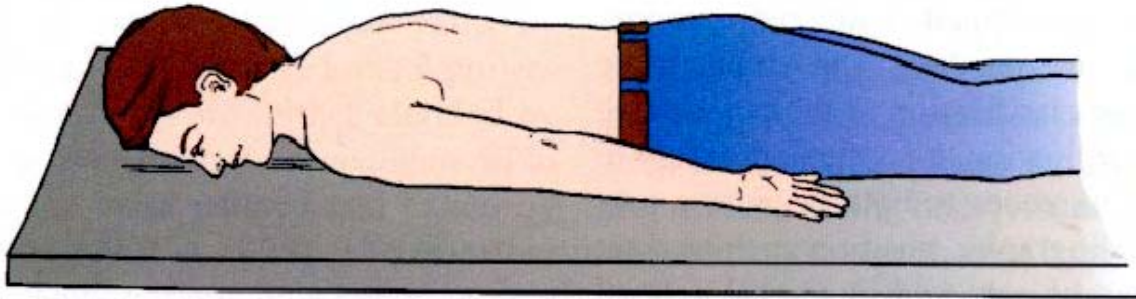


Figure 1-50. The prone position.

**STEPS TO ASSIST THE PATIENT TO ASSUME PRONE POSITION.**

1. Patient's head, neck, and spine in straight line.
2. Head turned to side.
3. Arms parallel to body.
4. Legs straight.

**1-20. SPECIAL SITUATIONS**

a. **Trauma.** Additional safety precautions must be taken when handling trauma patients in order to avoid inadvertently causing additional injury. Special precautions must be taken particularly when handling patients with skull, spinal, or long bone injuries or patients with fractures, dislocations, fresh casts, splints, and bandages. The positioning technique must be adapted to the patient so that he is moved as little as possible.

b. **Spinal Injuries.** Never move a patient with a possible spinal injury. A patient with a spinal injury should be brought in on a backboard. The X-rays will be taken directly through the backboard or across the X-ray table. Then, based on preliminary X-ray results, the physician will instruct you whether or not to move the patient.

c. **Ideal Setup.** The ideal setup for dealing with trauma patients is a specially equipped radiographic room adjoining the emergency room. Many hospitals now have such special units equipped with special radiographic equipment and stretchers with radiolucent tops. Severely injured patients can, thus, be examined in the position in which they arrive. If you do not have such a setup in your hospital, then the trauma patient must be moved as little as possible while being conveyed to the main radiology department. This patient should, of course, have precedence over non-emergency cases.

## SPECIAL PRECAUTIONS WHEN HANDLING TRAUMA PATIENTS

1. Move trauma patients as little as possible.
2. Never move a patient with a possible spine injury.
3. Never try to manipulate patient beyond his or her capabilities, if a fracture dislocation is suspected.
4. Do not remove splints or bandages unless so directed by the physician.

d. **Cast Care.** A patient with a cast requires special care. Remember that a fresh (wet) cast can be inadvertently compressed by rough handling, thus causing further injury. Incorrect handling (figure 1-51) can also exert pressure on the skin, resulting in impaired circulation. The correct way to handle a patient with a cast is with open hands (figure 1-52). An open hand provides a flat surface and helps avoid the danger of creating indentations in the cast.

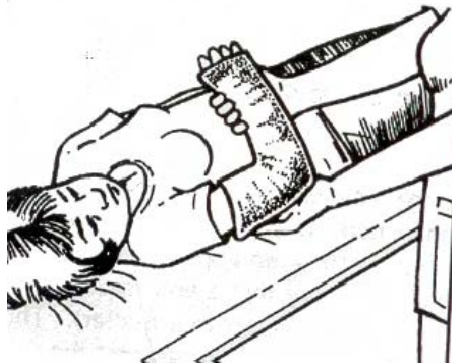


Figure 1-51. Danger! Indentations in the cast can impair circulation.

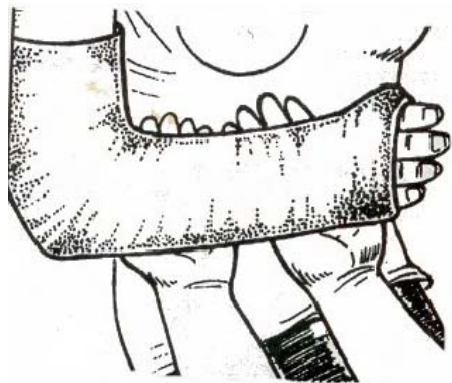


Figure 1-52. Handle cast carefully. Open hand lessens the chance of making indentations in a fresh cast.



e. **Checking Circulation of Patients with Casts.** It is important to, check for signs of impaired circulation. This check should be performed every 15 minutes. The signs of impaired circulation are listed in the chart below. If there is evidence of poor circulation, you will need to immediately notify the emergency room physician or nurse and ask them to check the cast.

#### **SIGNS OF IMPAIRED CIRCULATION**

1. Fingers or toes cold to the touch.
2. Patient complaints of burning or tingling.
3. Swelling.
4. Color changes in the nail bed (bluish color).
5. Numbness or inability to move.

#### **THE CARE OF A CAST**

1. Handle a fresh (wet) cast carefully.
2. Avoid grasping a fresh cast with your fingers.
3. Handle a cast with hands open.
4. Check the patient every 15 minutes for signs of impaired circulation.

**Continue with Exercises**

## EXERCISE, LESSON 1, SECTION II

**MULTIPLE-CHOICE.** For exercises 1 through 15, select the ONE word or phrase that BEST completes the statement or BEST answers the question.

1. Before moving a patient, you should:
  - a. Assess the patient's approximate weight, condition, mobility, strength, endurance, balance, responsiveness, and alertness.
  - b. Select the longest route to ensure a safe move.
  - c. Give detailed and lengthy instructions so that the patient knows exactly what to do.
  - d. Discourage the patient from assisting in the move to avoid mishaps and possible lawsuits.
  - e. Unlock all wheels on beds and gurney.
  
2. If the patient is mobile, you should.
  - a. Allow him to make the move unassisted to encourage the patient along on the road to recovery.
  - b. Provide your assistance; the patient may not be as strong as he thinks he is.
  - c. Use the draw-sheet pull or three-person lift.
  - d. Perform a two-person carry.
  
3. If the patient is unable to assist in the transfer from wheelchair to X-ray table you will need to:
  - a. Use a portable X-ray machine.
  - b. Move the patient yourself.
  - c. Find another person or persons to help you.
  - d. Reschedule the X-rays.

4. If a patient has an intravenous line and is capable of assisting in the move, you should:
  - a. Find another person to move the IV at the same time that you move the patient.
  - b. Have the patient hold IV during the move.
  - c. Remove the IV temporarily to ensure that it does not become dislodged.
  - d. Increase drip rate of the IV for the duration of the move.
  
5. Transport the patient on a stretcher rather than a wheelchair if the patient:
  - a. Has an IV.
  - b. Is an outpatient.
  - c. Cannot sit or stand for extended periods.
  - d. Is wearing a cast.
  
6. If moving a patient who is of average weight and able to assist, you will \_\_\_\_\_ to move him from a stretcher to a table.
  - a. Need someone to assist you.
  - b. Have to seek the help of two other movers.
  - c. Be able to transfer the patient by yourself.
  - d. Use the draw sheet pull method of transfer.
  
7. When transferring a patient from a stretcher to an X-ray table, be sure that:
  - a. The stretcher and table are parallel and that there is no space between them.
  - b. The wheels are unlocked.
  - c. The patient moves his legs first.
  - d. The stretcher is about three inches lower than the table.

8. The draw sheet pull or the three-person carry should be used if:
  - a. The technologist is feeling weak.
  - b. The patient is unable to assist or there is a stretcher to table height disparity that cannot be adjusted.
  - c. The patient has a fresh cast.
  - d. There is a long distance to travel.
  
9. In the \_\_\_\_\_ method, the bed sheet is loosened from either side of the bed and rolled up close to the patient's body to provide handholds for pulling and lifting the patient.
  - a. Three-person lift.
  - b. Three-person carry.
  - c. Draw sheet pull.
  - d. Patient-assisted move.
  
10. In the draw sheet pull, the carriers should be sure to move the patient:
  - a. In unison, so the head and feet move safely with the trunk.
  - b. Hips first.
  - c. At a ninety-degree angle from the stretcher.
  - d. Parallel to their bodies.
  
11. In \_\_\_\_\_, the patient is lifted and rolled with the patient's weight borne by the movers' upper arms and chests.
  - a. The three-person carry.
  - b. The draw-sheet pull.
  - c. The patient-assisted move.
  - d. All of the above.

12. In the three-person carry, the tallest mover stands near the patient's:
- Head.
  - Midsection.
  - Legs.
13. Which of the following is NOT a special precaution for handling trauma patients?
- Never move a suspected spinal injury patient.
  - Never manipulate patient beyond his capabilities.
  - Do not remove splints or bandages unless directed by the physician.
  - Never take X-rays.
14. Which of the following is NOT a sign of impaired circulation in a patient with a cast?
- Fingers or toes that are cold to the touch.
  - Swelling, burning, or tingling.
  - Color change, numbness, or an inability to move.
  - Itching.
15. Which of the following is NOT part of the special care required for patients with casts?
- Handle a fresh cast carefully.
  - Grasp a fresh cast gently with your fingers.
  - Check for impaired circulation every 15 minutes.
  - Handle a cast with open hands.

**IDENTIFICATION AND SEQUENCING . For exercises 16 through 21.** The steps of procedure for various methods of transporting or positioning the patient are listed below. For each exercise item, there is one step that is NOT part of the procedure and SHOULD NOT BE SELECTED. Indicate the correct sequence for the remaining steps that you have selected by numbering them on the space provided.

16. Number the applicable initial steps for transferring a patient from a wheelchair to an X-ray table using the numbers 1 through 6.
- a. \_\_\_\_\_ Your hands under patient's axilla.
  - b. \_\_\_\_\_ Brakes locked.
  - c. \_\_\_\_\_ Patient's hands on your shoulders.
  - d. \_\_\_\_\_ Wheelchair parallel to table.
  - e. \_\_\_\_\_ Footrests out of the way.
  - f. \_\_\_\_\_ Sheet rolled tightly.
  - g. \_\_\_\_\_ Stool nearby.
17. Number the remaining applicable steps for transferring a patient from a wheelchair to an X-ray table using the numbers 7 through 13.
- a. \_\_\_\_\_ Patient puts one hand on stool, the other across your shoulder.
  - b. \_\_\_\_\_ You lift while patient tries to stand.
  - c. \_\_\_\_\_ You pause; patient regains balance.
  - d. \_\_\_\_\_ You ease patient into sitting position.
  - e. \_\_\_\_\_ You place one arm around patient's shoulders and the other arm under his knees.
  - f. \_\_\_\_\_ Patient steps on stool and pivots, back to table.
  - g. \_\_\_\_\_ With single motion, patient places legs on table and lowers head and shoulders into supine position.
  - h. \_\_\_\_\_ Patient pivots slowly with minimal assistance.

18. Number the applicable steps for transferring a patient from wheelchair to X-ray table (patient unable to assist), using the numbers 1 through 5.
- a. \_\_\_\_\_ Movers assume their positions on either side of the chair.
  - b. \_\_\_\_\_ Patient hoists himself or herself onto the table.
  - c. \_\_\_\_\_ Wheelchair parallel to the table; patient facing foot end of table.
  - d. \_\_\_\_\_ Pivot wheelchair to face head of table.
  - e. \_\_\_\_\_ Mover on left, puts shoulder under patient's left axilla and left arm under the patient's left thigh.
  - f. \_\_\_\_\_ Mover on right, puts shoulder under the patient's right axilla and right arm under the patient's thighs.
19. Number the remaining applicable steps for moving a patient from wheelchair to X-ray table (patient unable to assist) using the numbers 6 through 10.
- a. \_\_\_\_\_ Movers assist the patient to lie down.
  - b. \_\_\_\_\_ Movers lift patient upon signal.
  - c. \_\_\_\_\_ Patient grasps mover's neck.
  - d. \_\_\_\_\_ Movers step forward and turn sideways to place patient on table.
  - e. \_\_\_\_\_ Movers grasp each other's wrists under patient's thighs.
  - f. \_\_\_\_\_ Movers join their free hands across patient's back.

20. Number the applicable steps for the draw-sheet pull method using the numbers 1 through 5.
- a. \_\_\_\_\_ Place stretcher parallel to X-ray table.
  - b. \_\_\_\_\_ Allow the patient to assist.
  - c. \_\_\_\_\_ In unison, the movers pull pt. toward them and across table.
  - d. \_\_\_\_\_ Movers lock all wheels.
  - e. \_\_\_\_\_ With one mover at head and shoulder level and the other at hip level, firmly grasp the sheet close to the patient's body.
  - f. \_\_\_\_\_ Movers lean across X-ray table and roll sheet in toward patient.
21. Number the applicable steps of the three-person carry, using the numbers 1 through 5.
- a. \_\_\_\_\_ Strap the patient in.
  - b. \_\_\_\_\_ Slide the patient to the edge of the area from which he or she is to be lifted.
  - c. \_\_\_\_\_ Patient can now be moved to the table.
  - d. \_\_\_\_\_ Position the stretcher at right angles to the end of the X-ray table.
  - e. \_\_\_\_\_ All three movers stand on the same side of stretcher that the patient has been edged toward and place bodies against the area on which the patient is lying.
  - f. \_\_\_\_\_ On command, the patient is lifted and rolled; weight borne in the upper arms of the movers.

**Check Your Answers on Next Page**



## SOLUTIONS, LESSON 1, SECTION II

1. a (para 1-9)
2. b (para 1-11a)
3. c (para 1-13a)
4. a (para 1-14c)
5. c (para 1-12a)
6. c (para 1-12b)
7. a (figure 1-25, steps)
8. c (paras 1-14a, 1-16a)
9. a (para 1-14e)
10. a (para 1-14b)
11. a (figure 1-39)
12. a (para 1-16b)
13. d (para 1-20c)
14. d (para 1-20e)
15. b (para 1-20d)
16. Wheelchair to table (para 1-11a)
  - a. 6
  - b. 2
  - c. 5
  - d. 1
  - e. 3
  - f. ---
  - g. 4

17. Wheelchair to table (para 1-11a)
- a. 9
  - b. 7
  - c. 8
  - d. 11
  - e. 12
  - f. 10
  - g. 13
  - h. ---
18. Wheelchair to table, patient unable to assist. (para 1-11b)
- a. 3
  - b. ---
  - c. 1
  - d. 2
  - e. 4
  - f. 5
19. Wheelchair to table, patient unable to assist (para 1-11b)
- a. 10
  - b. 8
  - c. ---
  - d. 9
  - e. 6
  - f. 7
20. Draw sheet pull (para 1-14)
- a. 1
  - b. ---
  - c. 5
  - d. 2
  - e. 4
  - f. 3
21. Three-person lift (para 1-16)
- a. ---
  - b. 1
  - c. 5
  - d. 2
  - e. 3
  - f. 4

**End of Lesson 1**

## LESSON ASSIGNMENT

### LESSON 2

The Order of Procedure.

### LESSON ASSIGNMENT

Paragraphs 2-1 through 2-10.

### LESSON OBJECTIVES

After completing this lesson, you should be able to identify (largely by selecting from alternatives):

- 2-1. Identify the order of procedure.
- 2-2. Identify the five elements involved in projecting a professional image to patients and colleagues.
- 2-3. Identify the definitions of positioning terms (visualize, part to film reference, alignment, film anatomical structure, central ray, central ray to part reference, and film rundown).
- 2-4. Identify film size and film rundown options.
- 2-5. Identify differences between exposures taken "Bucky" vs. "non-Bucky".
- 2-6. Identify definitions of source to image receptor distance (SID), cone field, and technique chart.

### SUGGESTION

After reading and studying the assignment, complete the exercises at the end of this lesson. These exercises will help you to achieve the lesson objectives.

## LESSON 2

### ORDER OF PROCEDURE

#### Section I. ORDER OF PROCEDURE (STEPS 1 AND 2)

##### 2-1. INTRODUCTION

a. This lesson covers procedures that are essential preparatory steps to positioning the patient for any study. The lesson describes the order of procedure. Steps 1 and 2 of the order of procedure are covered in section I; steps 3, 4, and 5 are covered in section II.

b. Before you can effectively apply specific positioning techniques, you must have a working knowledge of the sequence in which X-ray procedures, in general, are performed. Another essential prerequisite is to understand the importance of maintaining a professional image at all times. You must also know the relevant specialized language (terminology) of positioning used in radiography and you must know film sizes and options. Therefore, these topics are covered in this lesson. Actual positioning, per se, begins in lesson 5 and continues in MD0962, Standard Positioning Techniques II.

##### 2-2. COMPETENCE AND PROFESSIONALISM

No matter what the particular study you are performing and no matter what the positioning technique involved, there is a professional image that you must maintain at all times in order to function effectively. Projecting professionalism is important because the way you act as an individual reflects not only upon yourself, but upon the field of X-ray technology and the health care profession as a whole.

##### 2-3. PROJECTING A PROFESSIONAL IMAGE

The way you come across can also enhance or undermine the patient's confidence in you and the entire team of health providers. It is not enough to know what you are doing. Almost of equal importance is the matter of appearing to know what you are doing by behaving in a professional fashion. You will project professionalism if you: are technically competent, demonstrate a caring yet controlled attitude, and appear well-groomed. (Taking a correspondence course like this one helps you maintain or enhance your knowledge and skills. While, strictly speaking, a course relates to competence, taking a course also contributes your professional image because it bolsters your confidence. So, competence and professionalism are more subtly intertwined than you might think.) As a professional, you must also project calm, confidence, and control over your emotions in all dealings with both patients and colleagues. Finally, you must look professional by being clean and well groomed. The components of a professional image bear repeating. See the chart that follows.

**A PROFESSIONAL IS:**

COMPETENT  
CARING  
CALM  
IN CONTROL  
WELL GROOMED

**2-4. THE WORKING SIDE OF THE TABLE**

It is so obvious that it may not seem worth mentioning that you should stay on the working side of the table (figures 2-1 and 2-2). Some beginning technologists, especially in Phase II of initial training, attempt to work from the side near the wall. They may be tempted to work this way because of left-hand dominance or personal preference. Working from the encumbered side (that is, the side where the X-ray tube is connected) is not efficient and can be dangerous. You risk tripping over the cables. In addition, it is much more difficult to access the patient and equipment from that side. So, remember to stay on the working side of the table, at all times.

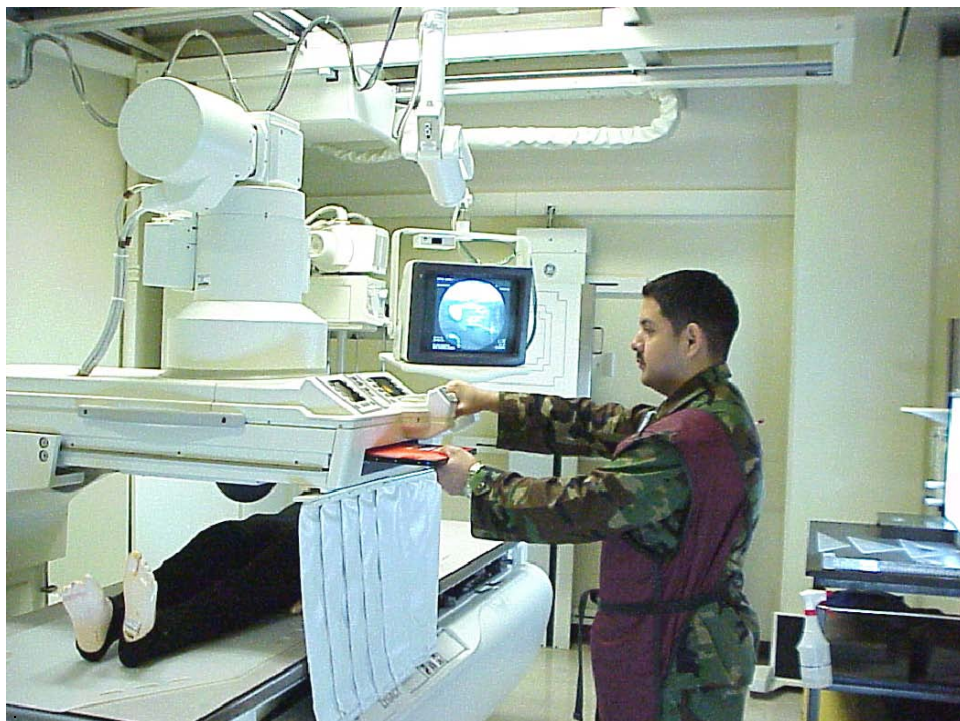

Figure 2-1. A simple thing like staying on the working (unencumbered) side of the table shows competence and projects a professional image.

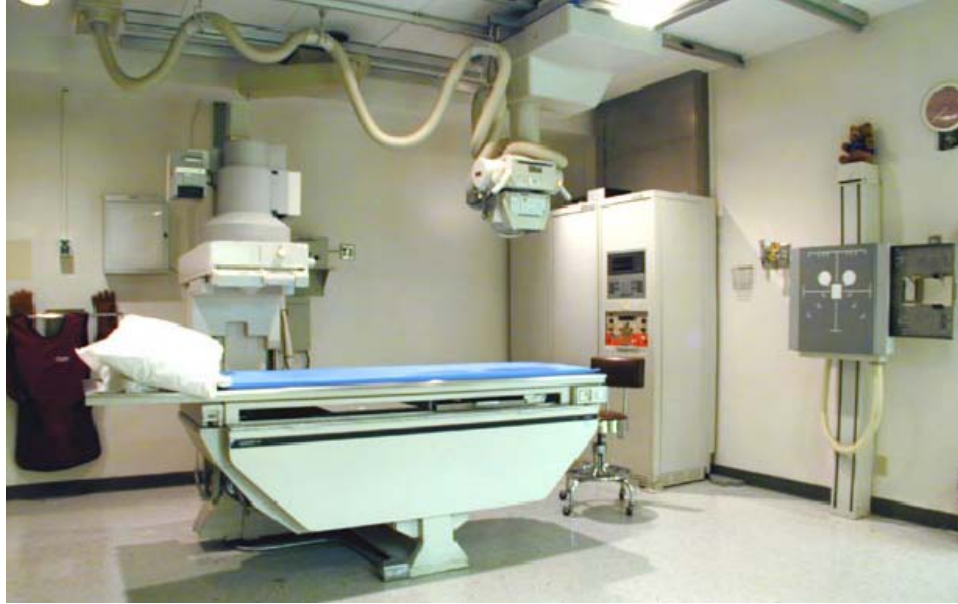

Figure 2-2. Another view of the working side of the X-ray table.

## 2-5. THE ORDER OF PROCEDURE

There is a logical sequence to performing the preparatory steps that precede the actual taking of an X-ray or performance of an examination. This logical sequence of events is referred to as the order of procedure. The order of procedure is broader in scope than the specific steps of any one particular exam or view such as positioning the right arm for an anteroposterior (AP) distal forearm. It involves a sequence that should be followed before any examinations, view, or study. By so doing, you will work more efficiently. Once you are experienced, the order of procedure will come naturally to you. The inner logic of the sequence becomes self-evident through practice. But, in the beginning, you will have to be more conscious about applying the correct order of procedure. The sequence at steps, or order of procedure, is summarized in the following chart. For now, we will be considering step 1 of the order of procedure, patient preparation.

### ORDER OF PROCEDURE

1. Prepare patient.
2. Adjust control panel.
3. Select table factors.
4. Position patient.
5. Take exposure.

## 2-6. ORDER OF PROCEDURE, STEP ONE: PATIENT PREPARATION

a. **Checking the X-Ray Request Slip (SF 519B).** To prepare the patient, you must know who the patient is and why he has been sent to the radiology department. By checking the patient's SF 5198, you will be able to verify a number of things: the patient's identity, the type of exam or X-ray required, whether or not artifacts will have to be removed, whether gowning is necessary, whether a contrast medium such as barium or conray is to be administered, and whether the exam was scheduled or not.

b. **Removing Artifacts.** Rings, wrist watches, necklaces, earrings hairpins, dentures, and other such objects should always be removed from the area to be examined. They should also be removed if there is a chance that they might project later the region of interest. Anything that could obstruct the examination should be removed. For example, when examining the skull, not only necklaces and earrings, but dentures, removable bridgework, and hairpins should be removed. The removal of artifacts is very important. If you should forget to remove a necklace before taking a study of the chest (figure 2-3), you will have to repeat the exam, thus exposing the patient to unnecessary additional radiation and delaying the overall operation of the department, as you keep other patients waiting.

**artifacts:** anything not intended to be imaged on the radiograph other than the anatomy of the patient.

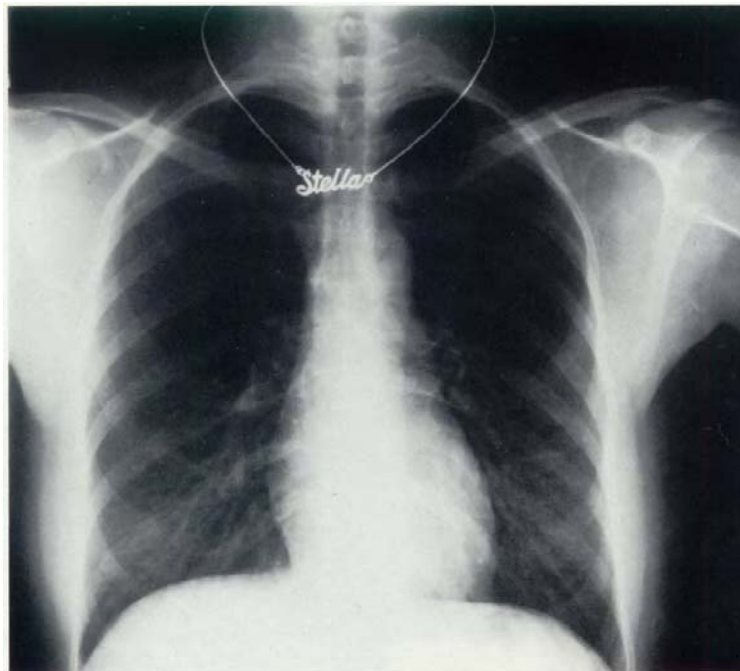


Figure 2-3. By forgetting to have the patient remove her jewelry, the RT is responsible for needless repeat exams

c. **Gowning and Draping.** As far as possible, all clothing should be removed from the part being examined. Generally, both male and female patients are asked to don gowns for projections to the femur through the abdomen. For examinations involving the thorax and neck, female patients should be instructed to put on a gown, whereas male patients are simply told to remove their clothing from the waist up. (However, male patients should be afforded the opportunity to put on a gown if they so desire.) The opening of the gown is usually to the back with the tie string knots loosened in the area of exposure.

d. **Sheet for Lower Extremities.** A sheet may be used to cover the patient's lower extremities. The sheet should be loose enough to allow the area under examination to be exposed without embarrassment to the patient. When changing the patient's position (for example, from the supine to lateral position), you should help to keep the gown closed and see that the sheet covers underlying parts. The patient should never be exposed unnecessarily.

**ORDER OF PROCEDURE, STEP 1**

1. Verify patient identity.
2. Remove artifacts.
3. Gown and drape.
4. Cover with sheet, if applicable.

**2-7. ORDER OF PROCEDURE STEP 2: THE CONTROL PANEL**

**ORDER OF PROCEDURE**

1. Prepare patient.
2. **Adjust control panel.**
3. Select table factors.
4. Position patient.
5. Take exposure.

a. **Measuring the Body Part.** Before setting technique factors on the control panel, you need to measure the body part to be radiographed. A measuring device known as a pair of calipers can be used to determine the thickness of the body part. Thickness of the body part is important as it will determine the technique factors required.



b. **Setting the Technique Factors.** Radiographic technique affects the quality of the X-ray and the film density; it also influences patient dose. The control panel, the heart of the X-ray system, controls the X-ray tube output through the technique factors. Based on measurement of the part, you can set the technique factors for milliamperere seconds (mAs) and kilovoltage peak (kVp). Required film density and contrast can be obtained by adjusting either the mAs up to 1000 or applying an extended kilovoltage range up 150 kVp, where applicable. By balancing these factors (mAs and kVp) correctly to make the necessary adjustments, you can then regularly produce radiographs of high technical quality and diagnostic value. With experience, you will learn to make quick factor exchange calculations between mAs and kVp.

**film (radiographic) density:** quantify of blackness (exposure) appearing on radiograph; photo-radiographic property that affects image visibility; without density, contrast couldn't be achieved film would be clear.

**contrast (scale):** a noticeable difference between adjacent radiographic densities seen as varying shades of gray on the radiograph.

(1) Milliamperere-seconds (mAs). The milliamperere-seconds (mAs) determines the length of time the patient is exposed to radiation. Milliamperage (mA) is measured in thousandths of an ampere. Selecting a given mA station (setting) controls the amount of current (electrons) flowing from the negative cathode filament wire of the X-ray tube. One of the cardinal rules of radiation protection is to keep the time of exposure to the minimum necessary to obtain the desired view. The milliamperere-seconds (mAs) setting controls the time of exposure and provides the required film density (blackness or exposure). Correct exposure in combination with optimum kilovoltage peak (kVp) produce the most suitable density and contrast that can be obtained. Over-exposure results in excessive density and low contrast. Underexposure leads to a lack of density and contrast.

**milliamperage:** the number of electrons flowing from the cathode to the anode end of the X-ray tube, measured in thousandths or an ampere.

**milliamperere seconds (mAs):** the milliamperage multiplied by the duration of exposure in seconds.

**cathode:** negative end of X-ray tube, source from which electrons flow.

(2) Kilovoltage peak (kVp). The kilovoltage peak or kVp determines the strength of the X-ray produced. The "k" is Latin for one thousand. The "v" in kVp stands for voltage. Thousands of volts of electricity (kilovolts) are needed to send the electrons from the cathode to the anode of the X-ray tube to produce X-rays suitable for penetrating human tissue. (The kVp is measured in kilovolts because regular voltage would lack the force to penetrate human tissue.) The "p" or peak in kVp stands for the maximum voltage in each burst of electron energy, produced in the pulsations of current within the X-ray tube. If you set the X-ray machine at 90 kVp, it means that each burst peaks at 90,000 volts. The voltage is less before and after the peak. Increasing the kVp increases the speed with which electrons travel from the tube filament across the X-ray tube, which, in turn, creates a shorter wavelength, a higher frequency, and greater penetrating power. See figures 2-4 and 2-5.

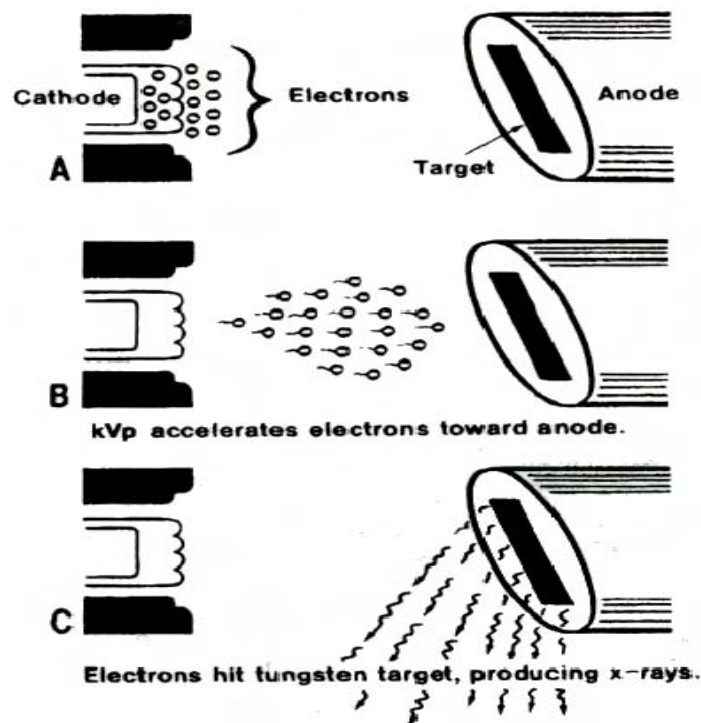


Figure 2-4. X-rays are produced when electrons from a cathode filament accelerate toward an anode target, where the electrons are stopped.

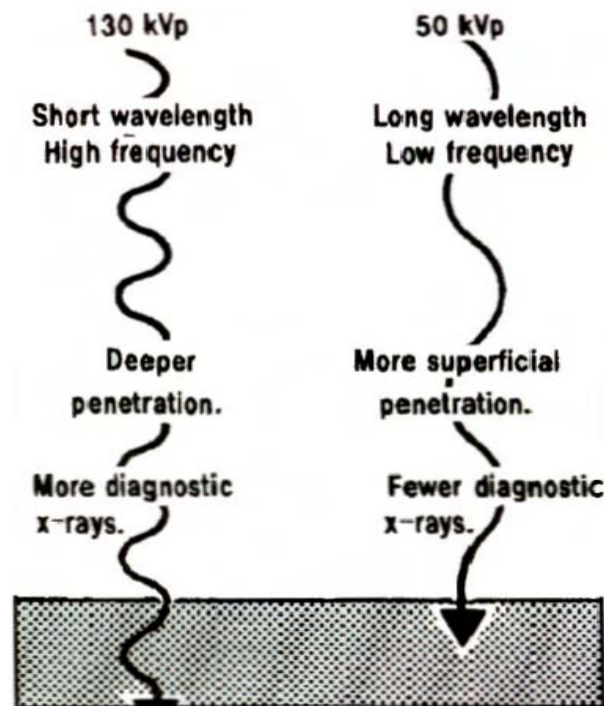


Figure 2-5. The higher the kVp, the deeper the penetration of the X-ray into the film, the greater the quantity of diagnostic X-rays.

**kilovolt:** unit of electromotive force equal to 1,000 volts of electricity.

**voltage:** the electrical pressure that causes electrons to move; measured in volts.

**kilovoltage peak (kVp):** the very highest voltage occurring at any time during an electrical cycle; the peak kilovoltage used in making an X-ray exposure.

(3) Set Bucky, if applicable. Once you have set the technique factors for mAs and kVp, you are ready to make the non-Bucky/Bucky selection, which is determined by the thickness of the body part to be radiographed. If the Potter-Bucky diaphragm (Bucky) is to be used for the examination, a switch marked Bucky can be activated. The Bucky is a sliding tray like device found just below the table on which a patient lies during the X-ray examination. The film is placed inside the Bucky tray and held in place by a pair of jaws that center the film under the midline of the table once the tray is pushed firmly closed (figures 2-6 and 2-7).

**Bucky (Becky-Potter diaphragm):** a sliding tray like device found just below the X-ray tube that reduces secondary (scatter) radiation reaching the film.

**scatter radiation:** a form of secondary radiation created when radiation has been deviated in direction during passage through thick body parts.



Figure 2-6. The radiologic technologist is inserting the X-ray cassette into the Bucky tray to get better definition on a thick body part.



Figure 2-7. When you insert the film into the Becky tray, make sure that the film is securely locked into the tray. The film shown will be off center from the central ray because it has not been secured.

**ORDER OF PROCEDURE, STEP 2**

1. Measure body part.
2. Set techniques factors on control panel for mAs and kVp.
3. Set Bucky or non-Bucky.

**Continue with Exercises**

## EXERCISES, LESSON 2, SECTION I

**MULTIPLE-CHOICE, For exercises 1 through 6,** select the ONE word or phrase that BEST completes the statement or BEST answers the question.

When you have completed all of the exercises to your satisfaction, turn to the solutions that immediately follow the exercises and check your answers.

1. To perform effectively as a health care provider, to project an image of professionalism, and to inspire the confidence of the patient you must display:
  - a. A knowledge of the accreditation and licensure processes.
  - b. A willingness to try experimental procedures.
  - c. Your real reactions and emotions to colleagues and patients even if they are negative.
  - d. Technical expertise, a controlled yet caring professional attitude, and a well-groomed appearance.
  
2. The logical sequence of steps for efficiently performing the steps preliminary to the actual view or examination is referred to as the:
  - a. Order of procedure.
  - b. Rank order.
  - c. Three point check.
  - d. Statute of limitations.
  
3. In the exposure room you should stand \_\_\_\_\_ for ease of access and maximum efficiency.
  - a. On the side of the table where the cables are located.
  - b. On the working side of the table.
  - c. On the side that best complements your particular hand dominance.
  - d. Behind the lead wall.

4. According to the order of procedure, initial patient preparation involves:
  - a. Detailed instructions on dietary restrictions.
  - b. Processing the patient's request form.
  - c. Removal of artifacts, gowning, and draping.
  - d. Explaining table factors to the patient.
  
5. Adjusting the control panel settings involves:
  - a. Measuring the body part and setting the technique factors.
  - b. Doing the film run down (FRD) and measuring the source to image distance (SID).
  - c. Setting the central ray (CR) angle and the cone field, if applicable.
  - d. Doing the three-point check.
  
6. The technique factors consist of the:
  - a. Milliampere seconds (mAs), the kilovoltage peak (kVp), and Bucky selection, if applicable.
  - b. Film run down (FRD), the letter marker (LM), and the central ray (CR) angle.
  - c. Source-to-image distance (SID) and the cone field (CF), if appropriate.
  - d. Source-to-image distance (SID), central ray (CR) angle, and letter marker (LM).

**SEQUENCING.** For **exercise 7**, indicate the correct sequence of the steps by writing the appropriate number in the space provided.

7. What is the correct order of procedure for the steps required to complete a view or examination, listed below?
- a. Take the exposure. \_\_\_\_\_
  - b. Position the patient. \_\_\_\_\_
  - c. Prepare the patient. \_\_\_\_\_
  - d. Set the table factors. \_\_\_\_\_
  - e. Make the control panel adjustments. \_\_\_\_\_

**Check Your Answers on Next Page**



## **SOLUTIONS, LESSON 2, SECTION I**

Be sure to re-read and study the paragraph(s) pertaining to any exercises you might have answered incorrectly. The relevant paragraph(s) is (are) listed after each of the answers below.

1. d (para 2-2)
2. a (para 2-5)
3. b (para 2-4)
4. c (para 2-6)
5. a (para 2-7)
6. a (para 2-7b)
7. a=step 5  
b=step 4  
c=step 1  
d=step 3  
e=step 2 (para 2-5 chart)

## Section II: ORDER OF PROCEDURE (STEPS 3 THROUGH 5)

### 2-8. ORDER OF PROCEDURE, STEP 3: SELECT TABLE FACTOR

a. **Table Factors in General.** As the term "table factors" suggests, step 3 of the order of procedure deals with the functioning of the X-ray table itself. Should you angle the tube? If so, by how much? Where are the left and right letter markers for a left or right hand, or the marker for an open or closed mouth to be located? These and other considerations regarding the X-ray table are resolved through the use of the table factors discussed below.

#### ORDER OF PROCEDURE

1. Prepare patient.
2. Adjust control panel.
- 3. Select table factors.**
4. Position patient.
5. Take exposure.

b. **Film Run Down and Letter Marker.** The first table factors are the film run down (FDR) and letter marker (LM). The FRD lets you set all factors relating to the film itself.

#### TABLE FACTORS

- 1. Film run down and letter marker.**
2. Central ray angle.
3. Source to image receptor distance (SID).
4. Conefield.

(1) Physical location of film. Earlier, you determined whether or not the X-ray would be Bucky or non-Bucky based on body part thickness. Now you will actually place the film in the appropriate location in the Bucky tray or on top of the X-ray table.

(2) Size of film. You will also need to determine the size film needed for the type of examination you are going to perform. The three basic film sizes are: 8x10 (inches), 10x12 (inches), and 14x17 (inches). Besides the basic sizes, however, there are also a few other sizes used for special studies (5x7, 14x14, and 9 1/2 x 9 1/2). Consider, too, whether you will get multiple exposures on the same film. Taking multiple exposures on the same film permits you to get more than one view (see figure 2-8). This facilitates comparison and saves film.

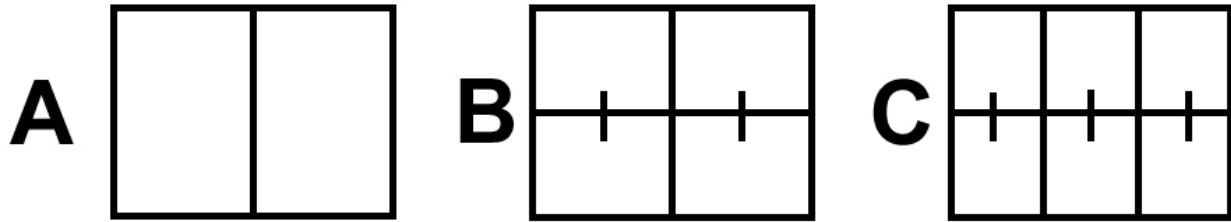


Figure 2-8. Multiple exposures may be obtained on the same film: with 2 (as in A), 4 (as in B), and 6 views per film (as in C).

(3) Direction of film. Does the film have to be placed lengthwise (LW) or crosswise (CW) to the part being radiographed? Correct film placement is crucial to ensuring that the structure of anatomical interest is adequately demonstrated.

(4) Manner of use. Will the X-ray be taken with a Bucky (B) or non-Bucky (NB)? As stated earlier, denser anatomical structures may require the use of the Bucky to reduce scatter radiation (fog).

(5) Letter marker (LM). It is important to affix the correct letter markers to the film before taking the exposure. Be sure to place the correct letter marker on the side of the film corresponding to the side of the body of anatomical interest. For example, place a left marker on the left side of the film. For a patient facing the film in a PA position, a left marker would be appropriately placed on the left side of the film, the part of the film corresponding to the left shoulder. If an AP view of the right arm, leg, or hand were needed, a right marker would be placed on the film. The film blacker should be placed so that it is out of the area of interest to be visualized (demonstrated).

**visualize (demonstrate):** to obtain a clear radiographic image of the primary and surrounding anatomical structures that are of clinical interest.

(6) Film identification. Proper identification includes the patient's name or code, the date the films are being taken, and the facility where taken. The age of the patient or date of birth is also recommended. The marker is usually placed on the outer margin of the cassette as there is not a lot of clearance between the top of the cassette and the grid. By placing the marker on the outer margin, there is less chance of it being misplaced or overlying and, thus, obscuring structures you are trying to visualize. See figures 2-9 and 2-10.

**mislabeling the film:** for example, confusing the right with the left side of the chest; can lead to misdiagnosis and a failure to treat the condition.

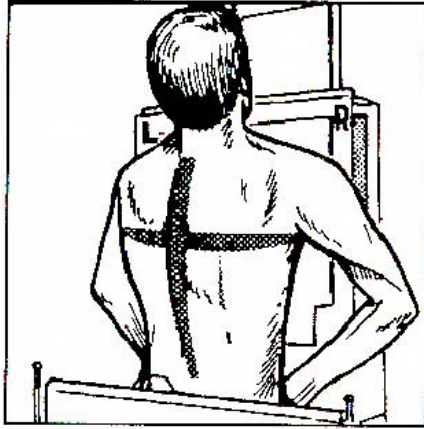


Figure 2-9. The posteroanterior (PA) position is a frequently requested view. The adult patient's film is correctly labeled, as shown.




Figure 2-10. This film is mislabeled (since the infant is turned toward you, not away from you as in the previous view). Don't label the film as for the PA view.

**FILM RUN DOWN AND LETTER MARKER**

1. Physical location of film.
2. Size of film
3. Direction of film.
4. Manner of use.
5. Letter marker.

c. **Central Ray (CR) Angle.** The second table factor to be adjusted is the angle of the X-ray tube, more commonly referred to as the central ray (CR) angle. The beam of rays, or central ray, should be projected onto the film at the desired angle. Accurate positioning of the part and correct centering of the central ray are of equal importance in obtaining a diagnostic radiograph. The central ray is centered to the film or portion of the film used. You will need to adjust the CR angle according to the part to be X-rayed and the views that are desired.

**central ray (CR) angle:** the angle and direction of the primary beam in relation to the film or anatomical part.

d. **The Source-to-Image Distance.** The third table factor that must be set is the source-to-receptor distance (SID). (The source is the tube focal spot; the image receptor is the film.) The SID is the distance in inches between the tube focal spot and the film (figure 2-11). The SID is sometimes referred to as the anode-film distance or the local spot film distance. The source-to-image receptor distance may be measured using a digital read-out or by using the tape measure on the tube head. For a vertical perpendicular central ray, use the automatic digital read-out of the SID. Located on the overhead tube scale, it provides a digital readout of the distance between the tube focal spot and the film as you raise or lower the table (figure 2-12). For an angled central ray, use the tape measure located on the side of the collimator (figure 2-13). A cardinal rule of radiation protection is that the distance between the radiation source and the radiologic technologist should be as great as possible. For tabletop procedures, the SID should be 40 inches from the tube focal spot to the tabletop (figure 2-14). For Bucky procedures, the SID should be 40 inches to the Bucky tray (38 inches to the tabletop and 2 inches from tabletop to Bucky) (figure 2-15). For upright procedures, such as a chest X-ray, the SID should be 72 inches to the film (figure 2-16).

**tube focal spot:** the area on the anode target where cathode electrons strike to produce X-rays.

**image receptor:** the radiographic film.

**source-to-image receptor distance (also referred to as anode-film, focal film, or focal spot-film distance):** distance in inches between X-ray tube focal spot and the film.

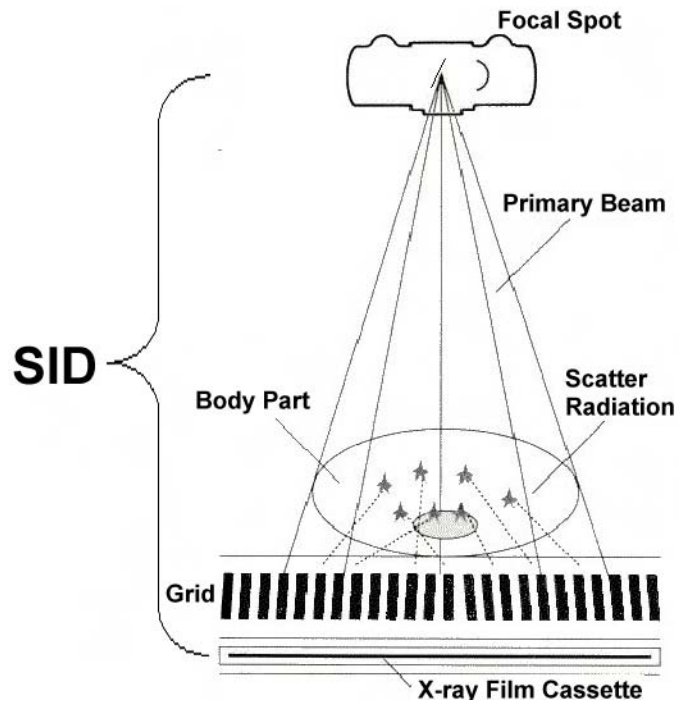


Figure 2-11. The source to image receptor distance (SID) is the distance between the tube focal spot and the film.

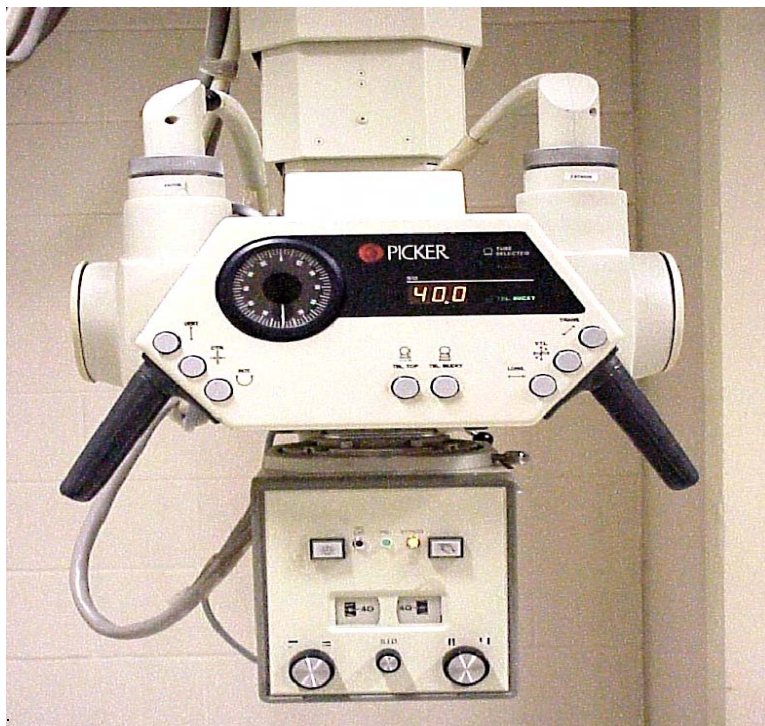

Figure 2-12. The overhead tube scale, which provides a digital readout of the SID, should be used for a vertical perpendicular central ray.

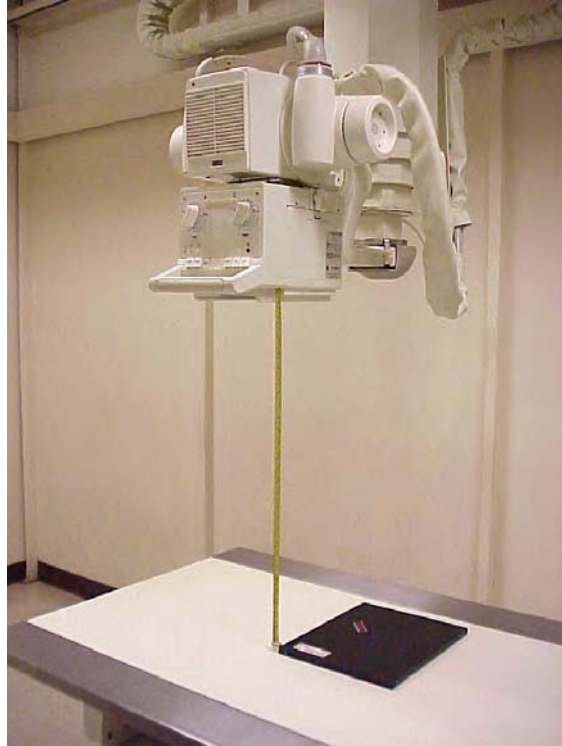


Figure 2-13. The tape measure, located on the side of the collimator, should be used to measure the source-to-image receptor distance (SID) for an angled central ray (CR).

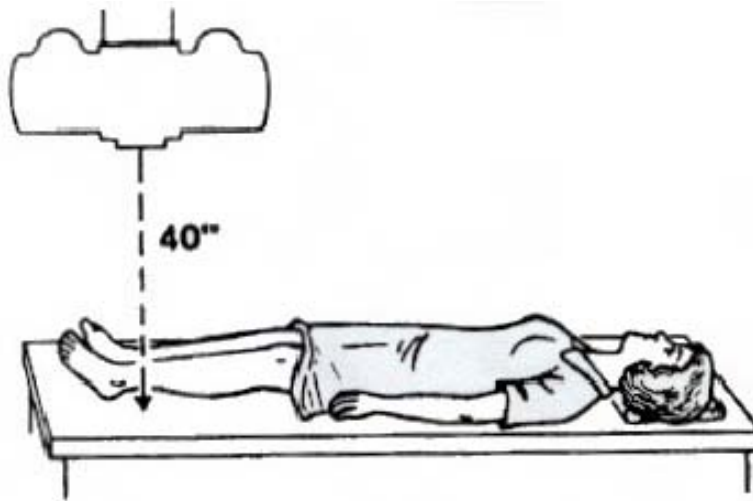


Figure 2-14. For tabletop procedures, the SID should be 40 inches from the tube focal spot to the tabletop.

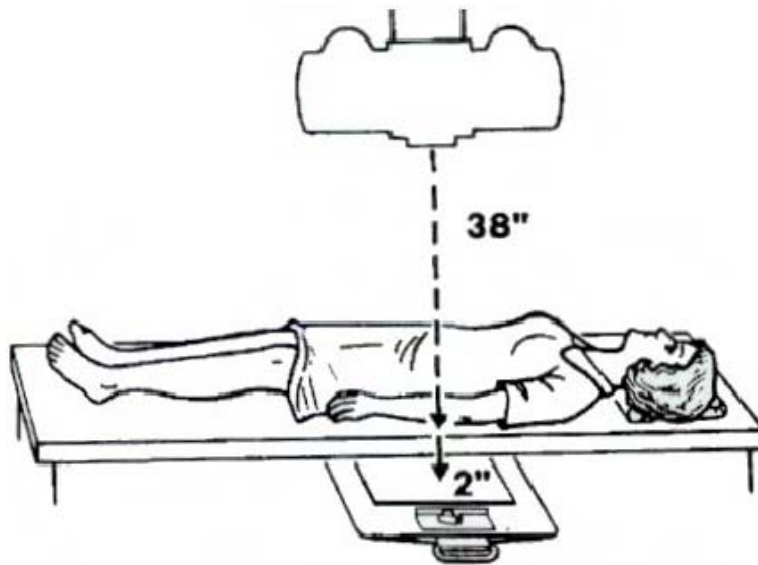


Figure 2-15. For Bucky procedures, the SID should be 40 inches to the Bucky tray (38 inches to the tabletop and 2 inches from tabletop to Bucky tray).

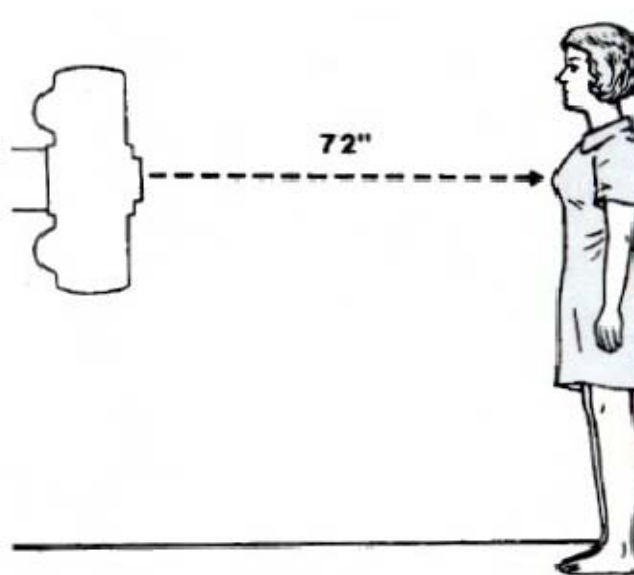


Figure 2-16. For upright procedures, such as a chest X-ray, the SID should be 72 inches to the film.



e. **The Conefield.** The fourth and final table factor is the cone field (CF). The cone field or area of the beam of radiation striking the film must be reduced to only that area required to produce the view requested. By adjusting the cone field setting, the size of the radiation field is set (figure 2-17). You may specify a cone field of 4 inches, 6 inches, 8 inches, or any other size, as required, to produce the desired view. Collimators made of lead or other metal with high radiation absorption power are used to restrict the cone field by so confining the beam. The peripheral (extra) radiation strikes and is absorbed by the intervening metal while only the rays in line with the exit aperture are transmitted to the exposure field. Or, you may opt for a full field coverage (FFC), that is, no coning down to limit the area of exposure. This may be appropriate for specific visualizations of the anatomy. Most views will require full field coverage (FFC), that is, if half the cassette is used, then the beam of radiation covers the entire half. If the whole cassette is used, the beam covers the entire cassette and there is no restricted cone field. Other views, such as those of the sinuses and the cervical spine will require a restricted cone field.

**collimation:** the limiting of the beam of radiation to the required dimensions.

**cone field:** the area of the beam of radiation striking the film.

**full field coverage (FFC):** total exposure of the area of the film cassette that is used: no coning down.




Figure 2-17. The patient is positioned with the cone field set.

## 2-9. ORDER OF PROCEDURE STEP 4: POSITIONING THE PATIENT

a. **Patient Positioning.** The fourth step of the order of procedure is to position the patient it is the process of assisting the patient onto the X-ray table and into one of the following positions: supine, prone, lateral, or oblique.

b. **Part Position.** Another component of positioning the patient is the placement of a specific body part in relationship to the CR. The patient is turned moved around as needed until the body part is centered with the CR. You must check for the correct placement of the palpation point or anatomical part in relation to the cassette. You will recall that the palpation point is the anatomical structure that serves as a landmark or guide for correctly demonstrating the desired area of interest on the cassette. For example, for an AP shoulder with internal rotation, the acromion process of the shoulder must be placed 2 inches below the upper film border (figures 2-18 and 2-19) or you will end up losing the required anatomy and have to repeat the X-ray to get a complete radiograph.

**palpation point:** anatomical structure(s) that serve(s) as a landmark or guide for correctly demonstrating the body part on the cassette.

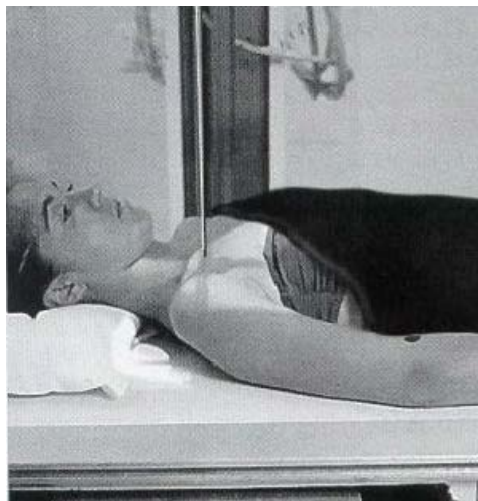


Figure 2-18. For an AP shoulder with internal rotation, the acromion process must be correctly placed or you will lose important anatomy.

## AP Shoulder with Internal Rotation

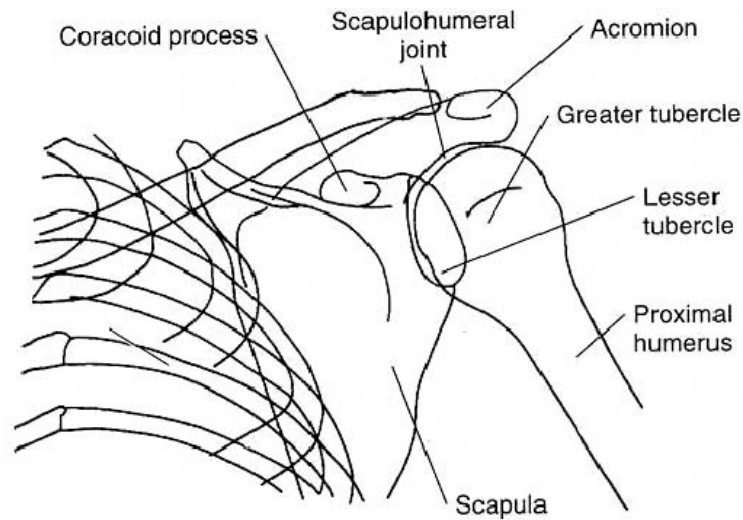


Figure 2-19. The acromion process of the shoulder must be 2 inches below the upper film border.

c. **Immobilization.** You must instruct the patient to hold still and not to breathe at the appropriate times. You may also wish to use positioning sponges and sandbags and straps (figure 2-20) that won't interfere with the examination to help hold the patient still for the exposure.



Figure 2-20. Sponges, sandbags, and straps may be used for immobilizing the body part to be radiographed.

d. **Shielding.** Your next step after immobilization is to see to the shielding of the patient with a lead apron. It is important to protect the patient's body from scatter radiation. Shielding of the gonadal area (ovaries and testes), when possible, is critical. If the gonads are not involved, you still need to protect the rest of the body from scatter radiation, where feasible. For example, when you are radiographing the hand, you should shield the patient's abdomen and vital organs. There are very few exams for which you do not shield the patient. For a barium enema (BE), a lead apron over a female's gonads is not feasible as the shield would obstruct the area of interest. If a mortally wounded accident victim were brought in for X-rays, there would probably not be time to shield the patient. If, however, other individuals are present to assist in the exam, they should be shielded (as in the case of an accident victim who is brought in by a friend and the friend is asked to hold the patient for radiographing). When radiographing a cadaver for an autopsy, a shield is, of course, not necessary.

e. **The Three-Point Check.** The last procedure in patient positioning is the three-point check, a final verification of the source-to-image receptor distance (SID), the cone field (CF), if applicable, and the letter (LM).

(1) The source-to-image receptor distance (SID). Make sure that you did, in fact, select the right SID. Double check the setting: 40 inches or 72 inches as appropriate to the examination that you are doing.

(2) The cone field (CF). Did you actually cone down to the size film or cone field being used for the exam?

(3) The letter marker (LM). Did you, in fact, place the correct letter marker on the film?

#### **THE THREE POINT CHECK**

A reverification of the:

1. SID.
2. Conefield.
3. Letter marker.

## 2-10. ORDER OF PROCEDURE, STEP FIVE: TAKING THE EXPOSURE

a. **Final Steps.** You are nearly ready to take the exposure. But before you actually make the exposure, there are two more things left to do: (1) verify the factors, and (2) instruct the patient,

b. **Verifying the Technique Factors.** Go back to the machine. Verify that you have set the technical factors correctly in terms of amount and duration of exposure (mAs) and strength of radiation (kVp). Check, too, that you set the factors according to the technique chain for that exam. (The technique chart should be posted in the exposure room.) You will need to check technique chart factors for both the body part being radiographed and the measurement of that part.

c. **Instructing the Patient.** Instructing the patient carefully can spare the patient from unnecessary additional radiation exposure, save you film, and save time lost in repeating the procedure or examination. If the examination requires preparation, such as a gastrointestinal (GI) or kidney exam, explain the procedures carefully to the patient. While the procedure may be like second nature to you, the procedure is still new to the patient. The best results are obtained if the patient not only understands what he is to do, but why. If the patient understands the reasons behind the procedure, he is more likely to follow your instructions. Some procedures do not require much prior explanation, but you will have to provide verbal prompts before and during the procedure. You may be saying to the patient, "Take in a deep breath and hold still," or "Drink, drink, drink," during an esophagram.

d. **Making the Exposure.** You can now take the X-ray. There may be some post-instructions, such as "relax," "breathe," or "hold still," depending on whether or not there is another exposure that follows.

### ORDER OF PROCEDURE, STEP 5: TAKING THE EXPOSURE

Verify technique factors (mAs and kVp).

Instruct the patient, as needed. (Explanation, verbal prompts.)

Make the exposure.

Give post-instructions, if applicable.

[Continue with Exercises](#)

## EXERCISE, LESSON 2, SECTION II

**MULTIPLE-CHOICE, For exercises 1 through 3,** select the ONE word or phrase that BEST completes the statement or BEST answers the question.

When you have completed all of the exercises to your satisfaction, turn to the solutions that immediately follow the exercises and check your answers.

1. Which of the following is NOT a table factor?
  - a. The film run down/letter marker.
  - b. The central ray angle.
  - c. The source-to-image receptor distance.
  - d. The cone field.
  - e. Part position.
  
2. Verifying the \_\_\_\_\_ is NOT a part of the three-point check.
  - a. Central ray (CR) angle.
  - b. Source-to-image receptor distance (SID).
  - c. The cone field.
  - d. Lettermarker (LM).
  
3. Which of the following is NOT a step in positioning the patient?
  - a. Patient position.
  - b. The part position.
  - c. Immobilization and shielding.
  - d. Verify the milliamperere seconds (mAs) and the kilovoltage peak (kvp).

**SEQUENCING.** For exercises 4 and 5 indicate the correct sequence of the steps by writing the appropriate number in the space provided. When you have completed all of the exercises to your satisfaction, turn to the solutions that immediately follow and check your answers.

4. What is the correct order of procedure for the steps involved in preparing to take a radiograph?
  - a. Take the exposure is step \_\_\_\_\_
  - b. Position the patient is step \_\_\_\_\_.
  - c. Prepare the patient is step \_\_\_\_\_.
  - d. Set the table factors is step \_\_\_\_\_.
  - e. Make the control panel adjustments is step \_\_\_\_\_.
  
5. What is the correct sequence for the final step of the order of procedure?
  - a. Making the exposure is done \_\_\_\_\_.
  - b. Verifying technique factors (mAs kVp) by checking the control panel and the technique chart is done \_\_\_\_\_.
  - c. Instructing the patient on what to do, how to breathe, when to drink, etc., is done \_\_\_\_\_.
  - d. Giving post-instructions, if applicable, is done \_\_\_\_\_.

**Check Your Answers on Next Page**

## SOLUTIONS, LESSON 2, SECTION 1

Be sure to re-read and study the paragraph(s) pertaining to any exercises you might have answered incorrectly. The relevant paragraph(s) is (are) listed after each of the answers below.

1. e (paras 2-8, 2-9b)
2. a (para 2-9e, chart)
3. d (para 2-9)
4. a= 5  
b=4  
c=1  
d=3  
e=2 (para 2-8a, chart)
5. a=third  
b=first  
c=second  
d=fourth (para 2-10d, chart)

**End of Lesson 2**



## LESSON ASSIGNMENT

### LESSON 3

Positioning Terminology.

### LESSON ASSIGNMENT

Paragraphs 3-1 through 3-23.

### LESSON OBJECTIVES

After completing this lesson, you should be able to:

- 3-1. Identify body part terminology.
- 3-2. Identify definitions of the anteroposterior (AP), posteroanterior (PA), lateral, and oblique views.
- 3-3. Identify position names based the point of entry of the central ray (CR).
- 3-4. Identify definitions of the supine, prone recumbent, lateral, and decubitus positions.
- 3-5. Identify definitions of suspended breathing, suspended inspiration, suspended expiration, and normal breathing.

### SUGGESTION

After reading and studying the assignment, complete the exercises at the end of this lesson. These exercises will help you to achieve the lesson objectives.

## LESSON 3

### POSITIONING TERMINOLOGY

#### Section I. GENERAL TERMS AND BODY PART TERMS

##### 3-1. INTRODUCTION

a. **The Importance of Terms.** In order to function effectively as a radiologic technologist, you must have a working knowledge of the terms commonly used in performing radiographic examinations. If your knowledge of these terms is inaccurate or incomplete, you may well end up positioning the patient for the wrong view. You might conceivably perform an incomplete examination or produce a blurry image. Thus, you would fail to provide the radiologist with the radiographic information needed to make a prompt and accurate diagnosis. You would also run the risk of exposing the patient to unnecessary repeat exposures. This lesson is intended to present the terms that you will need to know and use in positioning your patient for radiographs. Where possible, the terms are used in context and an illustration is provided to help you master the material and provide greater clarity.

b. **Where Terms are Introduced.** As you may have noticed, by now, this is not the only lesson in which new terms have been introduced. Other terms have been presented, in context, where they are logically needed to present a concept. Learning to use the terms in context is, in fact, a better way to learn new terms than by simply memorizing definitions in isolation. The terms covered in this lesson are a catch-all for remaining terms that have not cropped up in the two previous lessons. As for the previous lessons, new terms and their definitions are separated out of the text visually (boxed) for ease of reference. In addition, all the new terms in the subcourse are compiled in a glossary presented in the Appendix to facilitate subsequent review and mastery.

##### 3-2. THE TERMS, X-RAY FILM AND RADIOGRAPH

a. **X-ray Film.** The terms "X-ray film" and "radiograph" are quite often used interchangeably. But, in fact, they have distinct and separate meanings. The X-ray film refers more specifically to the physical piece of material on which the radiograph is taken.

**X-ray film:** emulsion composed of silver bromide crystals suspended in a gelatin substance and spread evenly upon a transparent, blue-tinted, polyester support base.

b. **Radiograph.** The radiograph, on the other hand, refers to the X-ray film once it has an image on it. In other words, the end result used by the radiologist for diagnosis of the patient's condition.

**Radiograph:** an X-ray film containing an image of an anatomical structure.

### 3-3. RADIOGRAPHIC EXAMINATION

A radiographic examination involves everything you do so as to produce the desired end-product--a diagnostic radiograph. This includes positioning the anatomical structure, making the exposure, having the film processed, etc.

**radiographic exam:** encompasses positioning the body part, exposing the film, and processing the film.

### 3-4. ANATOMIC POSITION

The anatomic position is a well established point of reference for describing the relationship of one body part to another. In the anatomic position, the patient is upright, facing straight ahead, body erect, feet together, arms at sides, and palms turned forward (figure 3-1). No matter what the actual position of the patient, such as figure 3-2, one must think in terms of the person standing erect in the anatomic position even when describing parts of a patient who is lying down. If you fail to think in terms of the anatomic position, you may incorrectly describe or label a radiograph. Consider figure 3-3, a posteroanterior (PA) chest in which both lungs are demonstrated. Because it is a PA projection, the right side is on the right side of the film. Thinking in terms of the anatomical position will orient you correctly. In an AP position, the right lung would be demonstrated on the left side of the film (figure 3-4). Thinking in terms of the anatomic position is especially important for properly placing the patient for positions involving the extremities, such as the foot or hand. Suppose you want to take a lateral view of the foot (figure 3-5). To do this, you must first determine which side to place closest to the film. For a lateral foot, the side to be placed closest to the film would correspond with the fifth digit of the foot, not the big toe.



Figure 3-1. The anatomic position, the point of reference for labeling all radiographs.

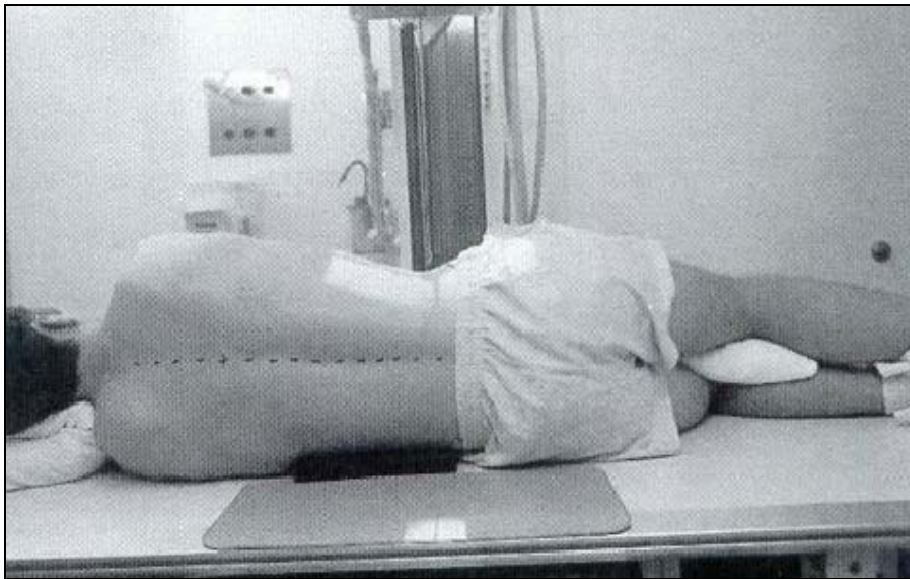


Figure 3-2. The patient is positioned for a radiographic examination of the spine (lateral lumbar spine).

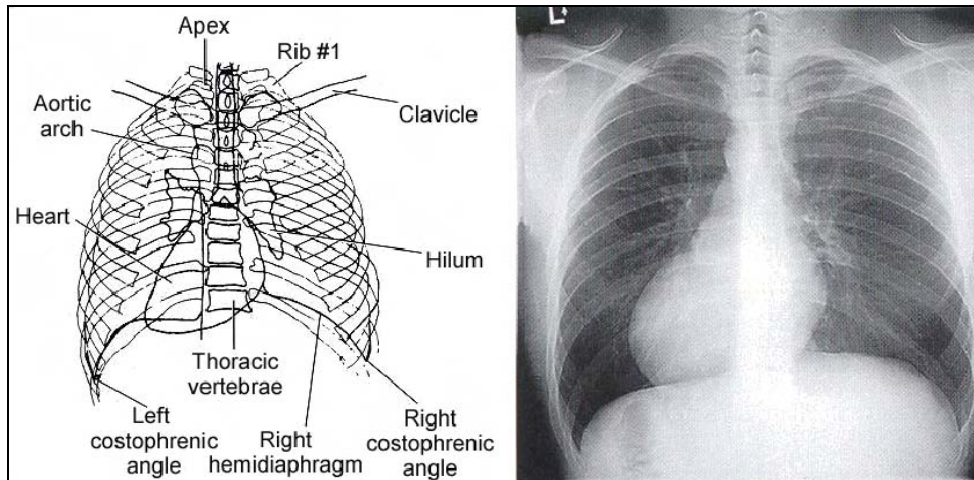


Figure 3-3. The right lung is on the right side as you face the film,

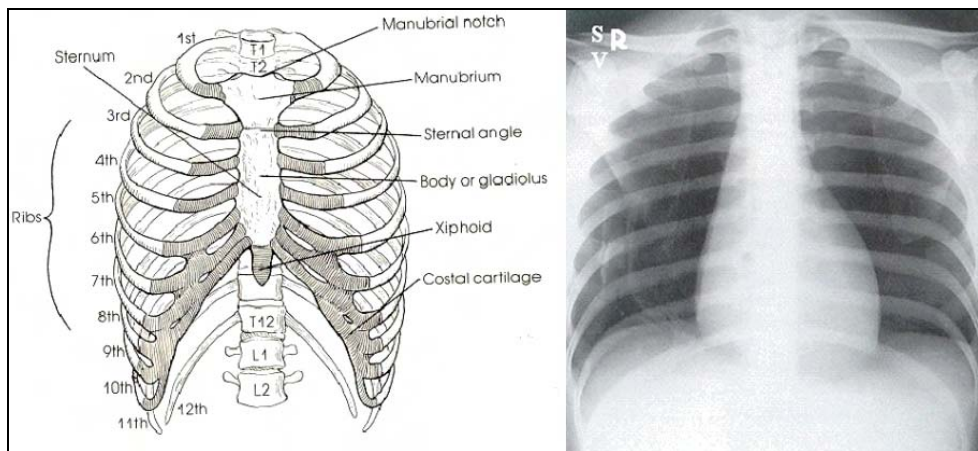


Figure 3-4. AP Rib : The right lung is on the left side as you face the film,

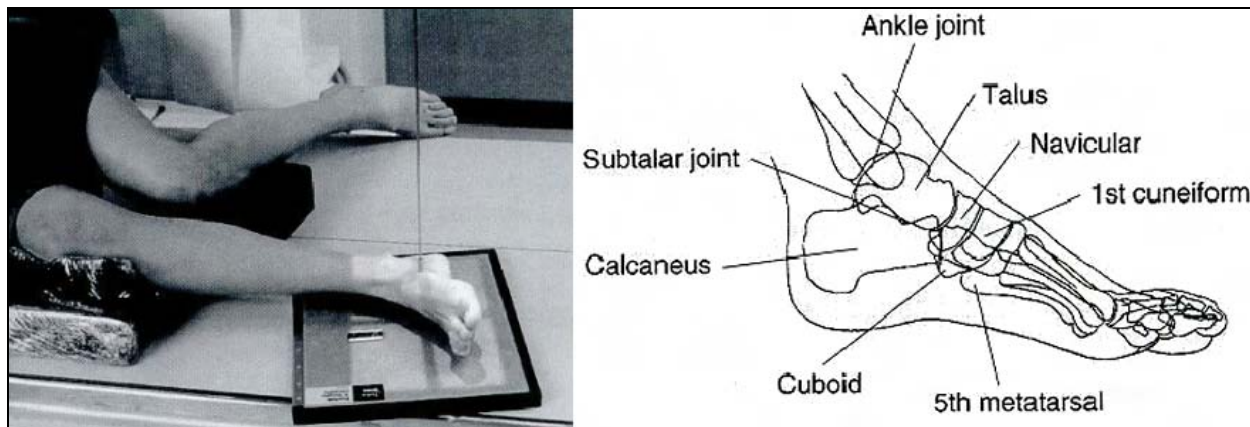


Figure 3-5. For a lateral foot, the fifth digit of the foot, not the big toe, should be closest to the film.

### 3-5. BODY PART TERMINOLOGY

a. **Anterior (Ventral).** Body part terms are used when describing the location of one anatomical structure (body part) in relation to another. Anterior or ventral refers to the front or forward half of the body or organ (figure 3-6). (It might be helpful to note that the prefix "antero-" is Latin for "front" and the prefix "venti-" is Latin for "abdomen.") For example, the anterior lingual gland refers to a certain category of gland located near the tip of the tongue.

**anterior (ventral):** referring to the front part of the body or organ.

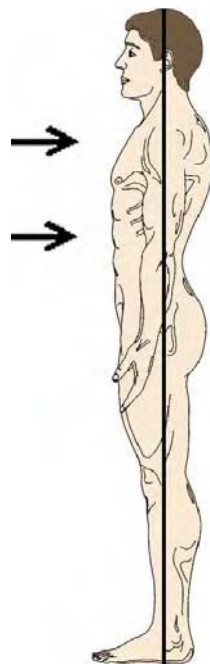


Figure 3-6. The anterior plane of the body.

b. **Posterior (Dorsal).** Posterior or dorsal refers to the back part of the body or the back part of an organ (figure 3-7). The terms, posterior or dorsal, are also used when referring to the back part of the foot or hand, as in the dorsoplantar foot. (It might help to take note that the term "posterius" is Latin for "coming after" and the term "dorsum" is Latin for "back.") A dorsoplantar foot is a view of the back part of the foot.

**posterior (dorsal):** referring to the back part of the body or organ.

NOTE: Figure 3-8 shows AP (anterior to posterior) and PA (posterior to anterior) projections.

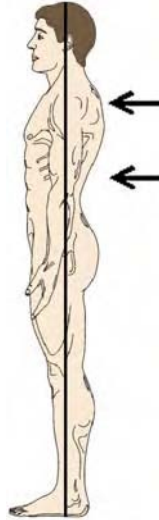


Figure 3-7. The posterior plane of the body.

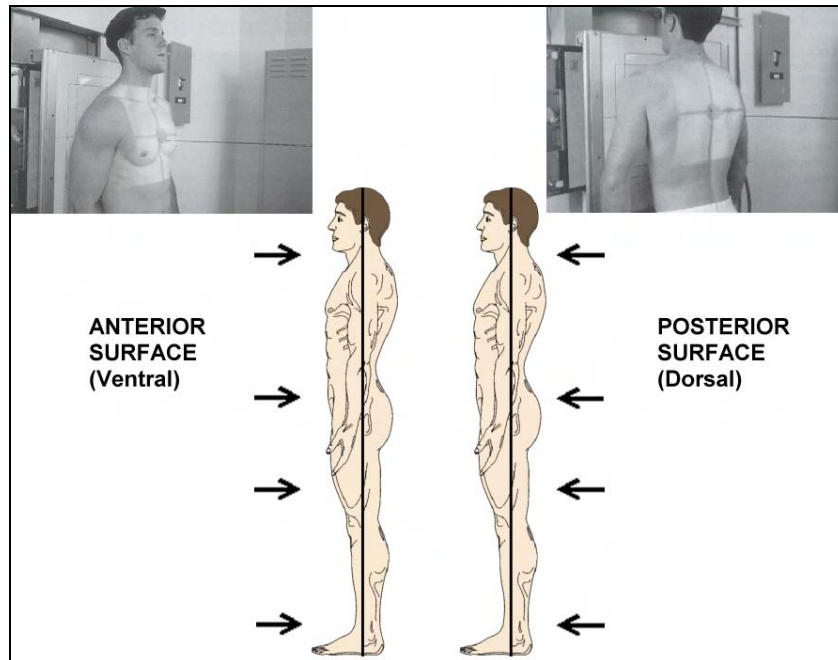


Figure 3-8. In AP projections, such as the AP chest, the central ray enters the anterior surface and exits the posterior surface. In PA projections, such as the PA chest, the opposite is true.

c. **Caudad, Caudal, or Inferior.** The terms caudad, caudal, or inferior refer to parts away from the head of the body (toward the feet). If the central ray is angled and caudad, it is angled away from the head and toward the feet (figure 3-9). ("Cauda" is Latin for "tail.") Caudal or caudad is the same as inferior or away from the head (figure 3-10).

**caudal, caudad, inferior:** parts away from the head of the body.

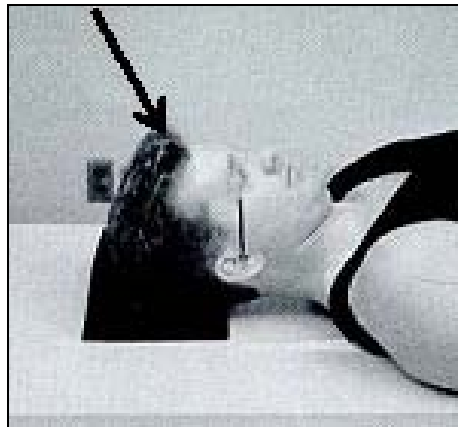


Figure 3-9. An angled central ray (caudad) is angled towards the feet.

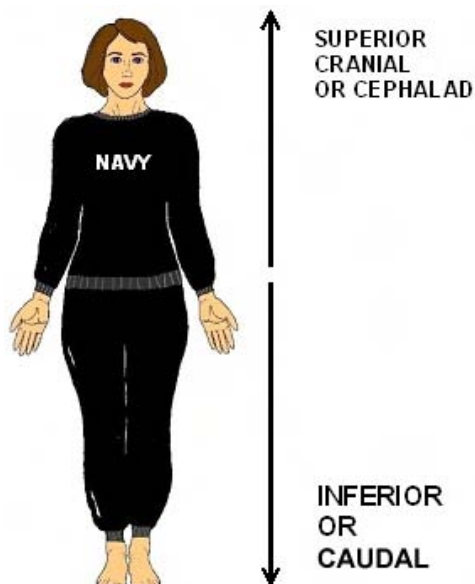


Figure 3-10. The leg is inferior (caudad) to the chest. The chest is inferior (caudal) to the skull.



d. **Cranial, Cephalic, or Superior.** The terms "cranial", "cephalic", and "superior" refer to parts that are toward the head end of the body. ("Kranion" is the Greek word for skull and "kephalo-" is the Greek prefix for head.) If the central ray (CR) is cephalic, toward which end of the body is it angled? You were right if you said that the ray would be angled toward the head (figure 3-11). Let's review some of the alternate terms for caudal and cephalic (toward the head)--the terms inferior and superior. Take a look at the inferior-superior os calcis projection shown in figure 3-12.

**cranial, cephalic, or superior:** refers to parts that are towards the head of the body.

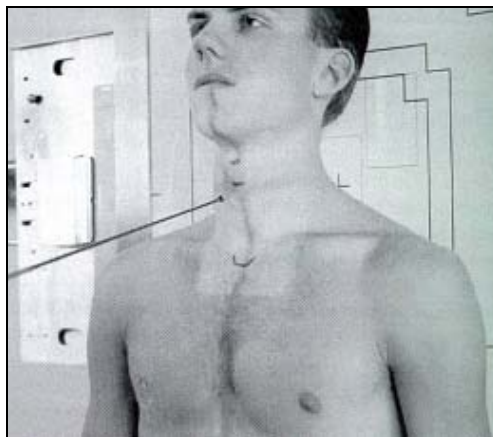


Figure 3-11. If the central ray is cephalic, it is angled toward the head.

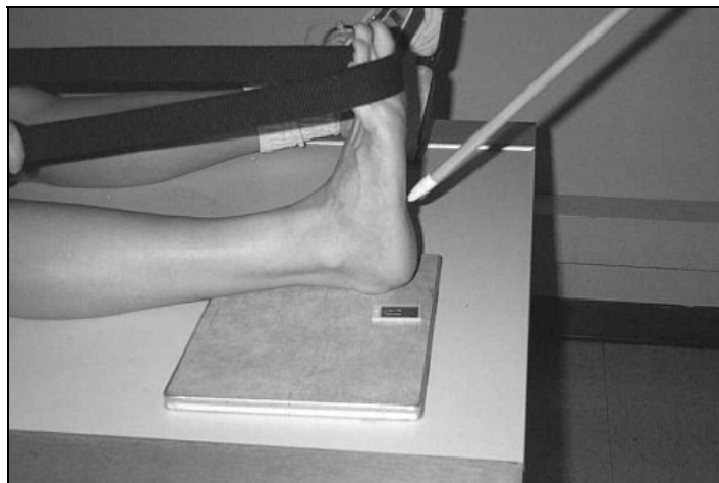


Figure 3-12. In an inferior-superior os calcis projection, the central ray enters from the inferior portion and exits the superior portion of the foot.

e. **Central.** The term "central" is used to describe the mid-area or main part of an organ.

**central:** the mid-area or main part of an organ.

f. **Distal.** The term "distal" refers to those parts that are farthest from the center, midline, or trunk. (In this sense, it is used as a directional term.) Distal can also be used as a relational term to mean far from the source or beginning (figure 3-13). Consider a patient as positioned in figure 3-13 (the lateral femur, distal and proximal).

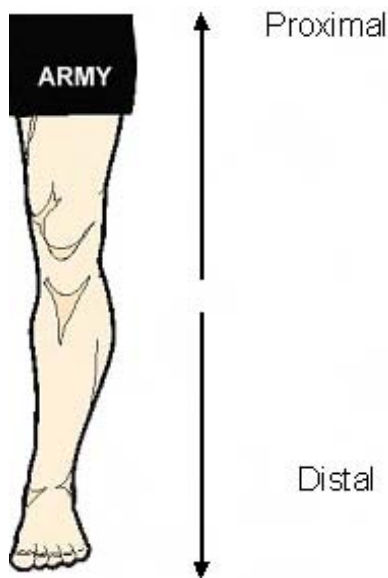


Figure 3-13. The foot is distal to the hip, that is, far from the midline or trunk.

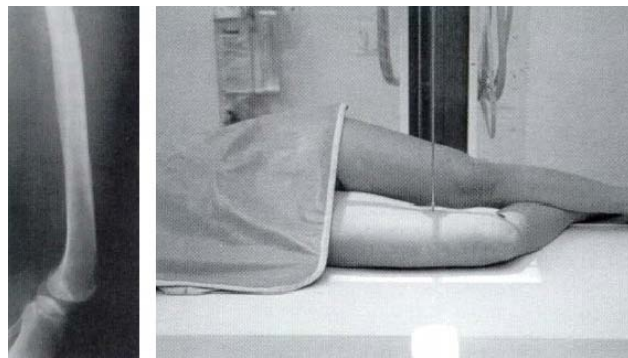


Figure 3-14. A lateral distal femur, is a side view of the part of the femur that is farthest from the point of attachment.

g. **Proximal.** The opposite of distal is proximal. The term "proximal" refers to parts closest to the center, midline or trunk. (It might help you to remember the term if you note that the word "proximh(us)" is Latin for nearest.) Proximal can also mean near the source or beginning. Consider figure 3-15 in terms of the scapula. You could say that the upper arm is proximal to the scapula. On the other hand, the metacarpals are distal to the scapula. In figure 3-16, we have a lateral proximal femur. In what sense is this projection proximal?

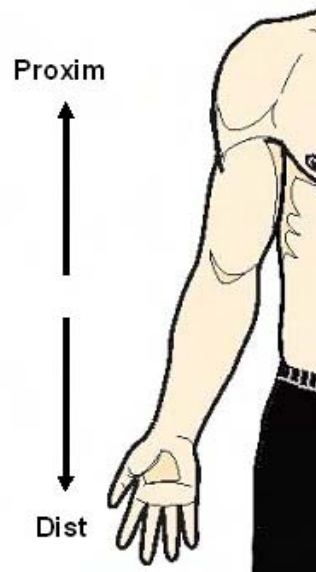


Figure 3-15. The humerus is proximal, whereas the hand is distal.

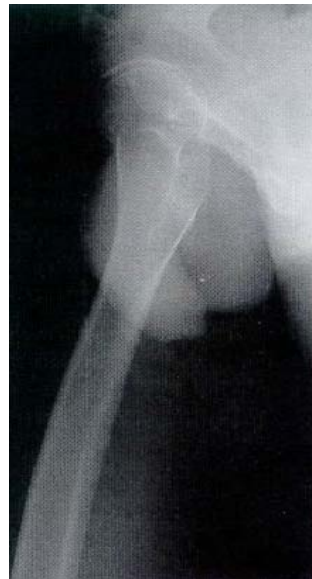

Figure 3-16. The lateral *proximal* femur is a side view of the part of the femur that is *closest* to the point of attachment.

NOTE: Figure 3-17 provided additional information on proximal and distal.

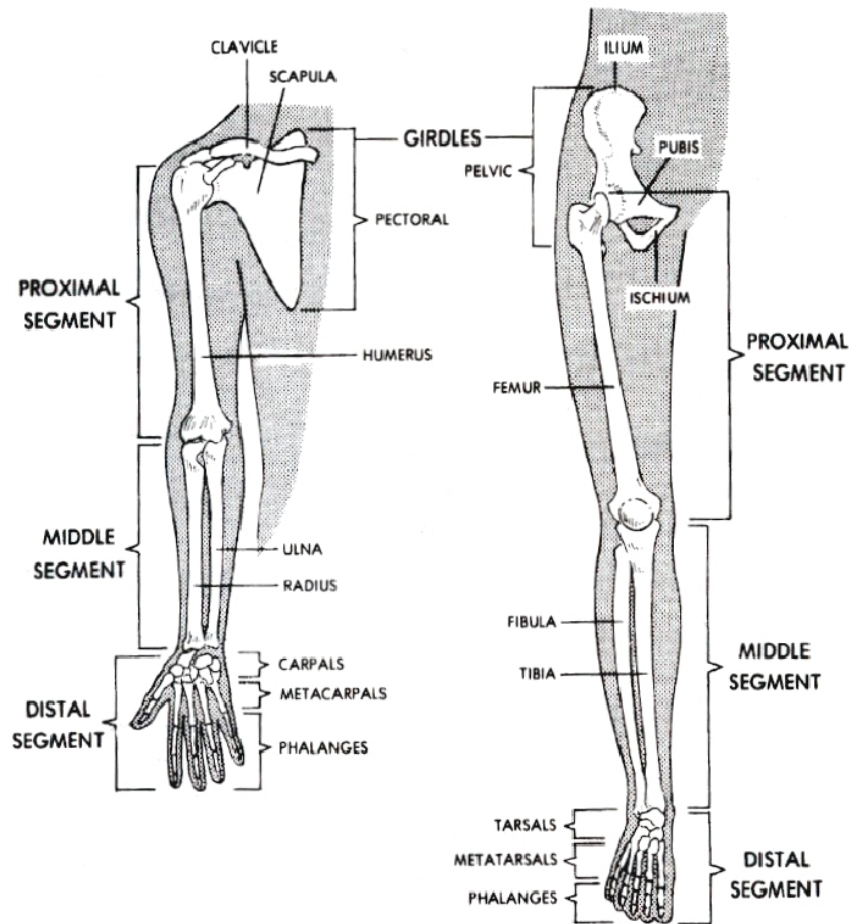


Figure 3-17. Proximal and distal segments of the arm and leg. The humerus is the proximal segment of the arm; the carpals, metacarpals, and phalanges make up the distal segment of the arm. For the leg, the femur is the proximal segment; the tarsals, metatarsals, and phalanges comprise the distal segment of the leg.

h. **Lateral.** The term lateral refers to parts away from the median plane of the body, away from the center, away from the middle of a part, or to the right or left. (The Latin "later" means "side.") A lateral view of the hand would be a side view (figure 3-18). In the anatomical position, the thumb is on the lateral aspect of the hand.

**lateral:** refers to parts away from the median plane of the body, away from the middle of a part, to the right or left.




Figure 3-18. A lateral projection of the hand.

i. **Medial or Mescal.** "Medial" is Latin for "middle." As you might expect, medial or mescal refers to parts toward the median plane of the body (figure 3-19) or toward the middle of a part (figure 3-20). Medial is the opposite of lateral.

**medial (mescal):** refers to parts toward the median plane of the body or toward the median plane of the body or toward the middle of a part.

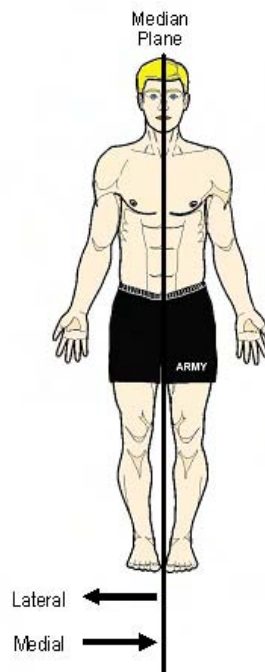


Figure 3-19. In the anatomic position the medial aspect of the ankle joint is the inside part closest to the median plane.

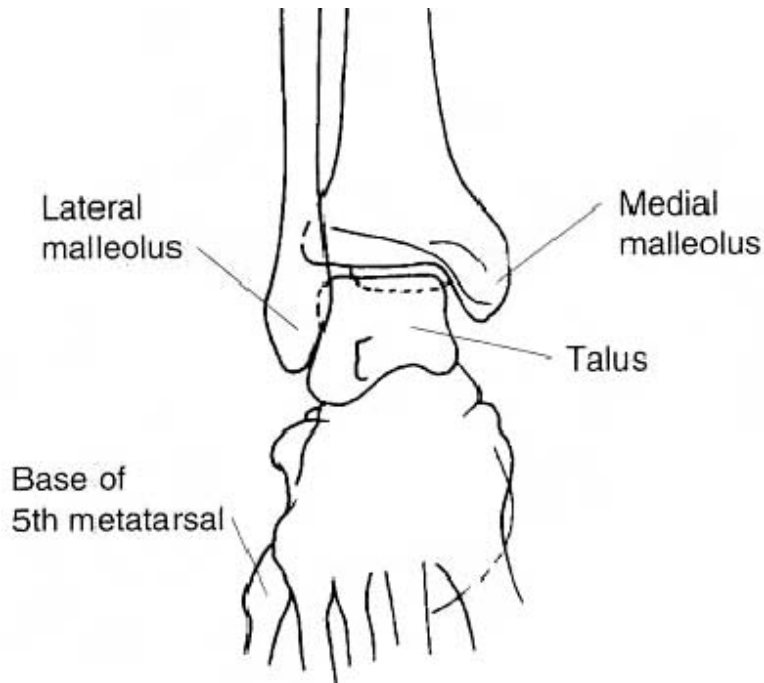


Figure 3-20. In the anatomic position, the medial aspect of the ankle joint is the inside part, closest to the median plane.

NOTE: Figures 3-21 and 3-22 give more information on lateral and medial.

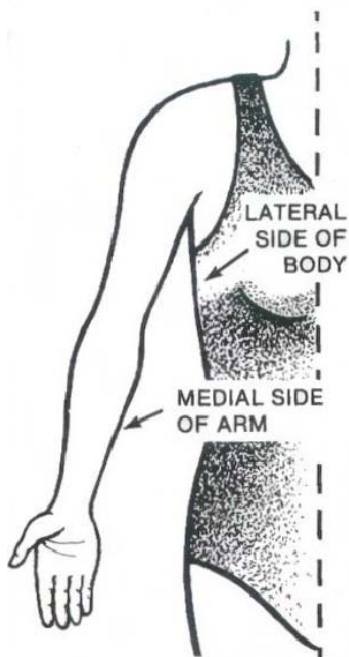


Figure 3-21. Medial and lateral sides (arm, body).

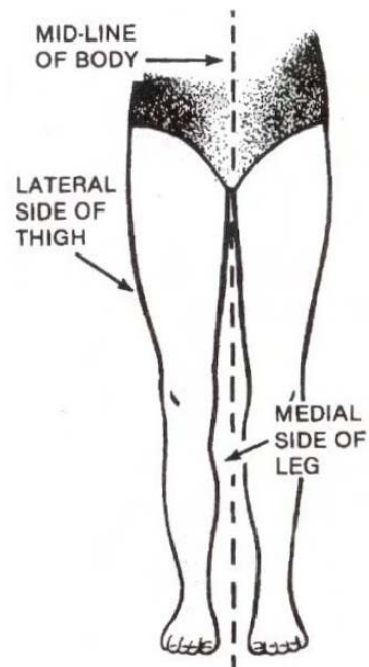


Figure 3-22. Medial and lateral sides (thigh, leg).

### 3-6. RIGHT ANGLE RADIOGRAPHIC VIEWING

a. **Anteroposterior Projections.** Right angle radiographic viewing involves obtaining a three-dimensional radiographic visualization on a two-dimensional projection. The height of the projection is obtained superior to inferior (from top to bottom). The width should be lateral to lateral or side to side.

#### AP Projections

1. Height: superior to inferior.
2. Width: lateral to lateral.

b. **Lateral Projections.** For lateral projections, the height is obtained superior to inferior. The depth of the projection is obtained anterior to posterior (from front to back).

#### Lateral Projections

1. Height: superior to inferior.
2. Depth: anterior to posterior.

c. **Oblique Projections.** For obliques, the body part is rotated off the AP or PA position. The oblique view is often requested to supplement the AP or PA and lateral projections. This additional view gives the radiologist a third dimension of the area being demonstrated. In some cases, the oblique projection may take the place of a lateral projection.

#### Oblique Projections

1. Supplement AP/laterals.
2. Takes the place of laterals.

**Continue with Exercises**

## EXERCISES, LESSON 3, SECTION I

**MATCHING.** For exercises 1 through 4, match the numbered term in the left-hand column with the lettered definition in the right-hand column. Enter the appropriate letter on the blank line. There is one extra definition that will not be selected.

- |                                   |   |
|-----------------------------------|---|
| 1. X-ray film _____               | a. Everything done to obtain an X-ray, from positioning the patient, exposing the film, to processing it.   |
| 2. Radiograph _____               | b. Point of reference for descriptions of body part relationships.  |
| 3. Radiographic examination _____ | c. Emulsion composed of silver bromide crystals suspended in a gelatin substance that is spread evenly upon a transparent, blue-tinted, polyester support base. |
| 4. Anatomic position _____        | d. The American Registry of Radiologic Technologists.   |
|                                   | e. An X-ray film containing an image of an anatomical structure.  |

**MATCHING.** For exercises 5 through 8, match the numbered term in the left-hand column with the lettered definition in the right-hand column. Enter the appropriate letter on the blank line. There is one extra definition that will not be selected.

- |                                     |   |
|-------------------------------------|---|
| 5. Anterior/ventral _____           | a. The front part of the body or organ.                     |
| 6. Posterior/dorsal. _____          | b. The back of the foot.                                    |
| 7. Dorsum of foot _____             | c. The back part of the body or organ.                      |
| 8. Caudal, caudad or inferior _____ | d. Body erect, feet together, arms at sides, palms forward. |
|                                     | e. Parts farthest from the head.                            |



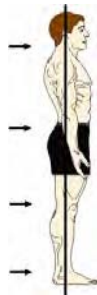**MATCHING.** For exercises 9 through 14, match the numbered term in the left-hand column with the lettered definition in the right-hand column. Enter the appropriate letter on the blank line. There is one extra definition that will not be selected.

- |   |   |
|---|---|
| 9. Cranial, cephalic _____<br>or superior | a. Nearest the center, midline, or trunk.                           |
| 10. Proximal _____                        | b. Toward the head.   |
| 11. Lateral _____                         | c. Mid-area or main part of an organ.                               |
| 12. Medial/mesial _____                   | d. Away from the head.  |
| 13. Distal _____                          | e. Away from the median plane or middle part: to the right or left. |
| 14. Central _____                         | f. Toward the median plane; toward the middle of a part.            |
|   | g. Farthest from the center, midline, or trunk.                     |

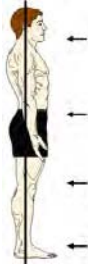
**IDENTIFICATION,** For exercises 15 through 29, correctly label the figures above the question by entering the appropriate word(s) in the space provided.



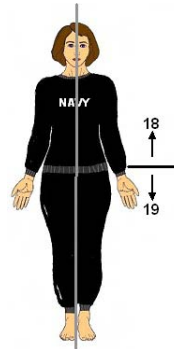
15. This is known as the \_\_\_\_\_ position.



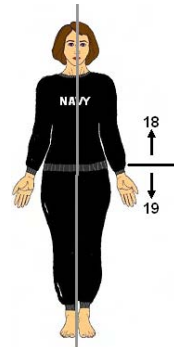
16. This is known as the \_\_\_\_\_ or \_\_\_\_\_ surface.



17. This is known as the \_\_\_\_\_ or \_\_\_\_\_ surface.



18. Parts in the direction indicated by arrow (number 18) are \_\_\_\_\_,  
\_\_\_\_\_, or \_\_\_\_\_.



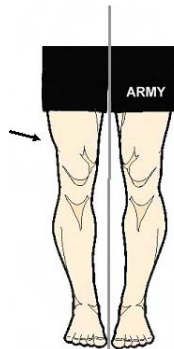
19. Parts in the direction indicated by arrow (number 19) are \_\_\_\_\_,  
\_\_\_\_\_, or \_\_\_\_\_.



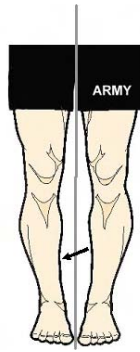
20. Parts in the direction indicated by arrow #20 are \_\_\_\_\_.



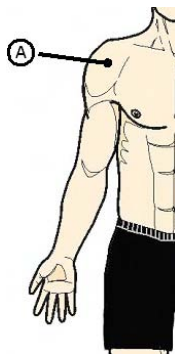
21. Parts in the direction indicated by arrow #21 are \_\_\_\_\_.



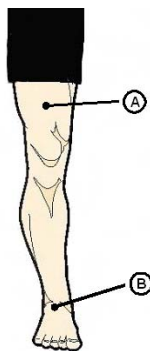
22. The arrow is pointing to the \_\_\_\_\_ side of the thigh.



23. The arrow is pointing to the \_\_\_\_\_ side of the leg.

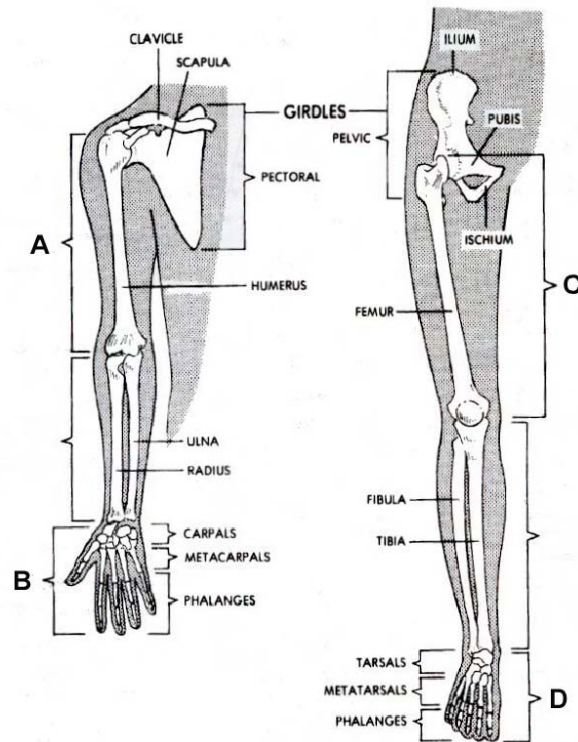


24. The shoulder (A) is \_\_\_\_\_ to the wrist.



25. The ankle (B) is \_\_\_\_\_ to the thigh (A).

**IDENTIFICATION, For exercises 26 through 29, consider the parts labeled a, b, c, or d in the figure below and enter the correct letter: in the space provided.**



- 26. Letter\_\_\_ marks the distal segment of the arm.
- 27. Letter \_\_\_ marks the proximal segment of the arm.
- 28. Letter\_\_\_ marks the distal segment of the leg.
- 29. Letter\_\_\_ marks the proximal segment of the leg

**Check Your Answers on Next Page**

## SOLUTIONS, LESSON 3, SECTION I

Be sure to re-read and study the paragraph(s) pertaining to any exercises you might have answered incorrectly. The relevant paragraph(s) is (are) listed after each of the answers below.

1. c (para 3-2a)
2. e (para 3-2b)
3. a (para 3-3)
4. b (para 3-4)
5. a (para 3-5a)
6. c (para 3-5b)
7. b (para 3-5b)
8. e (para 3-5c)
9. b (para 3-5d)
10. a (para 3-5g)
11. e (para 3-5h)
12. f (para 3-5i)
13. g (para 3-5f)
14. c (para 3-5e)
15. Anatomic (figure 3-1, para 3-4)
16. Posterior or dorsal (figure 3-8, para 3-5b)
17. Anterior or ventral (figure 3-8, para 3-5a)
18. Superior, cranial, or cephalic (figure 3-10, para 3-5d)
19. Inferior, caudad, or caudal (figure 3-10, para 3-5c)
20. Lateral (figure 3-22)
21. Medial (figure 3-22)
22. Lateral (figure 3-22)
23. Medial (figure 3-22)
24. Proximal (figure 3-15)
25. Distal (figure 3-13)
26. B (figure 3-17)
27. A (figure 3-17)
28. D (figure 3-17)
29. C (figure 3-17)

## Section II. POSITIONING AND PROJECTION TERMINOLOGY

### 3-7. PROJECTION

The process of recording a body part on an image receptor (film) is referred to as projection. The projection describes the path of the central ray (CR) from the X-ray tube through the patient to the image receptor.

**projection:** process of recording a body part on an image receptor (film); path of central ray from the X-ray tube to film

### 3-8. POSTEROANTERIOR PROJECTION

Here, the terms posterior and anterior (posteroanterior (PA)) are combined to describe the protection or direction in which the X-ray beam travels. In a PA projection, the X-ray beam enters a posterior surface and exits an anterior surface (figure 3-23). As stated earlier, in a PA projection the height of the film is superior to inferior and the width is lateral to lateral.

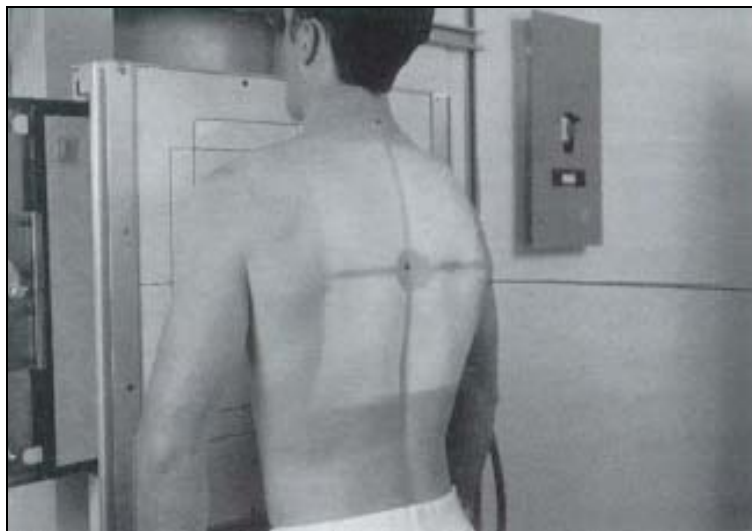

Figure 3-23. In this PA projection of the chest, the CR enters a posterior surface and exits an anterior surface.

### 3-9. ANTEROPOSTERIOR PROJECTION

The two terms, anterior and posterior are combined here to describe the direction of travel of the X-ray beam entering an anterior surface and exiting a posterior surface (figure 3-24).

**anteroposterior projection:** a projection of the X-ray beam human anterior surface to a posterior surface.

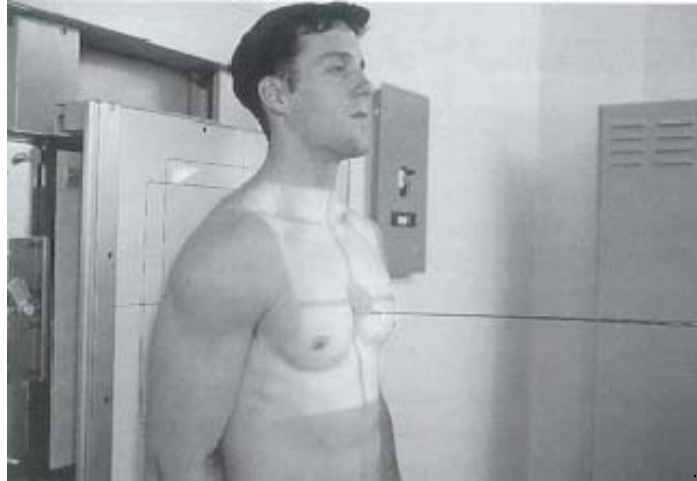


Figure 3-24. Anteroposterior chest projection with central ray entering anterior surface and traveling to posterior surface

### 3-10. VIEW

The view is the opposite of the projection and can be described as the way the image is seen from the vantage point of the image receptor. It is what is seen when the radiograph is viewed from the viewbox (figure 3-25). The term PA projection describes how the CR travels from the X-ray tube through the posterior aspect to the anterior aspect to the film. The term AP view describes how the side closest to the film, that is, the posterior surface, is demonstrated (figure 3-26).



Figure 3-25. The radiologist, looking over X-rays at a viewbox.



**view:** the image as seen from the vantage of the image receptor, the way the film “sees” the part.

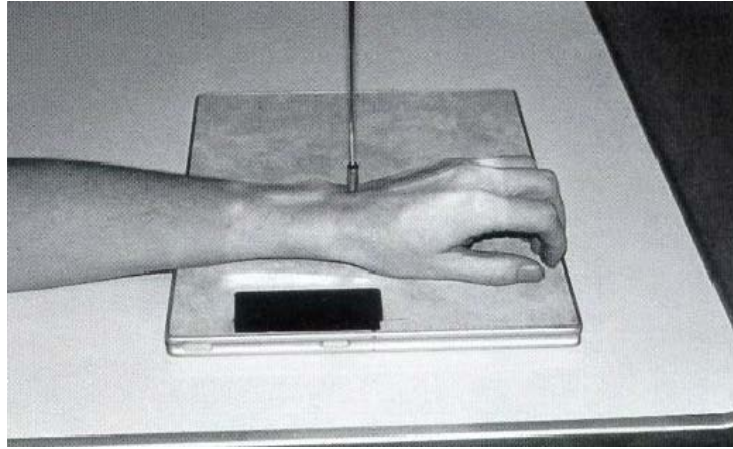


Figure 3-26. So positioned, a PA protection of the wrist will be produced, since the CR enters the superior surface and the inferior surface is closest to the film.

### 3-11. ROUTINE

When a radiologist seeks radiologic information about a particular anatomical structure or area, he will generally request a routine, that is, a battery of lightly different projections of the same body part. By ordering a routine, the radiologist will have not one, but a series of views of the same anatomical structure to look at and evaluate (figure 3-27).

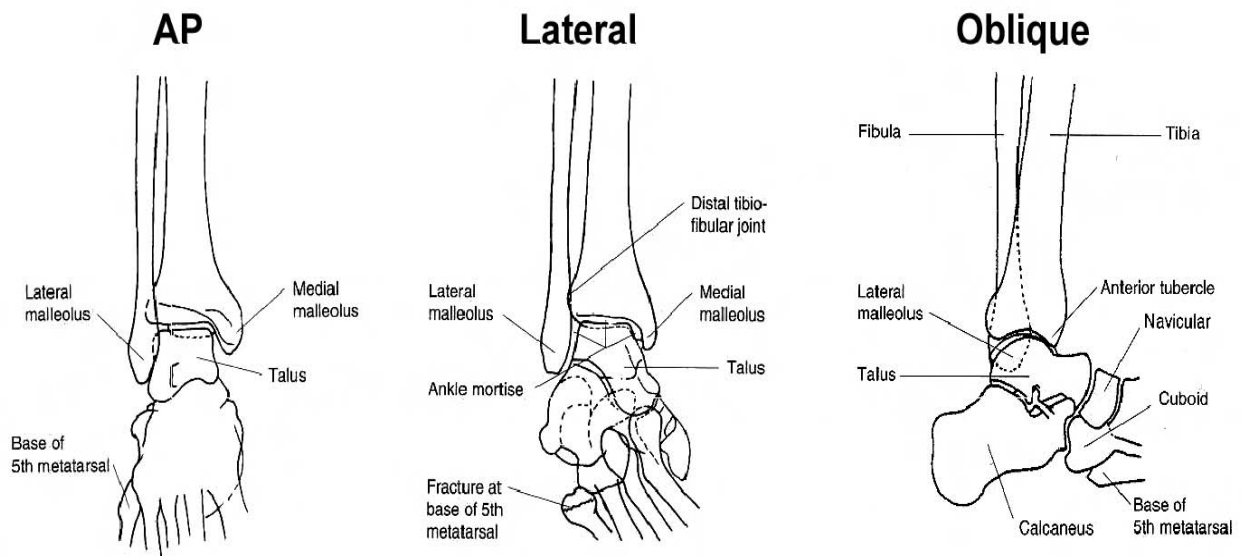


Figure 3-27. A routine generally consists of an AP, oblique, and lateral.

**routine:** a series of related projections of an anatomical structure required for right angle viewing or a general survey of the anatomical part to be demonstrated.

### 3-12. METHOD

a. **Methodology Named After Individual.** The method is the procedure for positioning the patient, the film, and the CR. In some cases, individuals who have developed a method for demonstrating a specific anatomic part are recognized by having the method named after them. For example, a PA projection of the cranium uses the Caldwell method for demonstrating the frontal ethmoid sinuses (figure 3-28).

**method:** a procedure for positioning the body in reference to anatomic landmarks, film position, and central ray to body position.

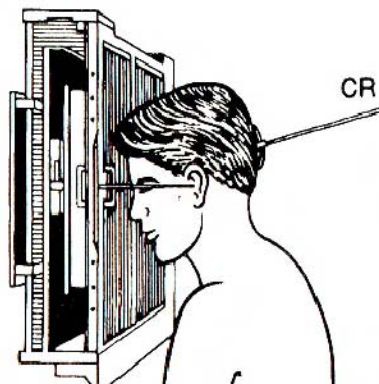


Figure 3-28. Posteroanterior projection of the cranium using the Caldwell method for demonstrating the frontal and ethmoid sinuses.

b. **The Author or Originator May Name the Position.** In some cases, the author or originator of the method for positioning the patient, film, and CR also names the position that the patient assumes. Thus, for the Chassard-Lapine method, the patient assumes the Chassard-Lapine position in which the patient sits well back on the side of the table with thighs abducted (moved away from the central axis) as shown in figure 3-29. In the case of the Caldwell method, however, the author's name has not come to stand for the body position that the patient assumes. You will learn which body positions are named for the author of the method as you start to use these positions in your day-to-day work.

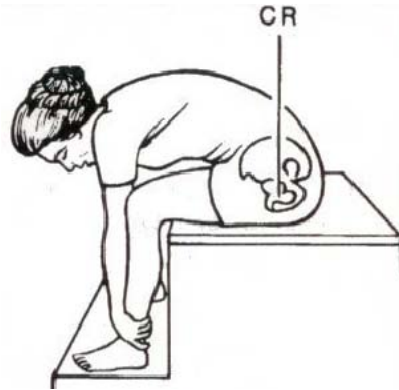


Figure 3-29. Posteroanterior anal projection of the rectum using the Chassard-Lapine method.

### 3-13. SPECIFIC BODY FUNCTIONS

a. **Relation to Surrounding Space.** The manner of placement of the patient in relation to the surrounding space is one way of defining a body position (for example, prone and supine positions).

b. **Anatomical Surface Nearest the Film.** A body position may also be named according to the anatomical surface (body part) closest to the film. For example, in the left lateral position, the patient's left side is closest to the film.

c. **Author or Originator.** As stated in paragraph 3-12, sometimes the body position that the patient must assume in order to obtain a certain projection is named after the individual who developed the overall method for placing the patient, film, and central ray CR, as in the Chassard-Lapine method.

d. **Anatomical Structure Demonstrated.** In some cases, the position is named after the anatomical structure demonstrated, as in a PA clavicle.

**body position:** the way the patient is placed in relation to the surrounding space; the body described in terms of the part closest to the film, the author of the method, or the anatomical structure demonstrated.

### 3-14. LATERAL POSITION

"Latus" is Latin for "side." Thus, a lateral position is one in which the patient is on his side. If a patient is placed in the lateral position in preparation for a true lateral projection, the patient is rotated 90 degrees (1/4 turn) from a true AP or PA (figure 3-30). Thus, a true lateral is perpendicular (at right angles to) a true AP or PA. In the left lateral position, the patient's left side is against the film. In the right lateral position the patient's right side is closest to the image receptor.

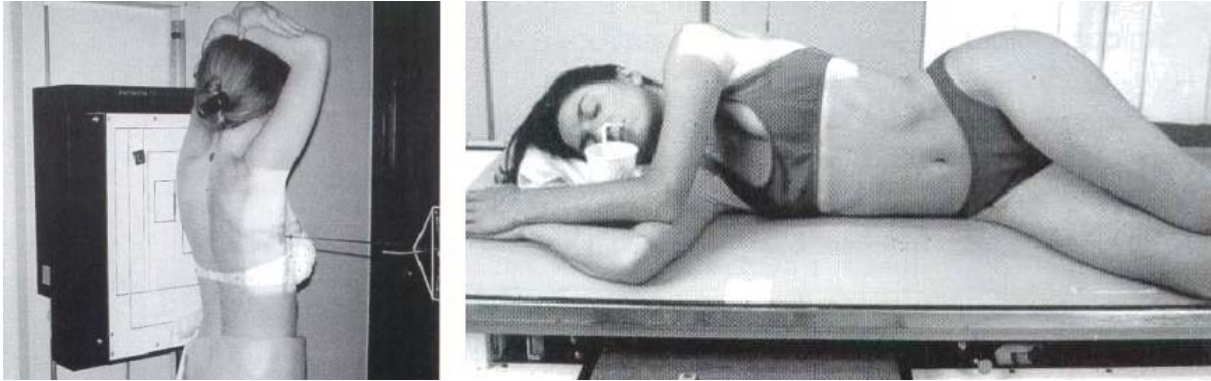


Figure 3-30. A true lateral is rotated 90 degree or 1/4 turn from a PA or AP projection.

### 3-15. OBLIQUE POSITION

In the oblique position, the frontal or coronal body plane (the plane that divides the body into anterior and posterior portions) is neither at right angles (lateral) nor parallel (PA or AP) to the film, such as demonstrated in figure 3-31. This plane is somewhere between a PA (or AP) and a lateral. The exact amount of body rotation in an oblique position will change according to the anatomical structure to be demonstrated. But, it will be somewhere between a PA (or AP) and lateral.

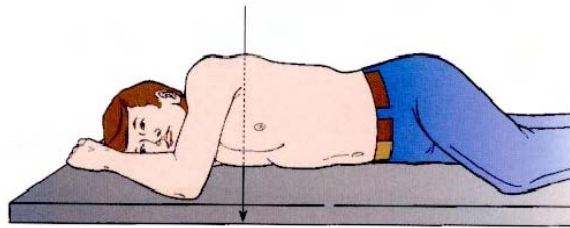


Figure 3-31. In the oblique position the frontal or coronal plane is somewhere between a PA (or AP) and a lateral.

### 3-16. DECUBITUS POSITION

The term "decubitus" is derived from the Latin verb "decumbere," which means to lie down. Decubitus terminology indicates the position of the patient during the examination. Decubitus is a general term meaning the act of lying down and the position that the patient assumes in lying down. There are a number of decubitus (lying down) positions. These are defined according to the way in which the body part/surface comes in contact with the bed or other surface. Before specifying the various decubitus positions the related term "recumbent" needs to be defined (paragraph 3-17).

**decubitus position:** the patient in a lying down position.

### 3-17. RECUMBENT POSITIONS

The term "recumbent" comes from the Latin words "re" (to lie back) and "cubere" (to lie down). Recumbent is another term often used to describe the decubitus positions. Recumbent means lying down or reclining. It is often used interchangeably with the term decubitus.

**recumbent:** lying down or reclining.

### 3-18. DORSAL RECUMBENT, DORSAL DECUBITUS, OR SUPINE POSITION

The term "dorsal" is Latin for "back." Thus, dorsal refers to being situated on the back. As you may have surmised, dorsal decubitus and dorsal recumbent mean lying in the supine position (figure 3-32).

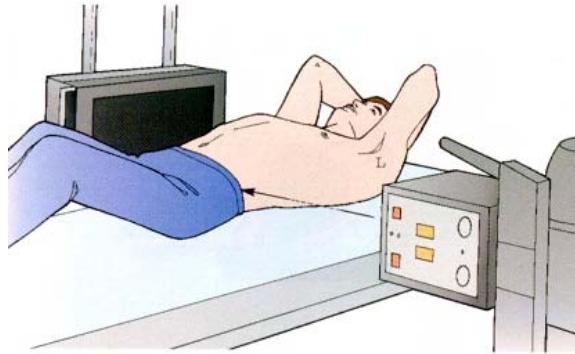


Figure 3-32. The dorsal decubitus, dorsal recumbent, or supine position. (Flexing the patient's knees provides added comfort.)

### 3-19. THE VENTRAL RECUMBENT, VENTRAL DECUBITUS, OR PRONE POSITION

The prefix "ventri-" is Latin for "abdomen." Thus, the ventral recumbent or ventral decubitus position is another name for the prone position. In this position, the patient is lying face down (figure 3-33). The ventral decubitus position produces a left lateral projection.

**ventral recumbent (ventral decubitus):** prone or lying face down.

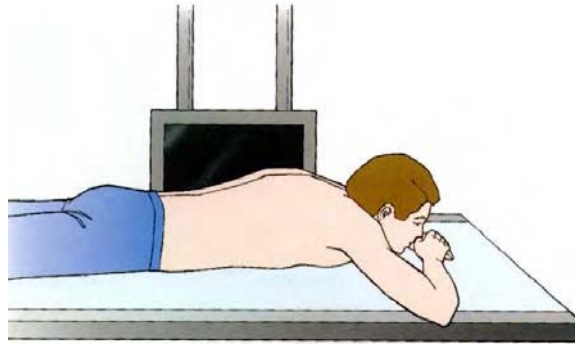


Figure 3-33. The ventral decubitus position produces a left lateral projection.

### 3-20. THE LATERAL DECUBITUS OR LATERAL RECUMBENT POSITION

The patient may be placed on his right side, in which case the position is referred to as the right lateral recumbent or right lateral decubitus position. The left lateral decubitus position shown in figure 3-34, produces an AP radiographic projection of the body part. If the patient is placed in the right lateral decubitus (recumbent) position, then the patient will be lying on his right side (see figure 3-35).

**left lateral recumbent (decubitus) position:** lying on left side.

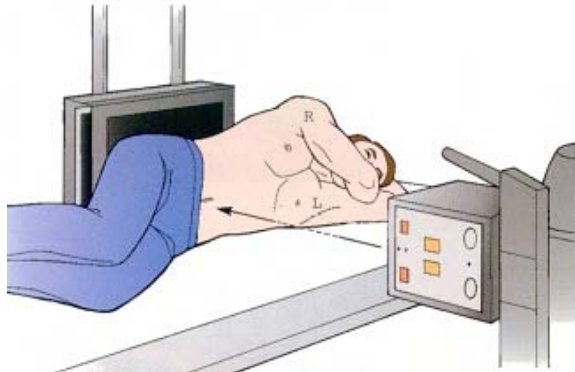


Figure 3-34. The left lateral decubitus (recumbent) position.

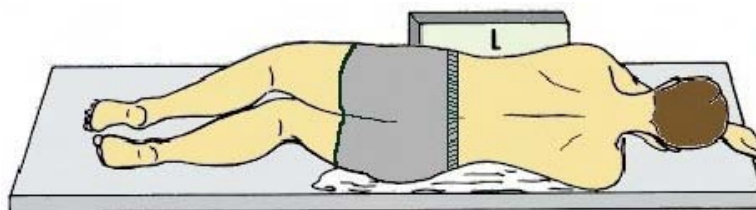


Figure 3-35. The patient shown here has assumed the right lateral decubitus position.

**Continue with Exercises**

## EXERCISES, LESSON 3, SECTION II

**MATCHING.** For exercises 1 through 5, match the numbered term in the left-hand column with the lettered definition in the right-hand column. Enter the appropriate letter on the blank line. There is one extra definition that will not be selected.

- |                             |  |
|-----------------------------|--|
| 1. Projection _____         | a. The way the patient is placed in relation to the surrounding space.   |
| 2. View _____               | b. Recumbent or lying down.  |
| 3. Routine _____            | c. Describes path of central ray from X-ray tube to film.  |
| 4. Method _____             | d. The image as seen from the vantage point of the image receptor.   |
| 5. Decubitus position _____ | e. Series of related projections needed for a general survey of an anatomical part.  |
|                             | f. Procedure for positioning the body with reference to established anatomic landmarks, film position, and central ray to body position. |

**MULTIPLE-CHOICE.** For exercises 6 through 13, select the ONE word or phrase that BEST completes the statement or BEST answers the question.

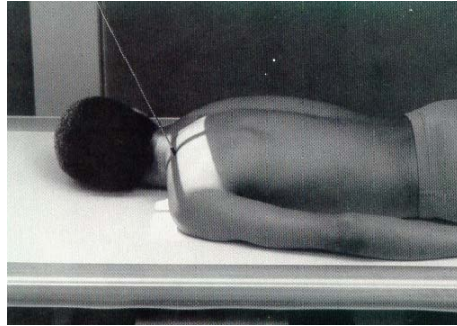
6. The term "view" should be regarded as:
- a. A positioning term.
  - b. The radiograph as seen from the viewgraph.
  - c. A verb.
  - d. The path of the central ray.

7. Routine views are:
  - a. Specifically requested by the radiologist.
  - b. Conducted at the radiographer's initiative.
  - c. Prescribed in the technique chart.
  - d. A kind of general guideline for the radiographer.
  
8. Which of the following represents correct usage of positioning and other terminology?
  - a. The Chassard-Lapine routine demonstrates a rectal projection.
  - b. Anal projection demonstrates Chassard-Lapine method.
  - c. When demonstrating the rectum for an anal projection, the Chassard-Lapine method is used.
  - d. The Chassard-Lapine projection demonstrates the anal view of the rectum.
  
9. When the radiologist looks at a PA view at the viewbox, he is seeing the \_\_\_\_\_ surface of the anatomy.
  - a. Anterior.
  - b. Lateral.
  - c. Oblique.
  - d. Posterior.
  
10. Which of the following describes characteristic(s) of a PA projection?
  - a. The height is inferior to superior and the width is lateral to lateral.
  - b. The height is superior to inferior and the width is lateral to lateral.
  - c. The height is equal to the width.




11. The body position assumed by the patient is NOT named for:
  - a. The path of the central ray.
  - b. The anatomical surface nearest the film.
  - c. The author of the overall radiographic method used to obtain the projection.
  - d. The anatomical structure demonstrated.
  
12. In a true lateral position, the body is:
  - a. Parallel to the film.
  - b. Rotated 45 degrees from a true AP or PA projection.
  - c. Perpendicular to a true AP or PA projection.
  - d. Neither at right angles nor parallel to the image receptor.
  
13. In an oblique position, the body is:
  - a. Parallel to the film.
  - b. Rotated 90 degrees from a true AP or PA projection.
  - c. Somewhere between the position required for an AP projection and a PA projection.
  - d. Neither parallel to nor at right angles to the film.

**IDENTIFICATION, For exercises 14 through 22,** correctly label the figures above the question by entering the appropriate word (or letter) in the space provided.



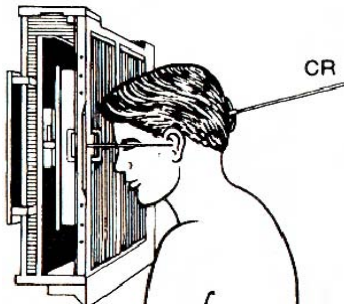
14. This is a(n) \_\_\_\_\_ of the clavicle.



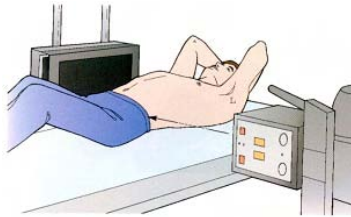
15. This is a(n) \_\_\_\_\_ of the scapula.



16. The radiologist is looking at an assortment of related \_\_\_\_\_  
on the viewgraph, which constitute a \_\_\_\_\_.

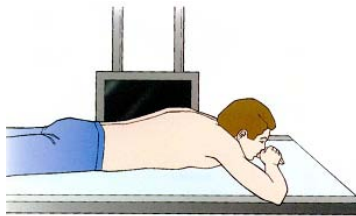


17. For a PA axial projection, the Caldwell \_\_\_\_\_ is used to demonstrate the frontal and anterior ethmoid sinuses.



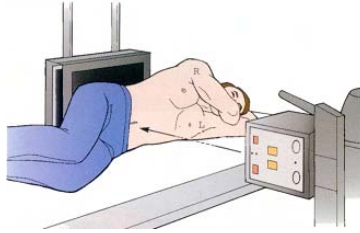
18. There are three alternative names for this position:

- (1) \_\_\_\_\_ position.
- (2) \_\_\_\_\_ position.
- (3) \_\_\_\_\_ position.



19. Three alternative names for this position are:

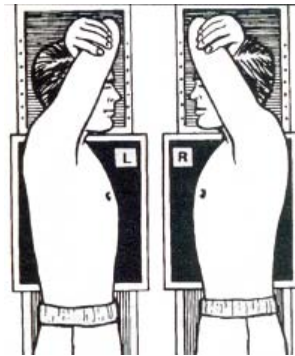- (1) \_\_\_\_\_ position.
- (2) \_\_\_\_\_ position.
- (3) \_\_\_\_\_ position.



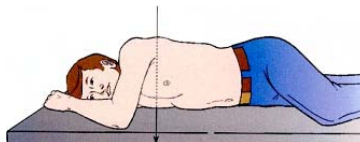
20. Two possible names for this position are:

(1) \_\_\_\_\_ position.

(2) \_\_\_\_\_ position.



21. This patient is in the \_\_\_\_\_ position.



22. This patient is in the \_\_\_\_\_ position.

**Check Your Answers on Next Page**

## SOLUTIONS, LESSON 3, SECTION II

Be sure to re-read and study the paragraph(s) pertaining to any exercises you might have answered incorrectly. The relevant paragraph(s) is (are) listed after each of the answers below.

1. c (para 3-7)
2. d (para 3-10)
3. e (para 3-11)
4. f (para 3-12)
5. b (para 3-16)
6. b (para 3-10)
7. a (para 3-11)
8. c (para 3-12)
9. a (para 3-10)
10. b (para 3-8)
11. a (para 3-13)
12. c (para 3-14)
13. d (para 3-15)
14. PA projection (para 3-8)
15. AP projection (para 3-9)
16. views, routine (paras 3-10, 3-11)
17. method (para 3-12)
18. dorsal decubitus  
dorsal recumbent  
supine (para 3-18)
19. ventral decubitus  
ventral recumbent  
prone (para 3-19)
20. left lateral decubitus  
left lateral recumbent (para 3-20)
21. lateral (para 3-14)
22. oblique (para 3-15)

## Section III. PROJECTION, CENTRAL RAY, AND BREATHING TECHNIQUE TERMINOLOGY

### 3-21. PROJECTION TERMINOLOGY

a. **Frontal Projections.** The body positions discussed earlier prepare the patient for certain projections. That is, the patient is so positioned that the central ray will travel in the desired direction. The various projections may be grouped into four major categories frontal, lateral, oblique, and decubitus projections. The frontal (front to back or back to front) projections are the anteroposterior (AP) and posteroanterior (PA) projections. (The term frontal is used to denote AP or PA projections because the frontal (or coronal) plane divides the body into anterior and posterior portions.)

**frontal or coronal plane.** the plane dividing the body into anterior and posterior portions.

**frontal projection:** an AP or PA projection.

(1) Anteroposterior projection. In the AP projection (figures 3-36 and 3-37), the central ray enters the front (anterior) body surface and exits the back (posterior) surface.

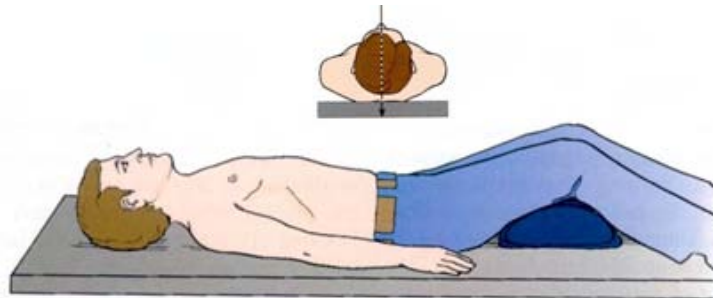


Figure 3-36. The dorsal recumbent position allows the central ray to travel in an anterior to posterior surface, producing an AP projection.

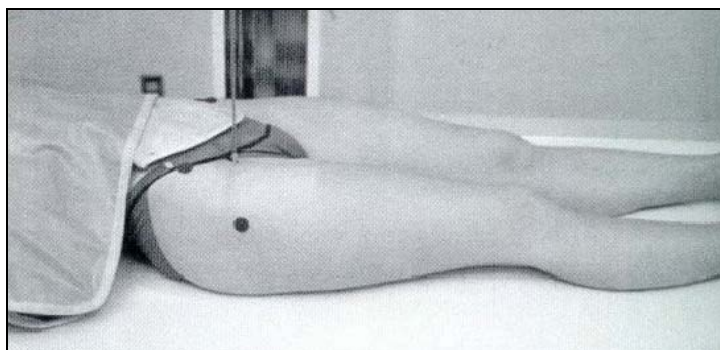


Figure 3-37. The patient on her back for an AP hip.

(2) Posteroanterior projection. In the upright position shown in figure 3-38, the X-ray beam enters from the posterior body surface. Thus, this position prepares the patient for a PA (posteroanterior) projection.

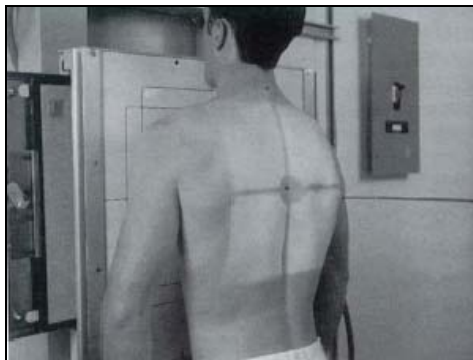

Figure 3-38. In this upright position, a PA projection is produced.

b. **Lateral Projections.** Lateral projections are named for the side of the patient closest to the film. (Thus, body position and projection names are identical.) In a left lateral position (figure 3-39), the CR travels to the left lateral surface, thus producing a left lateral projection. If the patient is placed in the right lateral position with the right side of the body closest to the film (figure 3-40), he will be prepared for a right lateral projection.

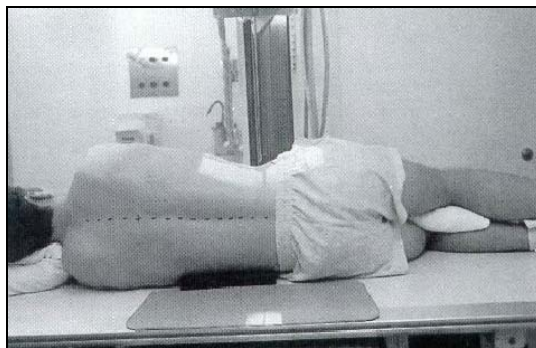


Figure 3-39. A left lateral position produces a left lateral projection.

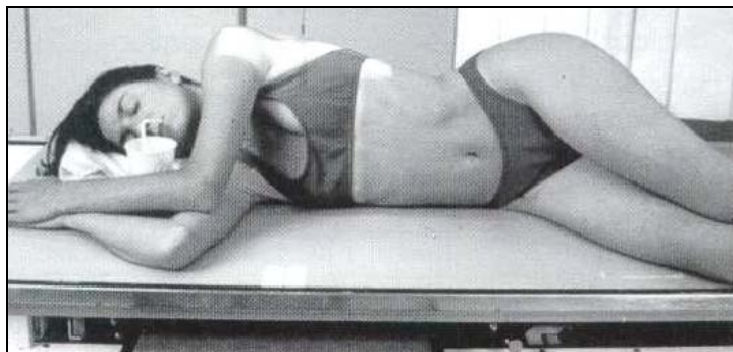


Figure 3-40. A right lateral position, results in a right lateral projection.

### c. Oblique Projections.

(1) Positioning the patient. To obtain an oblique projection, the patient must be positioned in an oblique body position. As you recall, in an oblique position the body part is rotated so that neither a frontal (AP or PA) nor a lateral projection is produced.

(2) Use of oblique projections. As stated earlier, oblique projections supplement AP and lateral views.

(3) Naming oblique projections. Oblique projections are named for the side (right or left) and the body surface (anterior or posterior) closest to the film. There are three alternative names for the position shown in figure 3-41. The patient's right side is closest to the film and that the central ray is traveling from a posterior to anterior surface. Thus, this can be termed a left posterior to right anterior projection with the patient in the oblique body position. It can also be termed a right posteroanterior (PA) oblique projection. But most commonly, it is referred to as a right anterior oblique (RAO) projection. Right anterior oblique is the term used by most radiographers in the United States (US). It is still useful, however, to also be familiar with the other alternative names for each oblique projection. (In this text, the term RAO will be used.) In figure 3-42, the patient is in an oblique position with the left side closest to the film. The central ray is following a posterior to anterior direct this projection can be described using any of the three names listed in the caption. Again, most radiographers will call this a left anterior oblique (LAO) position. The remaining oblique projections are shown in figures 3-43 and 3-44.

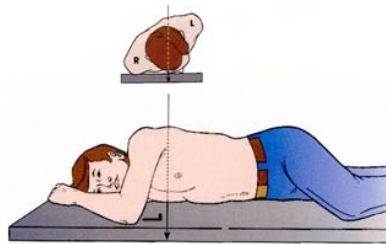


Figure 3-41. Right anterior oblique (RAO), left posterior to right anterior projection in the oblique body position, or right posteroanterior (PA) oblique projection.

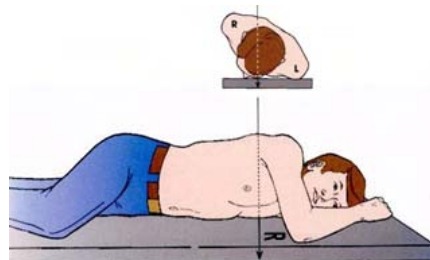


Figure 3-42. Left anterior oblique (LAO), or right posterior to left anterior projection with the patient in the oblique position, or left posteroanterior (PA) oblique projection.



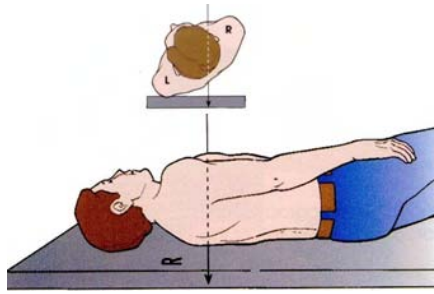


Figure 3-43. A left posterior oblique (LPO) or left anteroposterior (AP) oblique projection or right anterior projection.

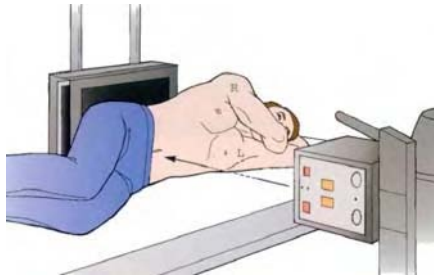


Figure 3-44. Right posterior oblique (RPO) or right anteroposterior oblique.

d. **Decubitus Projections.** To obtain a decubitus projection, the patient must be in a decubitus (lying down) position. In addition, the central ray (CR) must be parallel to the horizon (horizontal). For most decubitus projections the patient assumes a lateral decubitus position, that is, lying on either side. Like the lateral and oblique positions, decubitus positions are named according to the body surface on which the patient is lying.

(1) Left lateral decubitus position. When the patient assumes the left lateral decubitus position (figure 3-45), an AP radiographic projection is produced. Such a projection is particularly useful in diagnosing abdomen and chest air-fluid levels.

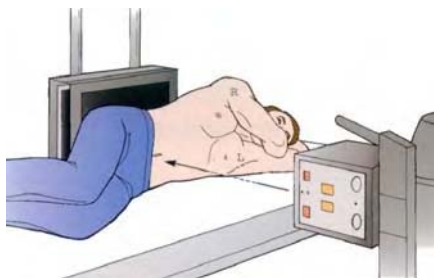


Figure 3-45. A left lateral decubitus position yields an AP projection.

(2) Dorsal decubitus position. A right lateral projection is the radiographic image produced when the patient assumes the dorsal decubitus position (figure 3-46).

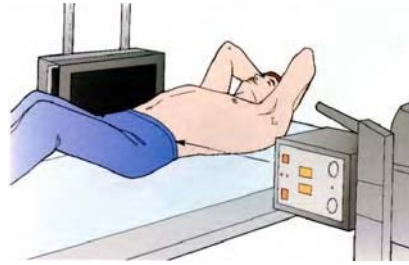


Figure 3-46. A right lateral projection results when the patient is placed in the dorsal decubitus position.

(3) Ventral decubitus position. In the ventral decubitus position (figure 3-47), a left lateral projection can be obtained.

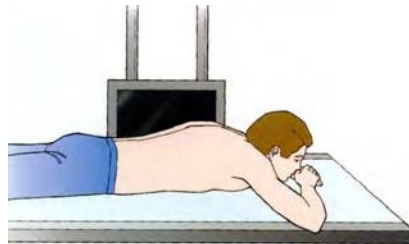


Figure 3-47. A ventral decubitus position produces a left lateral projection.

### 3-22. CENTRAL RAY TERMINOLOGY

a. **Central Ray**. The central ray (CR) (figure 3-48) is the central or principal beam of rays emanating from the X-ray tube. You will need to adjust the CR angle according to the part to be x-rayed and the protections that are desired. Accurate positioning of the part and accurate centering of the central ray are of equal importance in securing a true structural projection.

**central ray:** the central or principal beam of rays emanates from the X-ray tube.

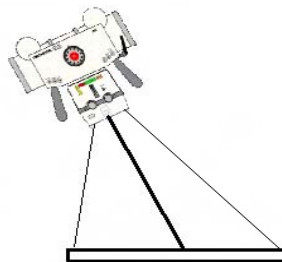


Figure 3-48. The CR is always centered on the film or portion of the film being used.

b. **Straight Central Ray.** A straight central ray forms a 90 degree angle with the film. A straight CR may be vertical perpendicular (VP) or horizontal perpendicular (HP).

**straight central ray:** forms a 90 degree angle with the film.

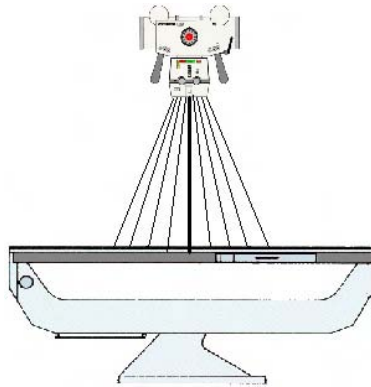


Figure 3-49. This straight CR is vertical perpendicular.

c. **Angled Central Ray.** Alternatively, the central ray may be angled rather than straight. If the central ray is angled, then it forms an angle of less than 90 degrees with the film.

**angled central ray:** central ray that forms an angle of less than 90 degrees with the film.

(1) Angled CR, cephalic. If the angled CR is cephalic, it means that the CR is angled up toward the head, as in figure 3-50 below.

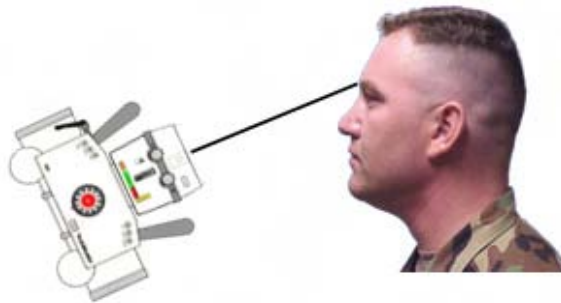


Figure 3-50. Angled CR, cephalic.

(2) Angled central ray, caudal. If, on the other hand, the CR is angled down toward the feet, as in figure 3-51 below, then the CR is angled away from the head,.

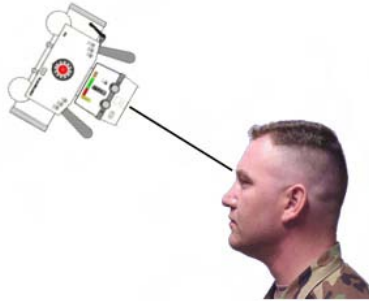


Figure 3-51. Angled CR, caudal.

d. **Patient Positioning.** Patient positioning is the process of assisting the patient onto the X-ray table and into one of the following positions: supine, prone, lateral, or oblique.

e. **Part Position.** Part position is the placement of a specific body part in relationship to the CR. The patient is turned moved around as needed until the body part is centered with the CR.

### 3-23. BREATHING TERMINOLOGY

a. **General.** Giving the correct verbal prompts to the patient regarding breathing just before and after taking the exposure can mean the difference between a good radiograph and one in which the end result is blurred because the patient moved at an inopportune moment.

b. **Suspended Respiration.** Suspended respiration occurs when the patient is instructed to stop breathing. For example, at that moment you press the button to take the exposure, you will instruct the patient to stop breathing.

c. **Suspended Inspiration.** Just before you actually take the exposure, you will instruct the patient to take a deep breath and hold it. This is referred to as suspended inspiration. Again, you will not use this technical term with the patient.

d. **Suspended Expiration.** Just before you make the exposure, you will instruct the patient to take a deep breath, blow it all the way out, and then hold it out. This is referred to as suspended expiration.

e. **Normal Breathing.** As the name suggests, this is when the patient is instructed to continue breathing naturally as he would normally breathe.

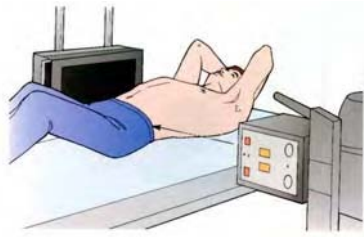**Continue with Exercises**

### EXERCISES, LESSON 3, SECTION III

**MULTIPLE-CHOICE:** For exercise 1 through 22, select the ONE word or phrase that BEST completes the statement or BEST answers the question.

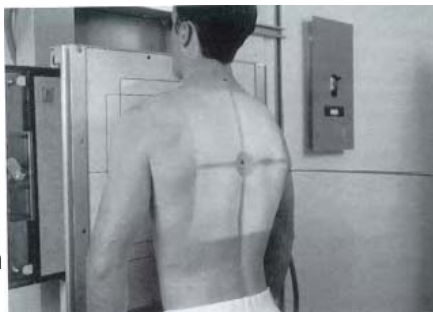1. The frontal projections are the:
  - a. Lateral and oblique projections.
  - b. Anteroposterior and posteroanterior projections.
  - c. Right anterior oblique and LAO projections.
  - d. RPO and LPO projections.
  
2. The dorsal recumbent position, shown below, prepares the patient for a(n):

- a. PA projection.
- b. Oblique projection.
- c. AP projection.
- d. Lateral projection.



3. The upright position shown below prepares the patient for a(n):

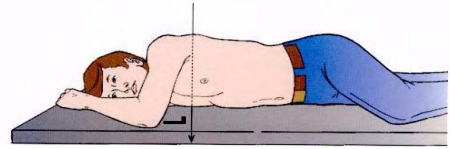
- a. PA projection.
- b. AP projection.
- c. AO projection.
- d. Left anterior oblique projection



4. Lateral projections are named for:
  - a. The author or originator of the method.
  - b. The relationship between the patient's body to the surrounding space.
  - c. The anatomical structure demonstrated.
  - d. The side of the patient closest to the film.
  
5. If the patient is placed in the right lateral position, he is being prepared for a:
  - a. Left lateral projection.
  - b. Left anterior oblique projection.
  - c. Right posterior oblique projection.
  - d. Right lateral projection.
  
6. Which of the following supplement AP and lateral projections?
  - a. PA projections.
  - b. Routines.
  - c. Projections that are angled CR.
  - d. Oblique projections.
  
7. Which category of projections is named for the side and the body surface closest to the film?
  - a. Frontal projections.
  - b. Lateral projections.
  - c. Oblique projections.
  - d. Decubitus projections.

8. Which of the following is the term used by the vast majority of radiographers to describe the projection obtained when the patient is positioned as shown below?

- a. Right posteroanterior (PA) oblique projection.
- b. Left posterior to right anterior projection in the oblique body position.
- c. Right anterior oblique (RAO) projection.
- d. Left posterior oblique (LPO) projection.

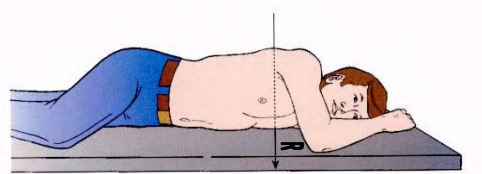


9. The frontal or coronal plane divided the body into:

- a. Right and left halves.
- b. Anterior and posterior portions.
- c. Sections that slant from the main planes.
- d. Superior and inferior portions.

10. Which is the most commonly used name for the projection obtained when the patient is positioned as shown below?

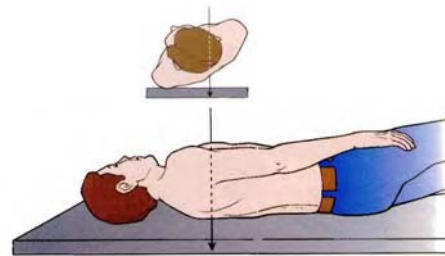
- a. Left posterior oblique (LPO).
- b. Left PA oblique projection.
- c. Left anterior oblique (LAO).



- d. Right posterior to left anterior oblique projection in the oblique body position.

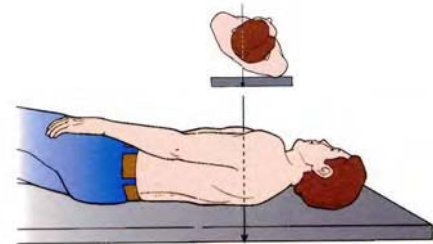
11. Which is the most commonly used name for the projection obtained when the patient is positioned as shown below?

- a. Left posterior oblique (LPO).
- b. Right anterior oblique (RAO).
- c. Left anteroposterior (AP) oblique projection.
- d. Right anterior to left posterior projection in the oblique position.



12. Which is the most commonly used name for the projection obtained when the patient is positioned as shown below?

- a. Left posterior oblique (LPO).
- b. Left anteroposterior (AP) oblique projection.
- c. Right posterior oblique (RPO).
- d. Right anterior to left posterior projection in the oblique position.



13. When the patient is placed in the left lateral decubitus position, a(n) \_\_\_\_\_ projection is produced.

- a. PA.
- b. Left lateral.
- c. LAO.
- d. AP.

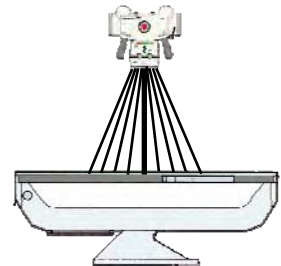14. The radiographic image produced when the patient assumes the dorsal decubitus position is a(n):

- a. Dorsal decubitus.
- b. Left lateral.
- c. AP.
- d. Right lateral.

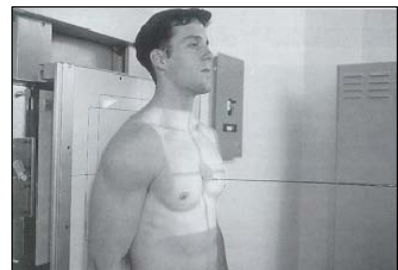

15. When the patient is placed in the ventral decubitus position, a \_\_\_\_\_ projection will be obtained.
- Right lateral projection.
  - Left anteroposterior (AP) oblique.
  - Posteroanterior (PA).
  - Left lateral.
16. How is the central ray always positioned?
- Centered on the film or that portion of the film being used.
  - Angled to form a ninety degree angle with the filter.
  - Angled to form a forty-five degree angle with the film.
  - Centered on the body part to be demonstrated.

17. In a PA projection like the one shown below, the central ray will be:
- Straight horizontal perpendicular (HP).
  - Angled CR (cephalic).
  - Angled CR (caudal).
  - Straight vertical perpendicular (VP).

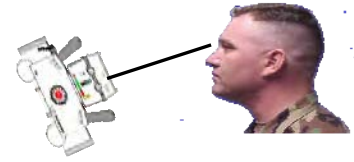


18. In an AP projection as shown, the central ray will be:
- Straight horizontal perpendicular (HP).
  - Angled (caudal).
  - Straight vertical perpendicular (VP).
  - Angled (cephalic).



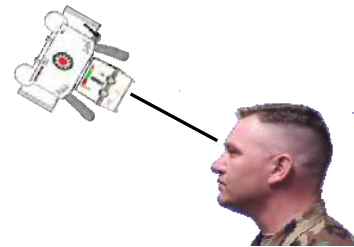
19. In the position, shown below, the central ray is:

- a. Straight horizontal perpendicular (HP).
- b. Angled (cephalic).
- c. Straight vertical perpendicular (VP).
- d. Angled (caudal).



20. In the position shown shown below, the central ray is:

- a. Straight horizontal perpendicular (HP).
- b. Angled (cephalic).
- c. Straight vertical perpendicular (VP).
- d. Angled (caudal).



21. The specific placement of the central ray with relation to an anatomical part or palpation point to ensure proper projection of that body part or palpation point to the center of the film is known as the:

- a. Part positioning.
- b. Patient positioning.
- c. Technique.
- d. Source to image receptor distance.

22. The purpose of the part position is to ensure that:
- a. The CR its accurately centered and the body part of clinical interest (or the necessary palpation point) is correctly positioned.
  - b. The patient is protected from excessive doses of radiation whether or not they are pregnant.
  - c. Such factors as scatter radiation and fog are reduced,
  - d. Unnecessary additional views are eliminated.

**MATCHING.** For exercises 23 through 26, match the term on the left with the appropriate definition. Enter the letter corresponding to your selection in the space provided. There is an extra definition that will not be selected.

- |                                 |   |
|---------------------------------|---|
| 23. Suspended respiration _____ | a. The patient is instructed to breath naturally.   |
| 24. Suspended inspiration _____ | b. The patient is instructed to take a deep breath, blow it all the way out , and then hold it out. |
| 25. Suspended expiration _____  | c. The patient is instructed to take a shallow breath.  |
| 26. Normal breathing _____      | d. The patient is told to take a deep breath and then hold it.                                      |
|                                 | e. Anytime the patient is instructed to stop breathing.   |

**Check Your Answers on Next Page**

### **SOLUTIONS, LESSON 3, SECTION III**

Be sure to re-read and study the paragraph(s) pertaining to any exercises you might have answered incorrectly. The relevant paragraph(s) is (are) listed after each of the answers below.

1. b (para 3-21a)
2. d (para 3-21d(2))
3. a (para 3-21a(2))
4. d (para 3-21b)
5. d (para 3-21b)
6. d (para 3-21c(2))
7. c (para 3-21c(3))
8. c (para 3-21c(3))
9. b (para 3-21a)
10. c (para 3-21c(3))
11. a (para 3-21c(3))
12. c (para 3-21c(3))
13. d (para 3-21d(1))
14. d (para 3-21d(2))
15. d (para 3-21d(3))
16. a (para 3-22a)
17. d (para 3-22b)
18. a (para 3-22b)
19. b (para 3-22c(1))
20. d (para 3-22c(2))
21. a (para 3-22e)
22. a (para 3-22e)
23. e (para 3-23b)
24. d (para 3-23c)
25. b (para 3-23d)
26. a (para 3-23e)

**End of Lesson 3**

## **LESSON ASSIGNMENT**

### **LESSON 4**

Film Identification and Captioning.

### **LESSON ASSIGNMENT**

Paragraphs 4-1 through 4-13.

### **LESSON OBJECTIVES**

After completing this lesson, you should be able to:

- 4-1. Identify entries you must verify on the SF 519-B, Radiologic Consultation Request/Report.
- 4-2. Identify tell-tale inconsistencies in the SF 519-B that signal a possible error.
- 4-3. Identify the importance of the SF 519-B.
- 4-4. Identify basic concepts of film identification.
- 4-5. Identify rules for determining the proper letter marker.
- 4-6. Identify information require on the film caption: method of transmission, patient information, etc.

### **SUGGESTION**

After reading and studying the assignment, complete the exercises at the end of this lesson. These exercises will help you to achieve the lesson objectives.

## LESSON 4

### FILM IDENTIFICATION AND CAPTIONING

#### Section I. THE X-RAY REQUEST FORM

##### 4-1. THE IMPORTANCE OF SCRUTINIZING THE X-RAY REQUEST SLIP

a. **The Heart of the Matter.** What you do in the exposure and processing room is the heart of your job as a radiographer. Essentially, your job is to demonstrate pathology radiographically.

b. **The Importance of the X-Ray Request Slip.** While demonstrating pathology radiographically is the heart of your job, other aspects of the job demand your close attention. The importance of the semi-clerical duties related to verifying the accuracy and internal consistency of entries provided to you on the X-ray request slip cannot be overly emphasized. There is no situation in which proper verification of the information on the X-ray request slip is unimportant. What good is a well demonstrated anatomical structure if it is irrelevant to the condition that the radiologist is trying to rule out? How, for example, can you properly identify the film if the patient's family prefix and social security number are not entered on the request? How can you proceed with reasonable certainty that the X-ray requested is really needed if the requesting physician's signature is not entered on the form? A failure to scrutinize the X-ray request slip with eagle eyes can lead to dire consequences, as the lawsuit described below suggests. In the case cited, the X-ray technologist failed to note that the brief clinical history (specific reasons block) indicated that the patient was heavily sedated. The importance of scrutinizing the X-ray request before proceeding cannot be overly emphasized.

#### **FAILURE TO NOTE CRUCIAL INFORMATION ON THE X-RAY REQUEST SLIP LEADS TO LAWSUIT**

In the case of *Albritton v. Bossier City Hospital Commission* (California, 1972), a patient was hospitalized for abdominal pain resulting from a ruptured appendix and brought to the X-ray table on a gurney. The radiographer did not read the X ray request slip carefully enough, thus failing to notice that the form did not include the required brief clinical history (specific reasons for complains block).

The X-ray technologist also failed to take adequate notice of the patient's condition (the patient was heavily sedated). The technologist proceeded to raise the X-ray table to the vertical position without placing straps or supports on the patient. As would be expected with heavy sedation, the patient fell and a broken an ankle resulted. The hospital was held liable because the radiographer had committed a breach of duty. He had failed to fulfill the requirement to securely strap in a heavily sedated patient. This true story illustrates the importance of reading the X-ray request slip very carefully before proceeding.

#### **4-2. SF 519-B, RADIOLOGICAL EXAM, CONSULTATION REQUEST/REPORT FORM**

a. **Catalyst for Actions Within the Radiology Department.** All actions in the radiology department begin with the Standard Form (SF) 519-B, The Radiological Consultation Request/Report form (figure 4-1). The SF 519-B, commonly referred to as the X-ray request slip, is the basic working document of the X-ray department. It is the catalyst for all subsequent actions within the department. Without the SF 519-B, the activity of the radiology department comes to a screeching halt. You cannot and should not proceed with any exposure without it. The initiation of the SF 519-B by a medical officer and its subsequent journey through the radiology department sets off the cycle of actions that makes it possible for you to take the exposure (figure 4-2).

b. **Ascertaining the Completeness and Accuracy of the SF 519-B.** It is not enough to ensure that the patient has come to the radiology department with an SF 519-B in hand. You must also take the time to verify that the form has been properly filled out. You cannot take X-rays of a patient until you have determined that you have all the information that you need and that all of the information is consistent. (In the anecdote cited on the preceding page, an RT's failure to note the absence of a brief patient history led to a breach of duty, patient injury, a malpractice suit against the hospital, and a consequent blight on the radiographer's record that will take some time to live down.)

c. **Checking for Required Entries on the SF 519-B.** Although local policy may vary, the entries shown in figure 4-3 are generally required. (Note that the middle section, starting with the date of examination and down to the radiologic report, are blank at this point. The radiologist will only be able to make his report after the X-rays have been taken.) Should you discover that the X-ray request is in any way incomplete, you will have to send the patient back to the referring physician unless there are simple gaps that you can easily rectify yourself, such as a missing first name and middle initial. But, for other, more serious, discrepancies the request slip will have to go back to its originator for correction.

NSN 7540-01-165-7294		519-302		
<b>RADIOLOGIC CONSULTATION REQUEST/REPORT</b> <i>(Radiology/Nuclear Medicine/Ultrasound/Computed Tomography Examinations)</i>				
EXAMINATION(S) REQUESTED	AGE	SEX	SSN <i>(Sponsor)</i>	WARD/CLINIC
	FILM NO.			REGISTER NO.
	REQUESTED BY <i>(Print)</i>			PREGNANT <input type="checkbox"/> YES <input type="checkbox"/> NO
	SIGNATURE OF REQUESTOR			TELEPHONE/PAGE NO.
DATE REQUESTED				
SPECIFIC REASON(S) FOR REQUEST <i>(Complaints and findings)</i>				
DATE OF EXAMINATION <i>(Month, day, year)</i>	DATE OF REPORT <i>(Month, day, year)</i>	DATE OF TRANSACTION <i>(Month, day, year)</i>		
RADIOLOGIC REPORT				
PATIENT'S IDENTIFICATION <i>(For typed or written entries give: Name - last, first, middle, Medical Facility)</i>		LOCATION OF MEDICAL RECORDS		
		LOCATION OF RADIOLOGIC FACILITY		
		SIGNATURE		
		RADIOLOGIC CONSULTATION REQUEST/REPORT		
		STANDARD FORM 519-B (Rev. 8-83) Prescribed by GSA/ICMR FIRM (41 CFR) 201-45.505		
1 - Medical Record				

Figure 4-1. SF 519-B. Radiologic Consultation Request/Report.



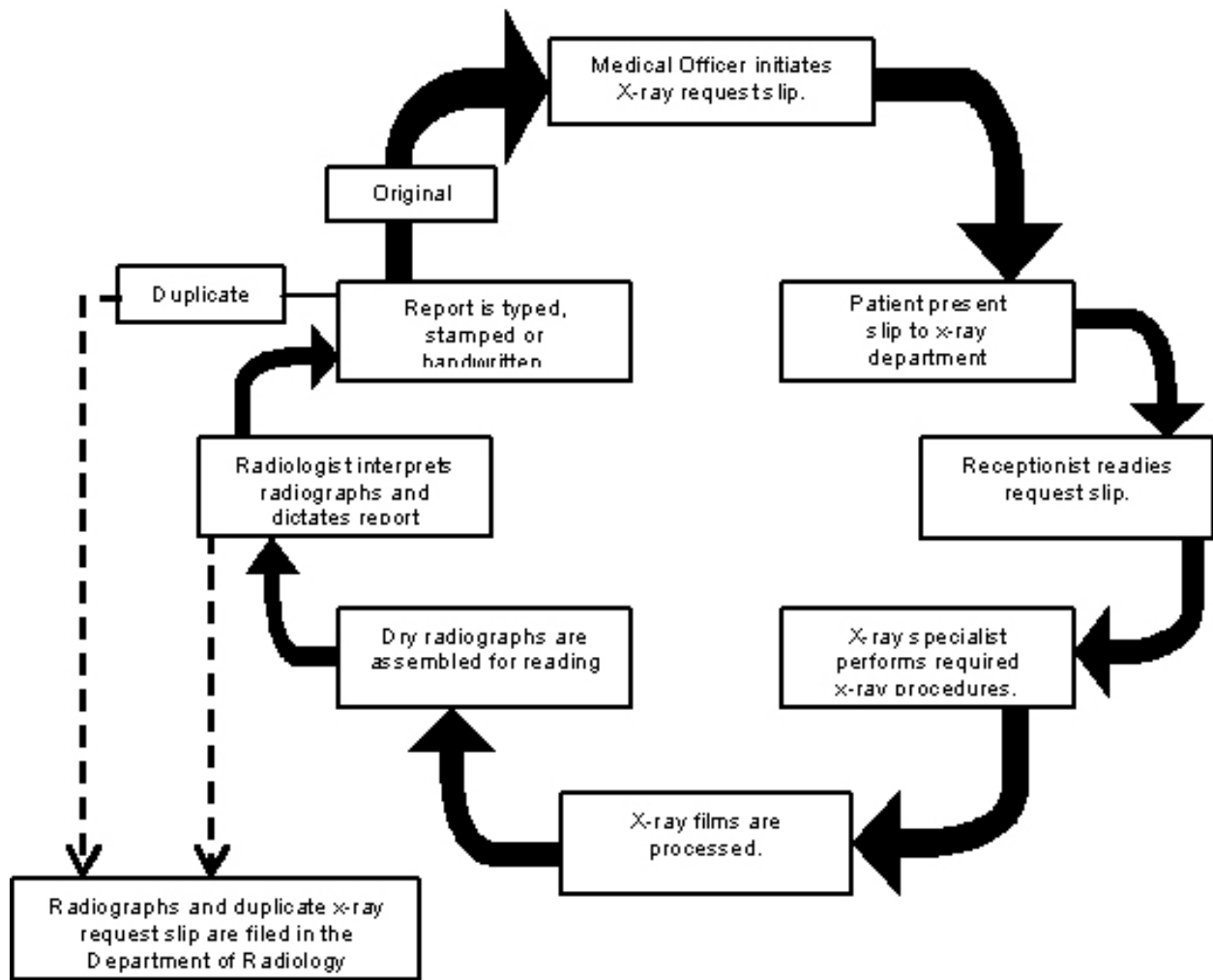



Figure 4-2. The journey of the X-ray slip through the radiology department.

**RADIOLOGIC CONSULTATION REQUEST/REPORT**  
(Radiology/Nuclear Medicine/Ultrasound/Computed Tomography Examinations)

EXAMINATION(S) REQUESTED  <b>Skull</b>	AGE	SEX	SSN (Sponsor)	WARD/CLINIC	REGISTER NO.
	36	M	20-123-45-0666	ER	
	FILM NO.				PREGNANT <input type="checkbox"/> YES <input type="checkbox"/> NO
	REQUESTED BY (Print) Dr. Gilbert Ortiz				TELEPHONE/PAGE NO. 1-7633
SIGNATURE OF REQUESTOR 				DATE REQUESTED 22 Jun 2004	

SPECIFIC REASON(S) FOR REQUEST (Complaints and findings)

Hx of lbc due to head trauma with rubber mallet while installing floor tiles in home.  
Profuse bleeding from head. R/O skull fractures

DATE OF EXAMINATION (Month, day, year)	DATE OF REPORT (Month, day, year)	DATE OF TRANSCRIPTION (Month, day, year)

RADIOLOGIC REPORT

PATIENT'S IDENTIFICATION (For typed or written entries give:  
Name - last, first, middle, Medical Facility)

Davis, Craig R.  
20-123-56-0666  
A/D SFC  
F Troop, RSS 2<sup>nd</sup> ACR  
555-1234  
GLWACH

LOCATION OF MEDICAL RECORDS

McWethy Troop Medical

LOCATION OF RADIOLOGIC FACILITY

GLWACH Ft. Leonard Wood

SIGNATURE

RADIOLOGIC CONSULTATION  
REQUEST/REPORT  
1 - MEDICAL RECORD

STANDARD FORM 519-B (8-83)  
Prescribed by GSA/ICMR  
FPNTR (41 CFR) 101-11.806-8

Figure 4-3. X-ray request slip, as it appears when the patient first brings it to the X-ray Department, with no entries in middle sections.

### 4-3. THE PATIENT'S IDENTIFICATION BLOCK

a. **Verify Patient Information.** The first thing you should look at is the lower left-hand corner of the form (figure 4-4).

(1) Check for the patient's name. Then, verify the family member prefix plus social security number (SSN). (In this case, the sponsor prefix, 20, precedes the SSN, indicating the patient is the service member.) Next, look for the component, rank, and unit, to include the unit address and telephone number. The unit is needed so that the patient may be reached, if necessary. Note that the patient's full name is required so as to avoid confusion with others of the same name. (This common error of omission makes it hard to determine whether the patient is the soldier, a dependent, or perhaps even another soldier, entirely.) One other common error is using the sponsor prefix, 20, when the patient is one of the soldier's dependents. The X-ray request slip must provide the radiographer needs to demonstrate pathology radiographically. Equally important, is administrative information about the patient. The patient's rank, if military, is needed so that the patient can be properly addressed by health care providers. The sponsor's social security number (SSN) is needed for film filing purposes.

(2) Consider figure 4-5 below. Note that right below the SSN block is film number block. Thus, the sponsor's SSN also serves as the film number for tracking purpose. The first time a patient is sent to the Radiology Department with an X-ray request slip, a radiology file envelope (used to store the patient's radiographs) is started. For ease of retrieval, the terminal (last four) digits of the sponsor's SSN are placed lengthwise along the right edge of the envelope and are color coded (figure 4-6). The full SSN is also placed across the top right corner of the folder, with each of the digits from 0 to 9 assigned a different color. In the case of SFC Deborah H. Berry, whose terminal digits are 0000, four orange zeroes would be placed lengthwise on the right edge of her folder, as shown in figure 4-6. The four big color-coded stickers can be instantly picked out, whereas the handwritten name and full SSN (which also appear on the form take more time to locate and read. You can appreciate the importance of accuracy on the SF 519-B X-ray request slip when you consider that key pieces of information (sponsor's SSN, family member prefix, name, terminal digits of the SSN, etc.) are transposed from the SF 519-B onto the patient's radiographic envelope and other documents.

RADIOLOGIC CONSULTATION REQUEST REPORT (Military, Reserve, National Guard, Component, Contingent, Detachment)			
EXAMINATION REQUESTED	PATIENT'S SIGNATURE 36 M 20-123-45-0666	MARKING ER	REGISTER NO.
Skull series	PHYSICIAN Dr. Guillermo Ortiz	PHYSICIAN'S PHONE NO. 1-7633	DATE REQUESTED 22 Jun 2004
SPECIFIC INSTRUCTIONS REQUEST (Appendix and Tables)			
Hit of loc due to head trauma with rubber mallet while installing floor tiles in home. Profuse bleeding from head. R/O skull fractures			
DATE OF EXAMINATION (Month, Day, Year)	DATE OF REPORT (Month, Day, Year)	DATE OF TRANSMISSION (Month, Day, Year)	
RADIOLOGIC REPORT			
SECTION OF MEDICAL RECORD Davis, Craig R. 20-123-56-0666 A/D SFC F Troop, RSS 2 <sup>nd</sup> ACR 555-1234 GLWACH		SECTION OF MEDICAL RECORD McWethy Troop Medical Clinic SECTION OF RADIOLOGY FACILITY GLWACH Ft Leonard Wood, Missouri SIGNATURE RADIOLOGIC CONSULTATION REQUEST REPORT STANDARD FORM 100-1 (FORM 100-1) (1-10-04)	



PATIENT'S IDENTIFICATION (For typed or written entries give: Name — last, first, middle, Medical Facility)	LOCAT	SIGNAT
Davis, Craig R. ¶		Full-Name ¶
20-123-56-0666 ¶	LOCAT	Sponsor-prefix-&-SSN ¶
A/D SFC ¶		Component-&-Rank ¶
F Troop, RSS 2 <sup>nd</sup> ACR ¶		Unit-&-Phone-Number ¶
555-1234 ¶		
GLWACH ¶		

Figure 4-4. The patient identification block of the X-ray request slip.

GOVERNMENT PRINTING OFFICE: 1984-450-337

### CONSULTATION REQUEST/REPORT

*(Medicine/Ultrasound/Computed Tomography Examinations)*

AGE	SEX	SSN (Sponsor)	WARD/CLINIC	REGISTER
		20-123-45-0666		
FILM NO.				PREGNANT
298-88-0000				<input type="checkbox"/> YES
REQUESTED BY (Print)				TELEPHONE
NAME OF REQUESTOR				DATE REQUESTED
REPORT (Month, day, year)				DATE OF TRANSCRIPTION (Month, day, year)

U.S. GOVERNMENT PRINTING OFFICE: 1984-450-337

### RADIOLOGIC CONSULTATION REQUEST REPORT

*(Medicine/Ultrasound/Computed Tomography Examinations)*

EXAMINATION REQUESTED: Skull series

DATE OF EXAMINATION: 22 Jun 2004

DATE OF REPORT: 22 Jun 2004

DATE OF TRANSCRIPTION: 22 Jun 2004

INDICATION: Hx of lac due to head trauma with rubber mallet while installing floor tiles in home. Profuse bleeding from head. R/O skull fractures.

LOCATION OF MEDICAL RECORD: McWethy Troop Medical Clinic

LOCATION OF RADIOLOGY: GLWACH Ft Leonard Wood, Missouri

DA Form 3443

Figure 4-5. Blocks in the upper right-hand corner of the form (sponsor's SSN and film number).

298800000

20

Berry

Deborah

CHARGED OUT RECORDS

0000

2

DA Form 3443

Terminal digits (color-coded)

Year folder initiated or Year of last X-ray

Figure 4-6. For SFC Deborah H. Berry, whose terminal digits are 0000, four orange zeroes are placed lengthwise along the right edge of her Radiology File Envelope for ease of recognition.

**b. Family Member Prefix + SSN.**

(1) See figure 4-7 for the Berry family's family member prefixes. SFC Deborah Berry's SSN is preceded by the two-digit family member prefix, 20. The prefix, 20, indicates that she is a sponsor or service member. Since her husband, SFC John R. Berry, is also a service member, his SSN is preceded by the sponsor prefix, 20, as well. The Berry children have the family member prefixes 01 and 02, respectively, to indicate order of birth. (Note that nonmilitary dependents are identified by the SSN of the service member/head of household.)

<b>FAMILY MEMBER PREFIXES</b>	
20-298-88-0000	SFC Deborah H. Berry
20-272-77-3256	SFC John R. Berry
01-272-77-3256	Kevin M. Berry
02-272-77-3256	Sara A. Berry

Figure 4-7. Family member prefixes (first two digits) of the Berry family.

(2) Now, consider the family prefixes of the Jones family (figure 4-8). The head of household is a sponsor (service member). His dependent spouse is not the service. In this case, since Mrs. Jones is not in the service, she is considered a dependent and is identified, like the children, by PFC Jones' SSN. The family prefix for a dependent spouse is 30.

20-466-90-1655	PFC Ronald R. Jones
30-466-90-1655	Mrs. Alice K. Jones
01-466-90-1655	Ronald R. Jones, Jr.
02-466-90-1655	Amy T. Jones

Figure 4-8. Family member prefixes of the Jones family.

(3) When an individual returns for additional X-rays, the patient's radiographic folder, color coded and filed under the terminal digits of the sponsor's SSN, is pulled from the files. In the case of SFC Deborah H. Berry, the X-ray technologist would look for four orange zeroes as he thumbed through the radiographic envelopes.) The radiographs in each envelope are stored in consecutive order, with the most recent X-ray on top. That way, the first thing the radiologist will pull from the folder is the most recent X-ray. The radiologist can then work back consecutively, if need be.

#### 4-4. EXAM REQUESTED AND SPECIFIC REASONS (BRIEF CLINICAL HISTORY)

Let's move on to the upper left-hand corner of the X-ray slip. Two very important blocks located here are the examination requested and specific reasons for request blocks. (The reason for request block is equivalent to the brief clinical history.) A common error is to list a reason that is not consistent with the exam, for example, the radiologist requesting an X-ray of the right ankle, but indicates in the reason block that a fracture of the foot must be ruled out.

The magnified view shows two blocks:

- EXAMINATION(S) REQUESTED:** Skull series
- SPECIFIC REASON(S) FOR REQUEST (Complaints and findings):** Hx of loc due to head trauma with rubber mallet while installing floor tiles in home. Profuse bleeding from head. R/O skull fractures

The full form below contains the following information:

- EXAMINATION(S) REQUESTED:** Skull series
- SPECIFIC REASON(S) FOR REQUEST (Complaints and findings):** Hx of loc due to head trauma with rubber mallet while installing floor tiles in home. Profuse bleeding from head. R/O skull fractures
- DEPARTMENT OF RADIOLOGY:** 20-123-45-0666 ER
- REGISTER NO.:** 1-7633
- DATE REQUESTED:** 22 Jun 2004
- REQUESTED BY NAME:** Dr. Guillermo Ortiz
- DEPARTMENT OF MEDICAL RECORDS:** McWethy Troop Medical Clinic
- DEPARTMENT OF RADIOLOGY:** GLWACH Ft Leonard Wood, Missouri
- REQUESTOR:** Davis, Craig R. 20-123-56-0966 A/D SFC F Troop, R55 2<sup>nd</sup> ACR 555-1234 GLWACH

Figure 4-9. Exam requested and specific reasons block.

#### 4-5. AGE, SEX, WARD, AND PREGNANCY BLOCKS

Refer to the top section of the SF 519-B. You will next have to verify that the patient's age, sex, ward, and pregnancy status have been entered (figure 4-10). The radiologist needs the patient's age and sex to evaluate the X-rays. The ward or clinic is needed so that the radiologist's report will go to the right place. It is absolutely essential that you ask your female patients if they are or could be pregnant. This information will affect how you proceed. The X-rays may be cancelled or, if the X-rays should be necessary despite the risks to the fetus, the X-ray dosage will have to be adjusted accordingly. A pregnancy entry is also needed to protect against possible lawsuits. Pregnant patients should generally not be exposed to ionizing radiation. If pregnant block indicates "yes," you should double check with the referring physician before proceeding.

The diagram illustrates the 'AGE, SEX, WARD, AND PREGNANCY BLOCKS' on a radiologic consultation request form. It features three callout boxes with arrows pointing to the corresponding fields on the form:

- AGE/SEX BLOCK:** A box containing 'AGE' with the value '36' and 'SEX' with the value 'M'.
- WARD/CLINIC BLOCK:** A box containing 'WARD/CLINIC' with the value 'ER'.
- PREGNANT BLOCK:** A box containing 'PREGNANT' with two checkboxes: 'YES' (unchecked) and 'NO' (checked).

The main form is titled 'RADIOLOGIC CONSULTATION REQUEST/REPORT' and includes the following information:

- EXAMINATION REQUESTED:** Skull series
- PATIENT INFORMATION:** 36 M, 20-123-45-0666, ER
- REGULATED BY:** Dr. Guillermo Ortiz
- PHYSICIAN'S SIGNATURE:** [Signature]
- PHONE NUMBER:** 1-7633
- DATE REQUESTED:** 22 Jun 2004
- INDICATION:** Hx of ltc due to head trauma with rubber mallet while installing floor tiles in home. Profuse bleeding from head. R/O skull fractures
- LOCATION OF MEDICAL RECORD:** McWethy Troop Medical Clinic
- LOCATION OF RADIOLOGIC FACILITY:** GLWACH Ft Leonard Wood, Missouri
- REFERRING PHYSICIAN'S NAME AND ADDRESS:** Davis, Craig R, 20-123-56-0666, A/D SFC, F Troop, RSS 2<sup>nd</sup> ACR, 555-1234, GLWACH

Figure 4-10. Age, sex, ward, pregnancy blocks.



**4-6. REQUESTOR'S NAME, SIGNATURE, TELEPHONE/PAGER NUMBER AND DATE BLOCKS**

Refer to figure 4-11. The requesting physician's name should be printed or typed in the requestor's name block. The physician's signature should appear in the signature block. The requester's telephone number and page number should be indicated in the appropriate block. The date of the request should also be indicated. It should be noted that many X-ray request slips are sent back because the referring physician failed to provide his or her signature on the form.

<b>REQUESTED BY (Print)</b> Dr. Guillermo Ortiz		<b>TELEPHONE/PAGE NO.</b> 1-7633
<b>SIGNATURE OF REQUESTOR</b> <i>[Handwritten Signature]</i>		<b>DATE REQUESTED</b> 22 Jun 2004

<b>EXAMINATION REQUESTED</b> Skull series		
<b>AGE/SEX</b> 30 M	<b>PHONE</b> 20-123-45-0666	<b>DEPARTMENT</b> ER
<b>FLORIDA</b>	<b>REGISTERED</b> Dr. Guillermo Ortiz	<b>TELEPHONE/PAGE NO.</b> 1-7633
<b>SIGNATURE OF REQUESTOR</b> <i>[Handwritten Signature]</i>	<b>DATE REQUESTED</b> 22 Jun 2004	

**SPECIFIC REASON FOR REQUEST (State in brief)**  
Hx of lcc due to head trauma with rubber mallet while installing floor tiles in home. Profuse bleeding from head. R/O skull fracture.

**DATE OF EXAMINATION (MM, DD, YYYY)**    **DATE OF REPORT (MM, DD, YYYY)**    **DATE OF TRANSCRIPTION (MM, DD, YYYY)**

**LOCATION OF MEDICAL RECORDS**  
McWethy Troop Medical Clinic

**LOCATION OF RADIOLOGY DEPARTMENT**  
GLWACH Ft Leonard Wood, Missouri

**SIGNATURE**

**REQUESTOR INFORMATION**  
1 - MEDICAL RECORDS

**STANDARD FORM 1016 - 611**  
FORM 21 10-97 2011-000-0

Figure 4-11. Requestor information blocks.

#### 4-7. LOCATION OF MEDICAL RECORDS BLOCK

Look for the location of the medical records block in the lower right-hand corner of the form (figure 4-12). The location is needed to ensure that the radiologic report is placed in the patient's medical record. If the patient is an inpatient, the results will be sent to the ward or clinic listed at the top of the X-ray request slip. If the patient has been discharged by the time the radiologic report is complete, the report will be forwarded by the ward or clinic to the place listed in the location of medical records block.

NOTE: Figure 4-13 summarizes the information on SF 519-B that is to be verified.

The image shows a 'RADIOLOGIC CONSULTATION REQUEST/REPORT' form. The 'EXAMINATION REQUESTED' field contains 'Skull series'. The 'PATIENT' field contains '38 M 20-123-45-0666 ER'. The 'REGISTERED BY' field contains 'Dr. Guillermo Ortiz' with a signature. The 'DATE REQUESTED' field contains '22 Jun 2004'. The 'SPECIFIC REQUEST/TEST REQUEST (INCLUDE ALL STORAGE)' field contains 'Hx of lcc due to head trauma with rubber mallet while installing floor tiles in home. Profuse bleeding from head. R/O skull fractures'. The 'LOCATION OF MEDICAL RECORDS' field is highlighted with a box and an arrow pointing to a separate box labeled 'LOCATION OF MEDICAL RECORDS' containing 'McWethy Troop Medical Clinic'. The 'LOCATION OF RADIOLOGIC FACILITY' field is also visible at the bottom of the separate box.

Figure 4-12. Location of medical record block.

## **X-RAY REQUEST ENTRIES**

### **BOTTOM OF FORM**

1. Patient's full name.
2. Family member prefix + sponsor's SSN.
3. Component/rank.
4. Unit/unit telephone number.

### **TOP OF FORM**

5. Exam requested.
6. Patient's age.
7. Sex.
8. Family member prefix + sponsor's SSN.
9. Ward/clinic.
10. Film No. (=SSN).
11. Pregnancy status (female patients).
12. Requesting physician's name.
13. Requesting physician's signature.
14. Requesting physician's telephone/pager number.
15. Date requested.
16. Exam requested.
17. Specific reasons for request.  
(Brief clinical history.)

Figure 4-13. Required entries that must be verified.

#### **4-8. THE RADIOLOGIST'S REPORT**

The middle blocks of the X-ray request slip will remain blank until the X-rays have been taken, forwarded to the radiologist, and evaluated. Thus, you should only look for these entries after the X-ray work has been completed. Once these steps have been accomplished, check the middle blocks for accuracy and consistency. Look for the date of the exam, the date of the report, the date of transcription, the radiologic report with the radiologist's name, rank, and title in the middle blocks, as shown in figure 4-14. Jumping down to the lower right-hand portion of the form, look for the location of the radiologic facility and the radiologist's signature.

5010-106-0101 U.S. GOVERNMENT PRINTING OFFICE: 1994-46337

**RADIOLOGIC CONSULTATION REQUEST/REPORT**  
(Kathode Ray, Nuclear Medicine, Ultrasound, Computed Tomography Examinations)

EXAMINATION REQUESTED  <b>Skull series</b>	AGE/SEX (Month/Year)	WARD/CLINIC	REGISTER NO.
	35/M 20-123-45-0666	ER	
	FIELD NO.		PREGNANT <input type="checkbox"/> YES <input type="checkbox"/> NO
	REQUESTED BY (Print)		TELEPHONE (PAGE NO.) 1-7633
	Dr. Guillermo Ortiz		DATE REQUESTED 22 Jun 2004
	SIGNATURE OF REQUESTOR <i>[Signature]</i>		

SPECIFIC REASON(S) FOR REQUEST (Symptoms and Signs):  
  
Hx of lcc due to head trauma with rubber mallet while installing floor tiles in home.  
Profuse bleeding from head. R/O skull fractures

DATE OF EXAMINATION (Month, day, year) <b>22 Jun 04</b>	DATE OF REPORT (Month, day, year) <b>22 Jun 04</b>	DATE OF TRANSCRIPTION (Month, day, year) <b>22 Jun 04</b>
--	---	--

RADIOLOGIC REPORT

**SKULL SERIES:** The bony calvarium is intact. The base of the sella turcica are normal in appearance. The visualized facial bones and paranasal sinuses are unremarkable.

**IMPRESSION:** NORMAL SKULL.

John B. Mayes  
COL, MC  
Radiologist

REFERRING PHYSICIAN (Print name of provider) (Name - last, first, middle, initial/initials)  Davis, Craig R. 20-123-56-0666 A/D SFC F Troop, RSS 2 <sup>nd</sup> ACR 555-1234 GLWACH	LOCATION OF MEDICAL RECORDS <b>McWethy Troop Medical Clinic</b>  LOCATION OF RADIOLOGIC FACILITY <b>GLWACH Ft Leonard Wood, Missouri</b>  SIGNATURE <i>[Signature: John B Mayes]</i>  RADIOLOGIC CONSULTATION REQUEST/REPORT 1 - MEDICAL RECORD	STANDARD FORM 519-B (9-83) Prescribed by GSA/GCMR *FPMR (41 CFR) 101-11.606-8
--	--	---

Figure 4-14. Radiographer's report entries.

#### 4-9. THE PROCEDURE WORKSHEET--COMPOSITE HEALTH CARE SYSTEM

a. **Composite Health Care System.** The Composite Health Care System (CHCS) is a hospital information system adopted by the tri-services (Army, Navy, and Air Force) and used to automate the entire realm of patient care and administrative activities within a medical treatment facility. With this system, an authorized healthcare provider could order an X-ray exam via a CHCS computer workstation. The receptionist or technologist in the radiology department could generate an electronic version of the SF 519-B. The "Procedure Worksheet," as it is also known by, can be uniquely formatted for the needs of the different modalities within a radiology department (figures 4-15 and 4-16). The Procedure Worksheet has replaced the SF 519-B as the primary request form for X-ray examinations. The SF 519-B is still used in medical treatment facilities not equipped with CHCS, medical field units, and as a back-up form.

b. **Procedure Worksheet Segments.** The three segments that comprise the procedure worksheet are the patient demographics, a procedure segment, and a work area segment. The work area segment contains selected work statement fields as follows: medications, prior surgeries, two pregnancy statements, radiologist plan, radiopharmaceutical data, lab results, exam comments, film utilization, and technique factors.

c. **Patient Demographics.** This segment of the worksheet (figure 4-17) contains patient specific information, such as, the patient's name, family member prefix/SSN, rank, date of birth, age, gender, and pregnancy status if applicable. In this area, CHCS also prints a barcode that links this information to the requested exam. The patient demographics segment will always be printed at the top of the worksheet. The information fields which will be displayed within this area cannot be changed.

PROCEDURE WORKSHEET  
BROOKE ARMY MEDICAL CENTER -- MAIN RADIOLOGY

Patient: VAIL, NANCY N  
FMP/SSN: 20/100-20-0251 Rank: MAJ  
DOB: 16 Mar 1974 Age: 27y  
Reg #: Sex: F Pregnant? Unknown



1. HAND, RT  
Proc. Code: 0410  
Exam No. : 01001118 Priority: ROUTINE  
Req. HCP: DOCTOR, AARON Req. Location: INTERNAL MEDICINE CLINIC  
Duty Phone: 555-8922 Beeper #:  
NO BRIEF COMMENT

Hx of trauma to rt hand after beating-up husband's girlfriend: r/o fx  
Exam Status: ARRIVED Scheduled Date/Time:  
Arrival Date/Time: 01 Jul 2001@1557 Departure Date/Time:

\*\*\* PREGNANCY STATEMENT \*\*\*

Are you pregnant? YES: \_\_\_ NO: \_\_\_ Date of Last Menses: \_\_\_\_\_  
Are you breast feeding? YES: \_\_\_ NO: \_\_\_

Patient Signature: \_\_\_\_\_

\*\*\* FILM UTILIZATION \*\*\*

Film size	# Repeats	Reason	Total Exposures
Additional Films		Reason	

\*\*\* TECHNIQUE FACTORS \*\*\*

View	Distance	KVP	MA	MAS	Time

Exam Comments: \_\_\_\_\_

Figure 4-15. Composite Health Care System worksheet for main radiology department.

```

Personal Data - Privacy Act of 1974 (PL 93-579)          Printed: 21 Jun 2001@1537

                P R O C E D U R E   W O R K S H E E T
                BROOKE ARMY MEDICAL CENTER -- ULTRASOUND                      Pg. 1
=====
Patient: SMITH, DENISE L
FMP/SSN: 30/555-58-5483 Rank:
DOB: 06 Jun 1959 Age: 42y
Reg #: Sex: F Pregnant? Yes
=====
1. US, OB
Proc. Code: 4360
Exam No. : 01001130
Req. HCP: JOHNSTON, FRANK
Duty Phone:
NO BRIEF COMMENT

Priority: ROUTINE
Req. Location: 10A
Beeper #:

PETAL AGE UNKNOWN. PLEASE EVALUATE
Exam Status: ARRIVED
Arrival Date/Time: 21 Jun 2001@1537
Scheduled Date/Time:
Departure Date/Time:
=====
                *** PREGNANCY HISTORY ***

LMP: _____ Para: _____ Gravida: _____ Ab: _____

=====
Prior Surgeries:

=====
Comments:
=====

```

Figure 4-16. Composite Health Care System Worksheet for ultrasound.

```

Personal Data - Privacy Act of 1974 (PL 93-579)          Printed: 21 Jun 2001@1537

                P R O C E D U R E   W O R K S H E E T
                BROOKE ARMY MEDICAL CENTER -- ULTRASOUND                      Pg. 1
=====
Patient: SMITH, DENISE L
FMP/SSN: 30/555-58-5483 Rank:
DOB: 06 Jun 1959 Age: 42y
Reg #: Sex: F Pregnant? Yes
=====

```

Figure 4-17. Patient demographics segment.

d. **Procedure Segment.** This segment (figure 4-18) contains information specific to the requested exam. This segment will always be printed under the patient demographics area and, like the patient demographics segment, the information fields cannot be changed.

```

=====
1. US, OB
Proc. Code: 4360
Exam No. : 01001130          Priority: ROUTINE
Req. HCP: JOHNSTON,FRANK    Req. Location: 10A
Duty Phone:                  Beeper #:
NO BRIEF COMMENT

FETAL AGE UNKNOWN. PLEASE EVALUATE
Exam Status: ARRIVED        Scheduled Date/Time:
Arrival Date/Time: 21 Jun 2001@1537  Departure Date/Time:
=====

```

Figure 4-18. Procedure segment.

e. **Work Area Segment.** This segment (figure 4-19) contains preformatted statements which can be used to uniquely format the worksheet for exams in different imaging modalities, such as ultrasound, mammography, and computed tomography. The preformatted pregnancy statements, if used, can be set to print out for female patients only if they are within the childbearing age.

```

=====
*** PREGNANCY HISTORY ***
LMP: _____ Para: _____ Gravida: _____ Ab: _____
=====
Prior Surgeries:
=====
Comments:
=====

```

Figure 4-19. Work area segment.

**Continue with Exercises**



## EXERCISES, LESSON 4, SECTION I

**MULTIPLE CHOICE.** For exercises 1 through 7, select the ONE word or phrase that BEST completes the statement or BEST answers the question.

1. Radiographic demonstration of pathology is the heart of your job. But, a good clear X-ray that accurately visualizes the anatomical part of clinical interest is useless to the radiologist (and to the patient) without:
  - a. Accurate film identification.
  - b. Computed tomography.
  - c. A thorough check of vital signs.
  - d. Patient consent.
  
2. If the patient arrives in the radiology department without a properly filled out X-ray request slip, you should:
  - a. Do the best you can without it.
  - b. Obtain a patient waiver before proceeding with the exposures.
  - c. Send the patient back to the requesting physician.
  - d. Proceed with the exposures, anyway.
  
3. The SF 519-B is the catalyst for your actions in the radiology department because it:
  - a. Indicates the patient's consent to treatment.
  - b. Provides information about the exam required, the patient's condition, and his identity.
  - c. Provides the technique factors.
  - d. Contains the patient's record of service.

4. If the patient's X-ray request slip lists the number, 20-466-90-1655, it means that you will be taking radiographs of:
  - a. A service member.
  - b. The spouse of the service member,
  - c. The service member's eldest child.
  - d. The service member's second child.
  
5. A child comes to the radiology department for X-rays. The social security number (SSN) that you will find listed on the SF 579B (under the entry "register no") is that of the:
  - a. Child.
  - b. Child's mother.
  - c. Head of the household/service member.
  - d. Child's surrogate.
  
6. On the radiographic envelope, the terminal digits of the sponsors SSN are\_\_\_\_\_ for ease of retrieval:
  - a. Computer dated.
  - b. Listed in alphabetical order by last name.
  - c. Listed chronologically by year.
  - d. Color coded.

7. A radiographer fails to review the SF 519-B carefully, thus, failing to strap in a patient who is heavily sedated. This oversight is probably due to the fact that he failed to read the:
  - a. Brief clinical history.
  - b. Exam requested.
  - c. Patient identification entries.
  - d. All of the above.

**IDENTIFICATION. For exercises 8 through 18,** imagine that a patient has just brought you the SF 519-B shown on the below. Identify correctly entered entries by writing the word okay. For incorrect entries, write in the statement that would make that entry correct.

8. Patient name. \_\_\_\_\_
9. Patient's rank \_\_\_\_\_
10. SSN. \_\_\_\_\_
11. AGE. \_\_\_\_\_
12. Unit. \_\_\_\_\_
13. Ward or clinic. \_\_\_\_\_
14. Exam requested. \_\_\_\_\_
15. Pregnant. \_\_\_\_\_
16. Specific reasons (brief clinical history). \_\_\_\_\_
17. Date of request. \_\_\_\_\_
18. Requesting physician. \_\_\_\_\_

**RADIOLOGIC CONSULTATION REQUEST/REPORT**  
(Radiology/Nuclear Medicine/Ultrasound/Computed Tomography Examinations)

EXAMINATION(S) REQUESTED  Right ankle	AGE	SEX	SSN (Sponsor)	WARD/CLINIC	REGISTER NO.
	12	F	20-298-88-0000		000001
	FILM NO.				PREGNANT
	298-88-0000				<input type="checkbox"/> YES <input checked="" type="checkbox"/> NO
	REQUESTED BY (Print)				TELEPHONE/PAGE NO.
Dr, Sandra Miller				1-6842 6511	
SIGNATURE OF REQUESTOR				DATE REQUESTED	20 Dec 92

**SPECIFIC REASON(S) FOR REQUEST (Complaints and findings)**

Patient was running and stepped in a hole. Rule out fracture of the foot.

DATE OF EXAMINATION (Month, day, year)	DATE OF REPORT (Month, day, year)	DATE OF TRANSCRIPTION (Month, day, year)
20 Dec 92	20 Dec 92	20 Dec 92

**RADIOLOGIC REPORT**

AP, lateral and oblique radiographs of the right ankle were obtained. Mild soft tissue swelling on the lateral aspect of the ankle was noted. No fracture was seen.

John B. Smith  
MAJ, MC  
Radiologist

**PATIENT'S IDENTIFICATION (For typed or written entries give: Name -- last, first, middle, Medical Facility)**

Berry, Sarah M.  
  
A/D SFC  
23rd Combat Support Hospital  
555-3490  
Brooke Army Medical Center

**LOCATION OF MEDICAL RECORDS**

Troop Medical Clinic #8

**LOCATION OF RADIOLOGIC FACILITY**

Brooke Army Medical Center Fort Sam Houston, Texas

**SIGNATURE**

*John B. Smith*

RADIOLOGIC CONSULTATION  
REQUEST/REPORT  
1 - MEDICAL RECORDS

STANDARD FORM 519-B (8-83)  
Prescribed by GSA/ICMR  
FPMR (41 CFR) 101-11.906-8

(SAMPLE)

**Check Your Answers on Next Page**

## **SOLUTIONS, LESSON 4, SECTION I**

Be sure to re-read and study the paragraph(s) pertaining to any exercises you might have answered incorrectly. The relevant paragraph(s) is (are) listed after each of the answers below.

1. a (para 4-1b)
2. c (para 4-2c)
3. b (paras 4-2, 4-3, 4-4; figure 4-1)
4. a (paraa 4-3a(1), b)
5. c (para 4-3b(1))
6. d (para 4-3a(2); figure 4-6)
7. a (para 4-1b)
8. OKAY
9. OKAY
10. Patient ID block: SSN missing
11. OKAY
12. OKAY
13. Ward/clinic missing
14. Exam request block inconsistent with specific reasons for request block
15. OKAY
16. See 15 above
17. Signature of requestor block not signed by requesting physician.
18. Signature of requestor block not signed by requesting physician.

## Section II: FILM IDENTIFICATION

### 4-10. PROJECTION

a. As stated earlier, what you do in the exposure and processing room is the heart of your job as a radiographer since your job is to demonstrate pathology radiographically. However, the importance of proper film identification cannot be overly stressed. There is no situation in which proper film identification is unimportant. What is the good of a clearly demonstrated anatomical structure if it has been mislabeled? Mislabeled anatomical structures, such as the right lung for the left lung, can lead to a failure to treat a diseased lung and unnecessary intervention on a healthy lung. If an incorrect family member prefix is entered on an X-ray, for example, 01 for 02, the radiologist's report will incorrectly attribute a condition to the wrong sibling. Film identification is always important, but it becomes particularly important in comparison studies on follow-up examinations and in malpractice suits where compensation for injury and damages is at stake.

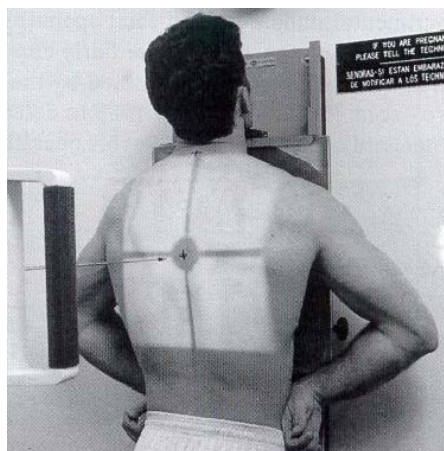
b. If, for example, the growth of a cancerous lesion is being compared from one week to the next, an accurate date becomes a crucial identifying factor and assessment tool. For such an examination, the cumulative time following injection of the contrast medium (for example, 5 minutes post injection) would be required. The age of the patient is also crucial in comparison studies that attempt to measure the progress of a disease since certain diseases travel faster depending upon the age of the patient. In tomography, the level of the fulcrum (for example, 8 cm--see figure 4-20) would be required. Other X-rays may be marked to indicate the patient's bodily position (for example, prone or decubitus). Local standard operating procedure (SOP) may also require other identifiers. As with all components of the medical record, film identification represents medical and legal documentation of the actions taken. Thus, this aspect of the job (patient and film identification) should never be taken lightly or done absent-mindedly.

#### **THE CASE OF THE INCORRECTLY LABELLED X-RAYS**

A 6-month old infant is admitted to the hospital for a bad cold. The attending physician, listening with her stethoscope, detects heavy congestion in the left lung. Based on the preliminary exam, she fills out an X-ray request slip requesting chest X-rays. The radiographer picks up the request, verifies the entries, and proceeds to label the film. Now, the technologist is used to seeing adult patients at a vertical chest X-ray unit leaning with the chest against the X-ray film cassette. In this position, the adult patient's left lung is demonstrated on the left side of the film. Infants, less frequent candidates for chest exams, must be handled differently due to their size. These pint-sized patients must be placed in the supine position, lying face up on the X-ray film cassette. In this position, the left lung is, of course, demonstrated on the right side of the film. The X-ray technologist, forgetting that the baby's body is reversed from the customary orientation, inadvertently marks an "R" on the upper right-hand side of the film, which, in fact, corresponds to the infant's left lung. Based on the inaccurately labeled X-rays, the healthy lung is treated and the ailing lung is left unattended. The baby dies. The parents sue the hospital, the attending physician, and the radiologist. The X-ray technologist is no longer trusted to the same extent as before, by his supervisor. The unnecessary death; the adverse publicity for the hospital and the health care team; the cost in terms of time, money and stress; and erosion of morale are all directly attributable to one incorrectly placed L or R (see figures 4-21 and 4-22).

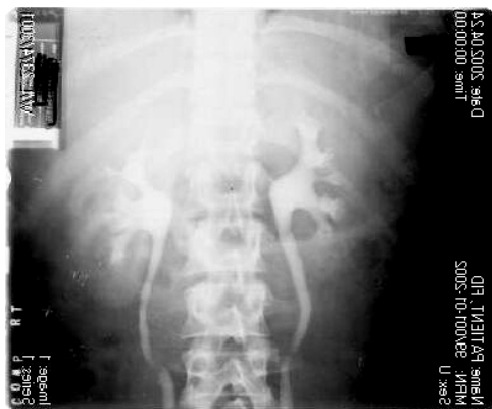


Figure 4-20. In tomography, the level of the fulcrum (for example, 8 cm) would be required film identification.



CORRECTLY LABELLED RADIOGRAPH

Figure 4-21. In this position, the adult's right lung is demonstrated on the right side of the film.



INCORRECTLY LABELLED RADIOGRAPH

Figure 4-22. In thus position, the placement of the right letter marker is incorrect.

## 4-11. A FILM IDENTIFICATION SYSTEM

a. The radiology department must have effective film identification and marking system if it is to provide X-rays that are accurate and useful to the radiologists who need them. Film must be accurately identified with the appropriate patient and clinic. The right and left sides of the radiograph as well as other necessary information must be indicated on the film.

b. Figure 4-23 shows the minimum required identifying information. Note that the patient's name, sex, and age are entered on the first line. On the second line is the family prefix plus the social security number. On the third line is the data the X-ray was taken. On the fourth line is the institutional identity. Also placed lower down on the film is the identifying marker (L or R) used to provide positional orientation.

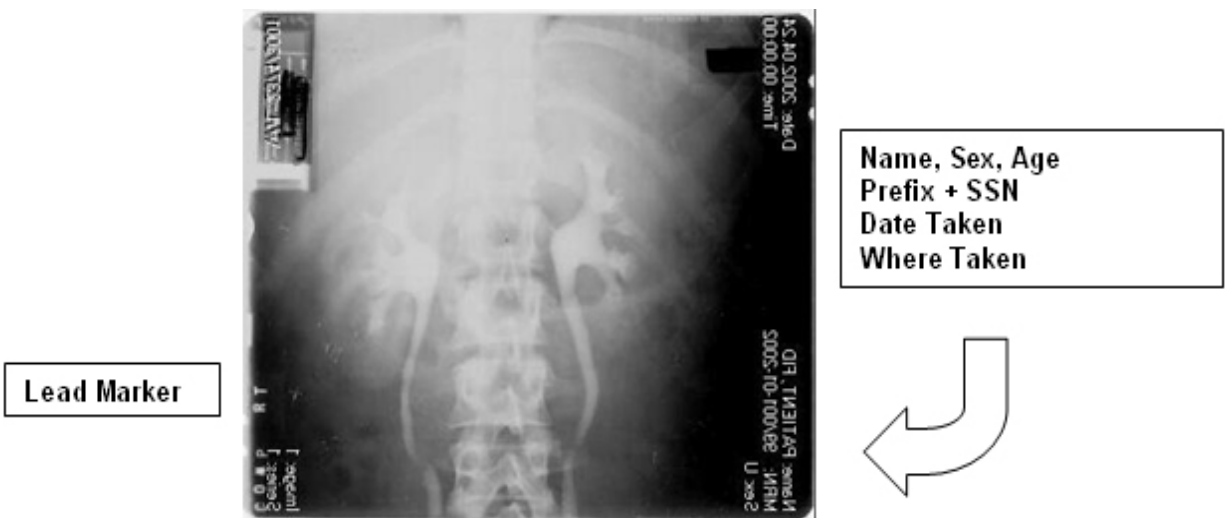

Figure 4-23. Minimum required permanent film identification

## 4-12. FILM IDENTIFICATION SYSTEMS

a. **X-ray Exposure (Direct) Method.** Numerous methods of marking film for identification are available. In the direct method, the identifying information is placed directly on the film and radiographed as the X-ray is taken.

b. **Flashing/Light Method.** The identifying information may also be recorded by flashing it onto the film in the darkroom or the examination room before development. This method, known as the flashing or light method, is the one most commonly used today. It involves writing or typing the identifying data on a three-by-five-inch card (figure 4-24) and then flashing (photographing) the information onto an unexposed portion of film.



Name _____	AGE _____
SSN _____	STATUS _____

NAME _____	
SSN _____	
STATUS _____	DATE _____
PROCEDURE _____	
HOSP. _____	

Flash Card

Figure 4-24. For the flashing method, identifying information is first placed on a three-by-five card.

c. **Lead Marker.** Another method of film identification is to assemble all the information on an aluminum tab or strip using lead numerals and letters. The tabs or strips are then taped to the cassette before exposure. (In this case, a number rather than his full name usually identifies the patient.) This method is used in the field. The lead marker is used to identify the corresponding side or area being demonstrated. It consists of an R or an L and a technologists's identification (I.D.) number or initials (figures 4-25 and 4-26). Other lead markers may be needed for certain procedures (time interval, uptight, with/without weights, and open/closed lead markers). An example is shown in figure 4-27.

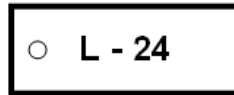


Figure 4-25. The lead marker, about the size of a razor blade, has a left LM and the technologist's number for accountability purposes.




Figure 4-26. An R for the LM and the technologist's initials (AD) are entered on this lead marker.

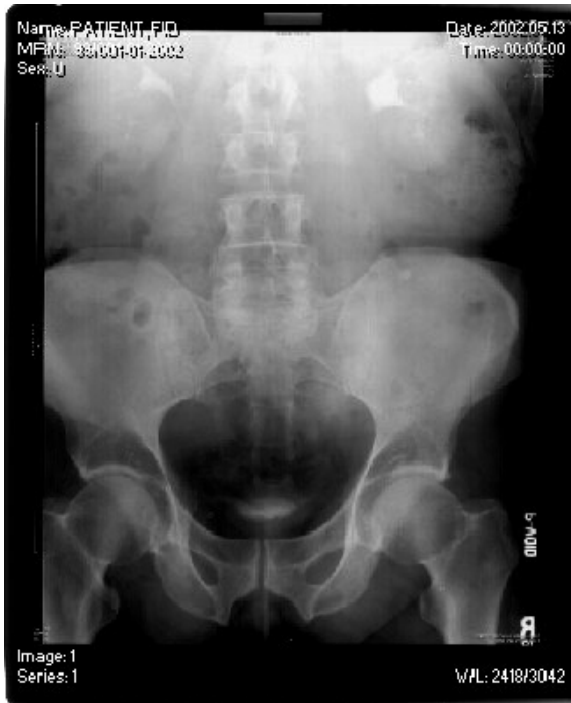

Figure 4-27. An IVP with lead-time interval (15 min), patient I.D., and LM (R).

#### 4-13. RULES FOR DETERMINING THE PROPER LETTER MARKER

a. **The Extremities.** Without an L or an R marker the radiologist would not know which foot he or she was looking at. Therefore, the appropriate marker must be placed on the film before you take the exposure. Figure 4-28 shows a letter marker (R).

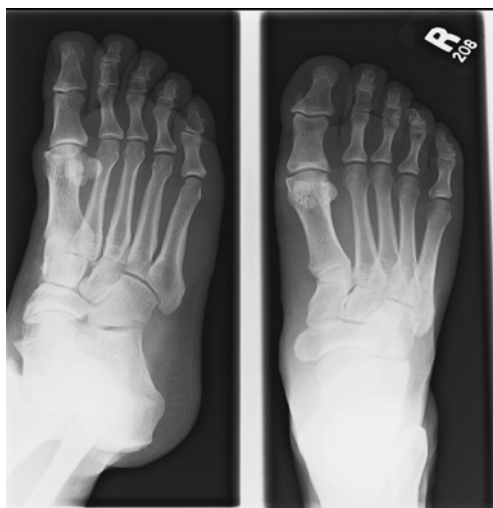

Figure 4-28. The appropriate LM of the corresponding part (in this case, an R) is placed on the cassette.

b. **Anteroposterio/posteroanterior Trunk and Skull.** For an anteroposterior (AP) or posteroanterior (PA) projection, the "R" or "L" marker should be placed on the corresponding side of the film cassette. See figures 4-29, 4-30, and 4-31.

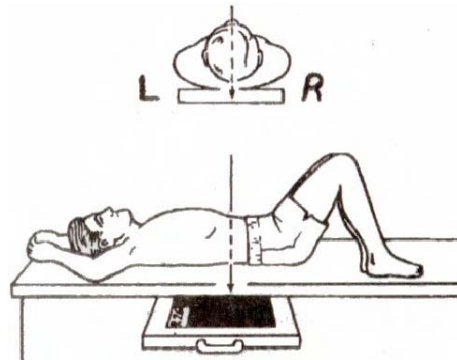


Figure 4-29. The R corresponds to side of body demonstrated on that side of the film.

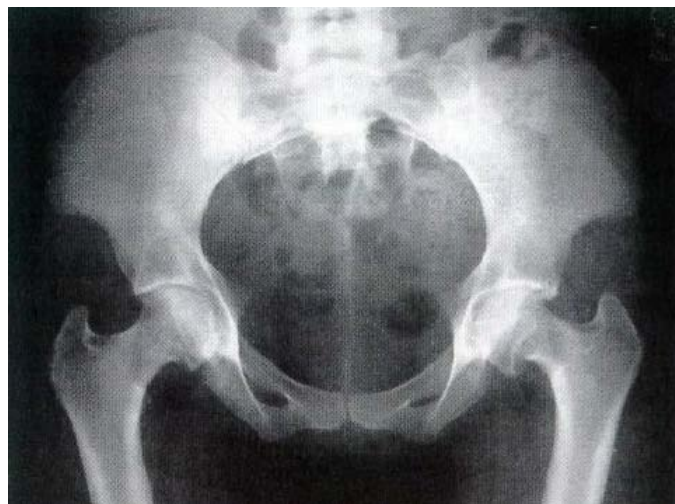

Figure 4-30. Full field coverage is demonstrated here. Either letter marker could be used, as long as it is placed with the corresponding side.

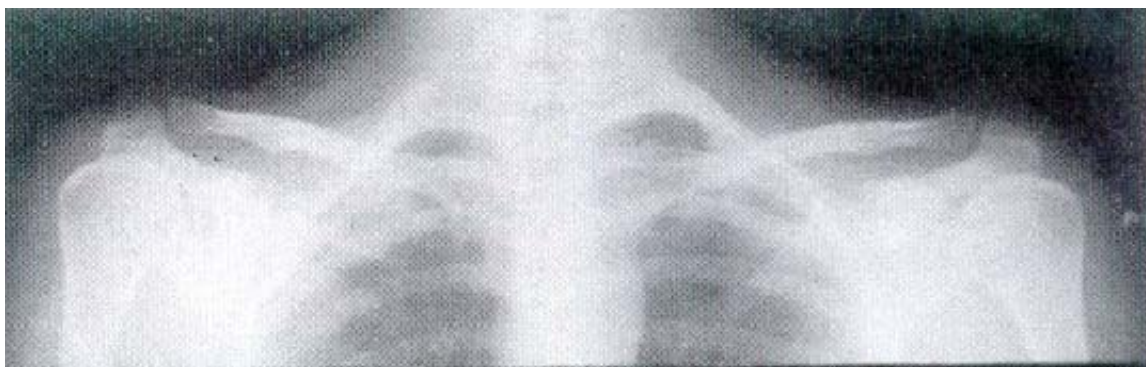

Figure 4-31. Either the R or L marker could be used in labeling the AP view of the acromioclavicular joints.

c. **Oblique Trunk Positions.** For full field coverage (FFC) obliques, the marker corresponds to the side of the body. For oblique projections, the technologist must first decide whether to do a FFC radiograph or a restricted cone field (CF) radiograph. In an FFC, the central ray is not coned down so that the entire film is exposed. In a restricted CF, the CR is coned down so that only a portion of the film is exposed. The requesting physician might, for example, request a hip series, in which case it would be up to you to determine if you are going to do a full pelvis or a right or left AP hip depending on the entry in the reasons requested block. (In some cases, of course, the physician might specifically request both views.) Once you have determined which views to take, you will have to prepare the film accordingly with the correct letter marker(s). For the pelvis view, which is FFC, both hips will appear in the radiograph. For an FFC, the letter marker must correspond to the side of the body. Thus, you could label the film with either the L marker near the position on the film corresponding to the place where the left hip will be visualized. Or, you could use the R marker, in which case, you would place it near the portion of the film where the right hip will be visualized. (You don't need to place both markers on the film because one identifier suffices to provide the positional orientation for both sides of the image.)

d. **Oblique Trunks (Restricted Conefield ).** For an oblique trunk with a restricted entered, the letter marker corresponds to the part demonstrated (figure 4-32). In an AP hip, a restricted CF radiograph, the collimator is coned down to demonstrate only one hip. Therefore, the LM you select to identify the film must correspond to the hip being demonstrated: R for the right hip or L for the left hip. You cannot use either marker, as for a FFC radiograph (that is, using an L to indicate the left side of the right hip). If the right hip is visualized in a restricted CF, you must use the R. If you mislabeled a right hip radiograph with an L, you would mislead the radiologist and quite possibly compromise the patient's treatment.

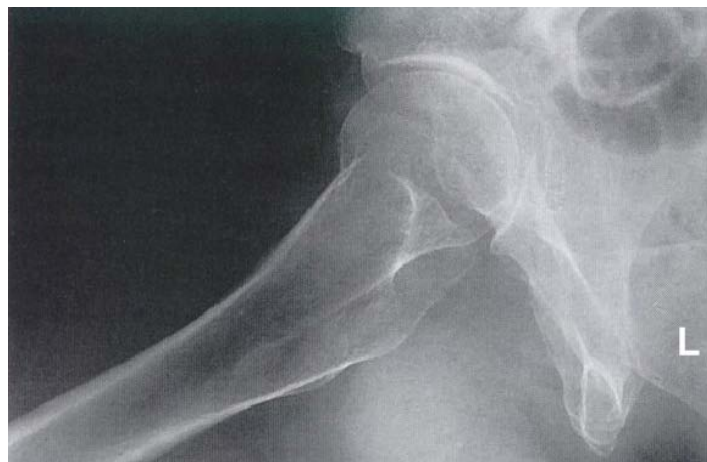

Figure 4-32. In his AP hip with a restricted CF, the letter marker (L) corresponds to the hip being demonstrated.

e. **Oblique Trunk and Skull Positions.** When labeling film for an oblique trunk or skull projection (figures 4-33 through 4-36), make sure that you label the side of the body or the part that is of clinical interest. As stated earlier, for an FFC oblique, the letter mark should correspond to the side of the body being demonstrated. For a restricted CF oblique, the letter marker should correspond to the part being demonstrated.

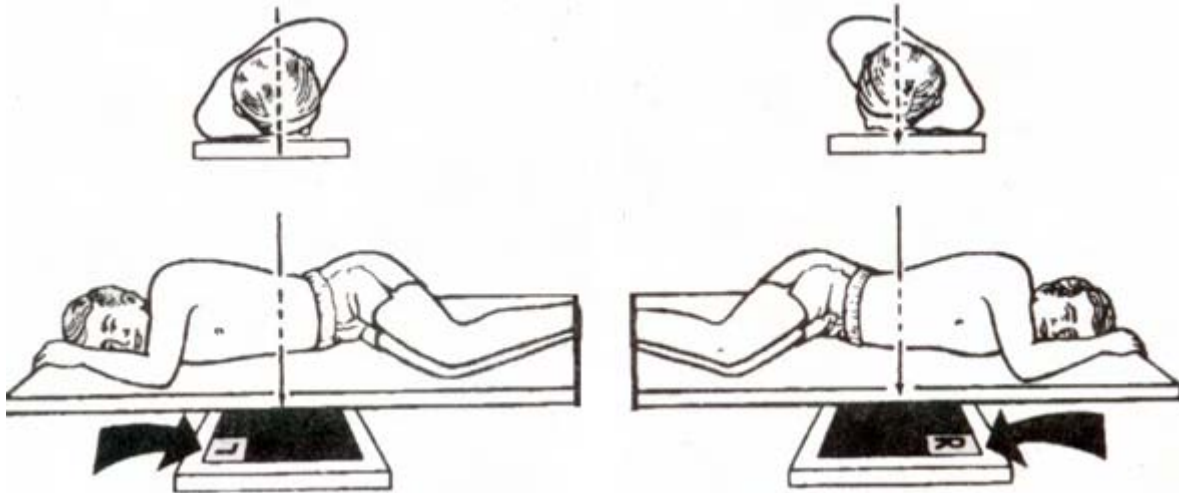


Figure 4-33. Both letter markers (LMs) have been used in these two different views, demonstrating appropriate placement of the LM.

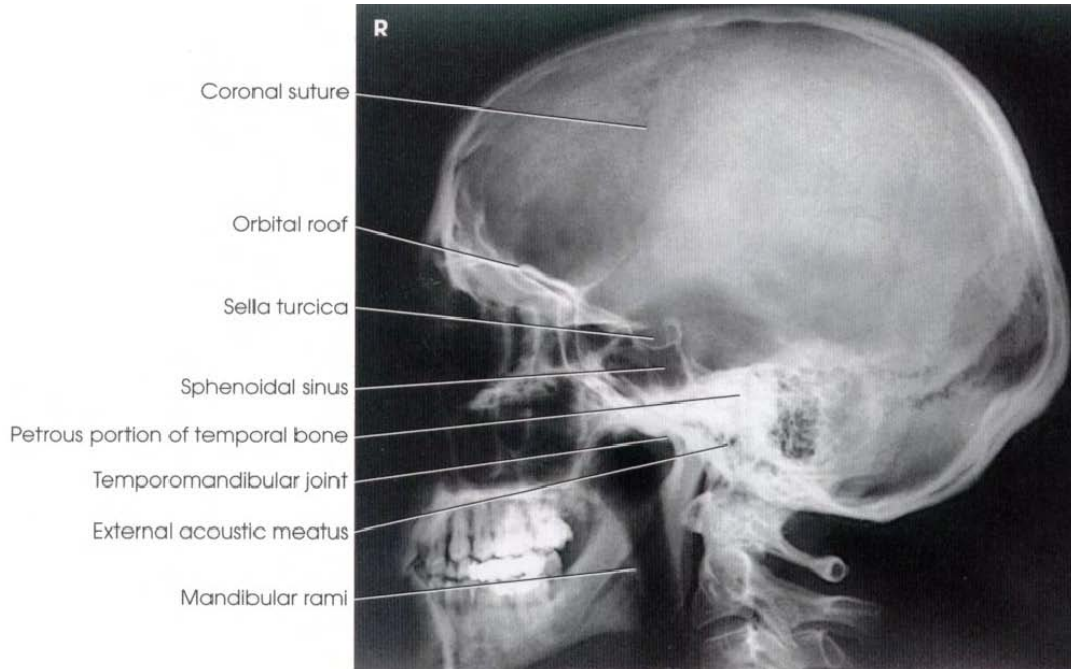


Figure 4-34. A lateral (lat.) skull projection with a restricted CF the letter marker corresponds to the part being demonstrated (side down).

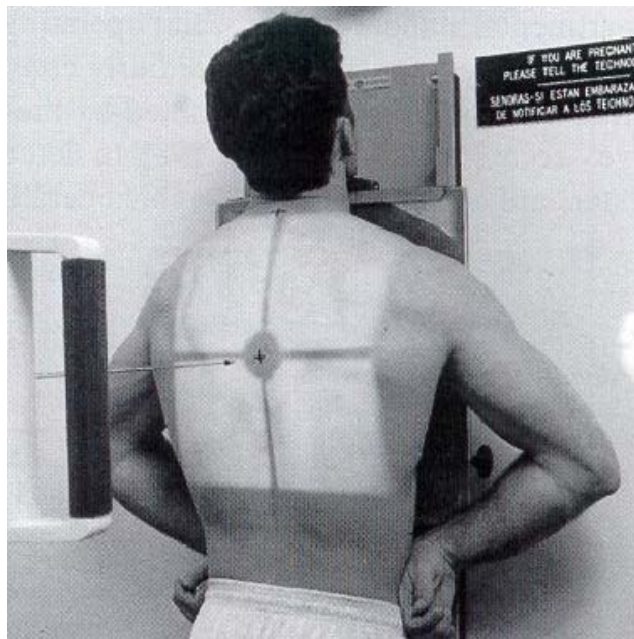


Figure 4-35. In which corner of the insert (box) would an "L" LM go?

You were right if you said that the L belonged in the upper left-hand corner.

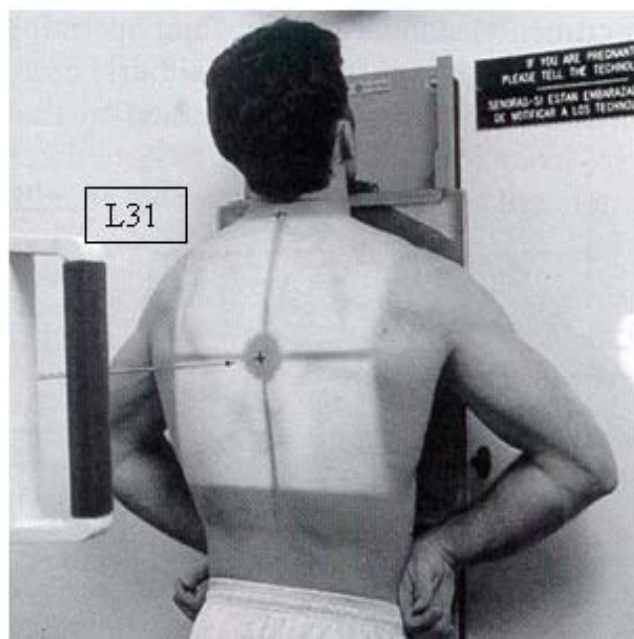


Figure 4-36. The left LM (L31) is placed in the upper left-hand corner of film.

f. **Measuring the Conefield.** The letter marker provides an essential piece of identifying information. You should place the LM within the restricted cone field. If it is placed far outside the area of exposure, it is likely not to be picked up by the ionizing radiation (figure 4-37). (Scatter radiation may or may not pick it up). If, on the other hand, it is placed too far in on the film, you may end up obscuring the very anatomical structure that needs to be visualized (figure 4-38). Therefore, you must know where on the film to place the letter marker. Proper placement of the letter marker becomes especially critical when preparing film for a restricted cone field (CF) radiograph. When placing the letter marker for a restricted cone field radiograph, some simple measuring techniques will ensure that the letter marker for a restricted cone field is appropriately placed. For a restricted six-inch cone field, position the blank film cassette. Then, turn the collimator on. Cone down to the desired six inches. Locate the center of the cone field (the spot where the crisscross shadow falls). Measure out three inches from the center (figure 4-39). Place the letter marker just within the 3-inch margin. Remember that placing it beyond the 3-inch mark will place it outside the area of exposure. Placing R well within the 3-inch margin means you risk obscuring the body part to be demonstrated. For an X-ray with an eight-inch restricted cone field, measure out four inches from the center (figure 4-40) and place the letter marker just within the 4-inch marker.

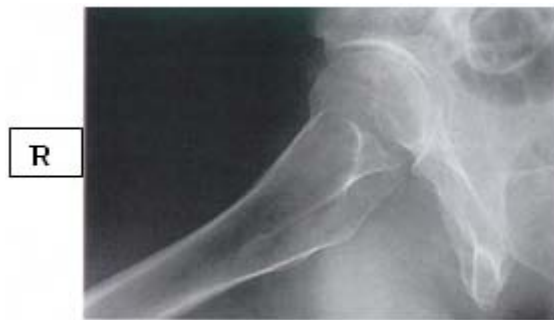

Figure 4-37. If the LM is outside the area on a restricted CF, the LM may not be exposed the film.

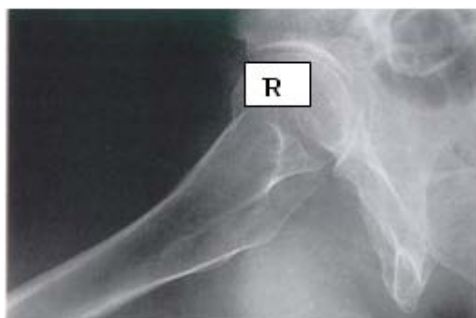


Figure 4-38. Letter markers placed within area of exposure, but without obscuring anatomical structure.



Figure 4-39. Measuring six-inch restricted CF so LM is within three inches from the center.



Figure 4-40. Measuring eight-inch restricted CF so LM is within four inches from the center.

g. **Lateral Trunk or Skull.** Lateral views are the only views for which the letter marker corresponds to the body part closest to the film. Thus, in figure 4-41 below, the L on the radiograph reflects that the left side of the patient's body is closest to the film.

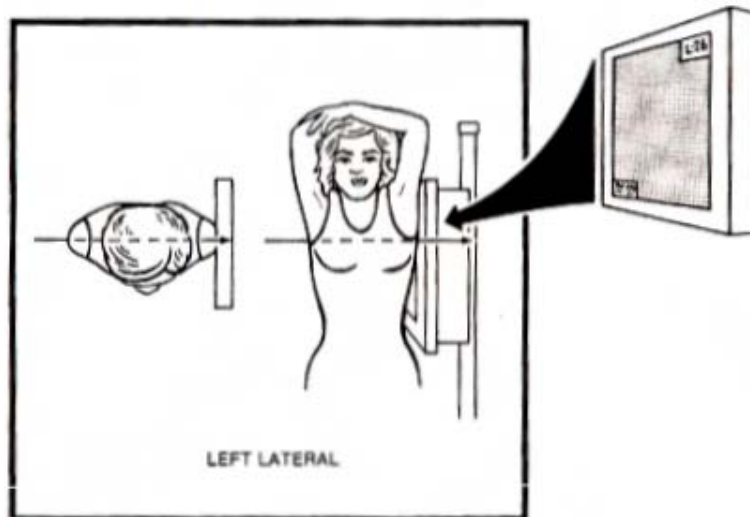


Figure 4-41. The L indicates that the left side of the body, the side nearest the film, is being demonstrated.

**Continue with Exercises**



## EXERCISES, LESSON 4, SECTION II

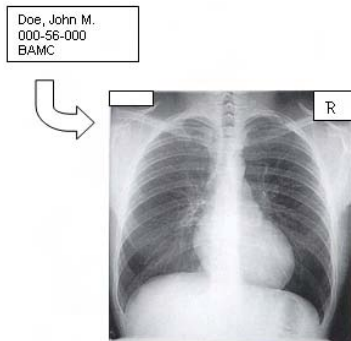
**MULTIPLE CHOICE.** FOR exercises 1 through 6, select the ONE word or phrase that BEST completes the statement or BEST answers the question.

1. For which of the following is accurate film Identification important?
  - a. Every radiograph you take.
  - b. Comparison studies for the rate of growth of a cancerous lesion.
  - c. Intravenous pyelograms.
  - d. Radiographs involving a failure to diagnose a bone tumor.
  
2. Which of the following is one of the most commonly used methods of film identification in the military?
  - a. The direct/exposure method.
  - b. The flashing/light method.
  - c. The lead marker method.
  - d. The perforation method.
  
3. Which method is often used when several films are being taken on a patient in which time intervals must be indicated?
  - a. The direct/exposure method.
  - b. The flashing/light method.
  - c. The specialty cassette marking method.
  - d. The lead marker method.

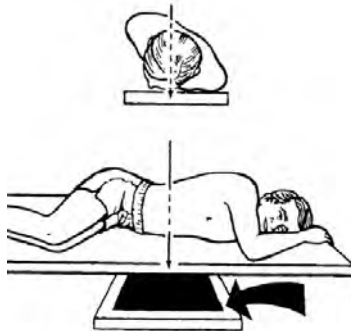
4. If you are doing a six-inch cone field (CF) radiograph, the letter marker should be placed just within \_\_\_\_\_ from the center.
  - a. 3 inches.
  - b. 4 inches.
  - c. 6 inches.
  - d. 8 inches.
  
5. If you are doing an eight-inch cone field (CF), the letter marker should be placed just within \_\_\_\_\_ from the center.
  - a. 3 inches.
  - b. 4 inches.
  - c. 6 inches.
  - d. 8 inches.
  
6. You are doing a six-inch restricted cone field of the right wrist. What letter marker should you use and where on the film should the LM be placed?
  - a. Left letter marker, 1 inch from the edge of the film.
  - b. Right letter marker, just inside the border of the film.
  - c. Right letter marker, 3 inches from the border of the film.
  - d. Right letter marker, just within 3 inches from the center of the film.

**IDENTIFICATION.** For exercises 7 through 13, evaluate the figure in order to identify the inaccuracy or answer the question, as appropriate. Enter your response in the space provided when you have completed all of the exercises to your satisfaction.

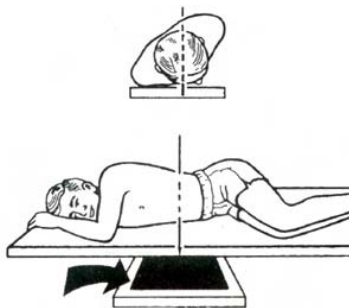
7. What is wrong with or missing from the film identification for the chest X-ray of SFC Doe shown below? Cross out the incorrect entries and make corrections, as needed.



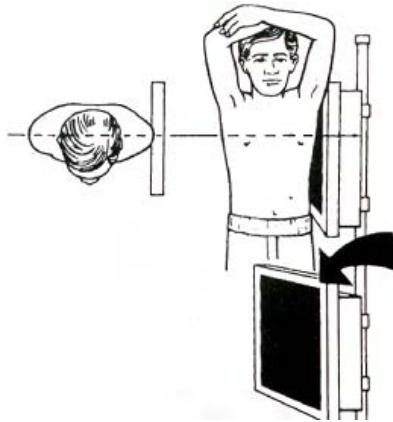
8. For the oblique projection shown, enter an R on the appropriate location of the film in the Bucky tray.



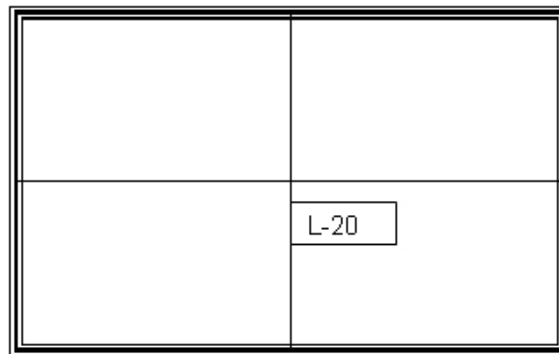
9. For the oblique projection shown below, enter an L in the appropriate place on the film.



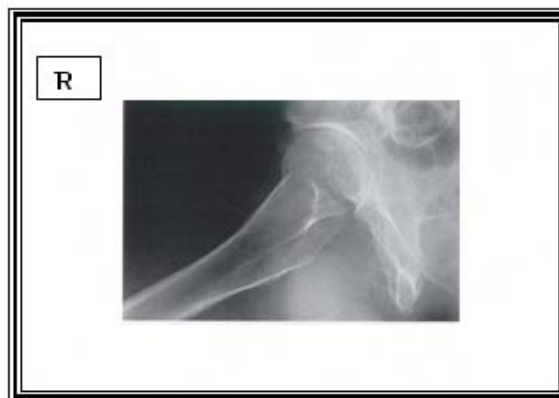
10. Enter the appropriate letter marker (where indicated by the arrow) for the lateral projection shown below.



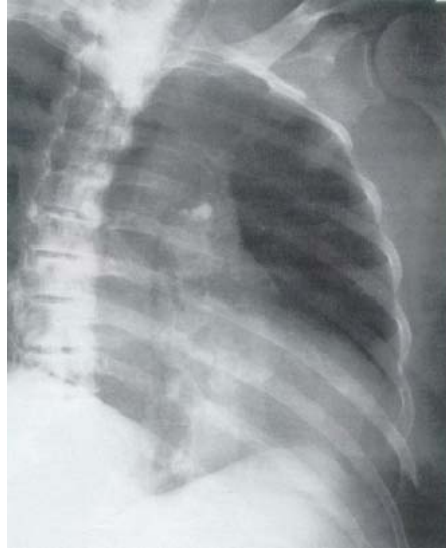
11. Consider the placement of the letter marker in this 6-inch restricted cone field. What is the likely outcome in terms of clear identification?



12. Consider the placement of the letter marker in this 8-inch restricted cone field. What is the likely outcome?



13. You are doing an RPO view of the ribs above the diaphragm with full field coverage. Decide where you would place the appropriate letter marker so that it corresponds with the side of the body of anatomical interest.



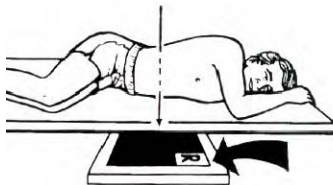
**Check Your Answers on Next Page**

## SOLUTIONS, LESSON 4, SECTION II

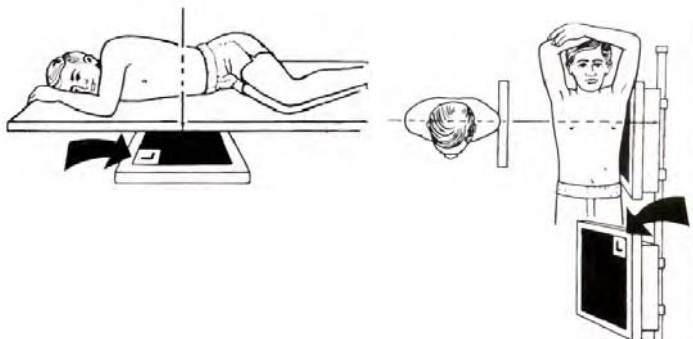
Be sure to re-read and study the paragraph(s) pertaining to any exercises you might have answered incorrectly. The relevant paragraph(s) is (are) listed after each of the answers below.

1. a (para 4-10a)
2. b (para 4-12b)
3. d (para 4-12c)
4. a (para 4-13f, figure 4-39)
5. b (para 4-13f, figure 4-40)
6. d (paras 4-13a, d, f)
7. Wrong letter marker. (In AP or PA, marker corresponds to side of body demonstrated in that part of the film.  
Age missing. Family member prefix missing. Date of X- ray missing. (para 4-11)

8. (para 4-13e, figure 4-33)

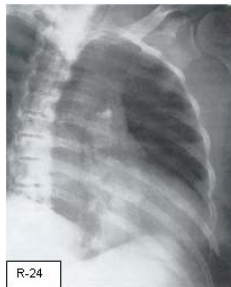

9. (para 4-13e, figure 4-33)



10. (para 4-13g, figure 4-36)

11. The anatomical part of clinical interest is likely to be obstructed by this placement of the letter marker. (para 4-13f, figure 3-38)
12. The letter marker won't show up on the film, because it is outside the portion of the film to be exposed to ionizing radiation. (para 4-13f, figure 4-37)
13. (para 4-13e)



**End of Lesson 4**

## LESSON ASSIGNMENT

### LESSON 5

Positioning for Exams of the Upper Extremities.

### LESSON ASSIGNMENT

Paragraphs 5-1 through 5-25.

### LESSON OBJECTIVES

After completing this lesson, you should be able to:

- 5-1. Identify specifications for proper placement of the anatomical structure of the upper extremities, listed below:
  - Hand (PA, oblique, lateral).
  - Wrist (lateral, PA with ulnar flexion)
  - Forearm (AP & lateral).
  - Elbow (AP & lateral).
  - Humerus (AP & lateral).
  - Shoulder (AP with external rotation, AP with internal rotation, inferiorsuperior axial projection).
  - Scapula (AP & lateral).
  - Acromioclavicular joints (with & without weights).

### SUGGESTION

After reading and studying the assignment, complete the exercises at the end of this lesson. These exercises will help you to achieve the lesson objectives.

## LESSON 5

### POSITIONING FOR EXAMS OF THE UPPER EXTREMITIES

#### Section I. RADIOGRAPHIC PROJECTIONS OF THE HAND

##### 5-1. INTRODUCTION

a. **Lesson Format.** In this lesson, a group of related projections for the upper extremities will be presented. For each projection, two figures are provided (figure 5-1). The first depicts the *body part* that is of clinical interest, with labels naming the various parts of the anatomical structure; the second shows proper placement of the *patient*. Where feasible, the anatomical structure to be demonstrated is highlighted in gray in the labeled drawing. (A line drawing rather than a photograph of a radiograph was selected to ensure clarity of depiction.)

b. **Specifications (Order of Procedure).** Following the two figures is the order of procedure, a laundry list of specifications for the projection (figure 5-2). The laundry list consists of information essential to ensuring proper visualization of the body part. The information (specifications) provided for each position will always be presented in the same order, for ease of comparison. (See bottom inset, figure 5-1).

c. **Common information.** Some information common to a group of projections will be presented at the beginning of the lesson instead of being repeated over and over again for each position. In this lesson, for example, the information pertaining to the patient's dress will be presented at the outset; but this common information should be kept in mind as you proceed to read about each position.

d. **The Order of Procedure (Position Specification).** The information generally included in the laundry list (position specifications) is explained in figure 5-2. Note that items a, b, and c are the position specific or unique information is provided for these entries.

e. **How to Use This Material.** There are over 100 positions presented in MD0961, Standard Positioning Techniques I, and MD0962, Standard Positioning Techniques II. The majority are in MD0962, the sequel to this subcourse. Many of the specifications for the various positions are similar. Unless you zero in on the critical distinguishing features of each position, the information presented here can easily become muddled in your mind. You cannot memorize all the facts about these positions. What you can do is to learn the critical differences among positions. Don't let yourself feel overwhelmed. Instead, take one position at a time. (Relax and forget about all the other positions to be covered for the time being.)



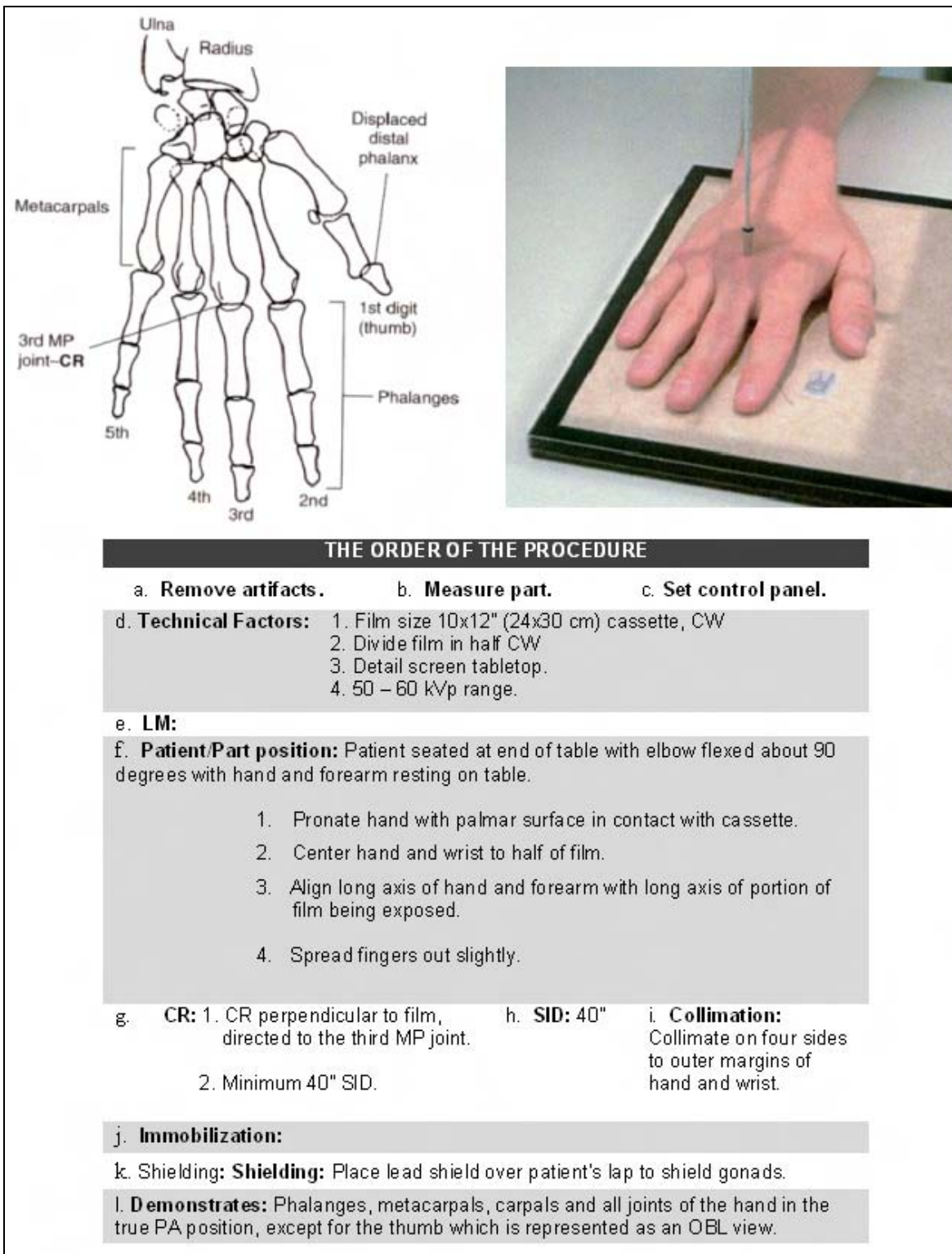


Figure 5-1. For each projection the anatomical structure (upper left), patient positioning (upper right), and specifications (order of procedure) are provided.

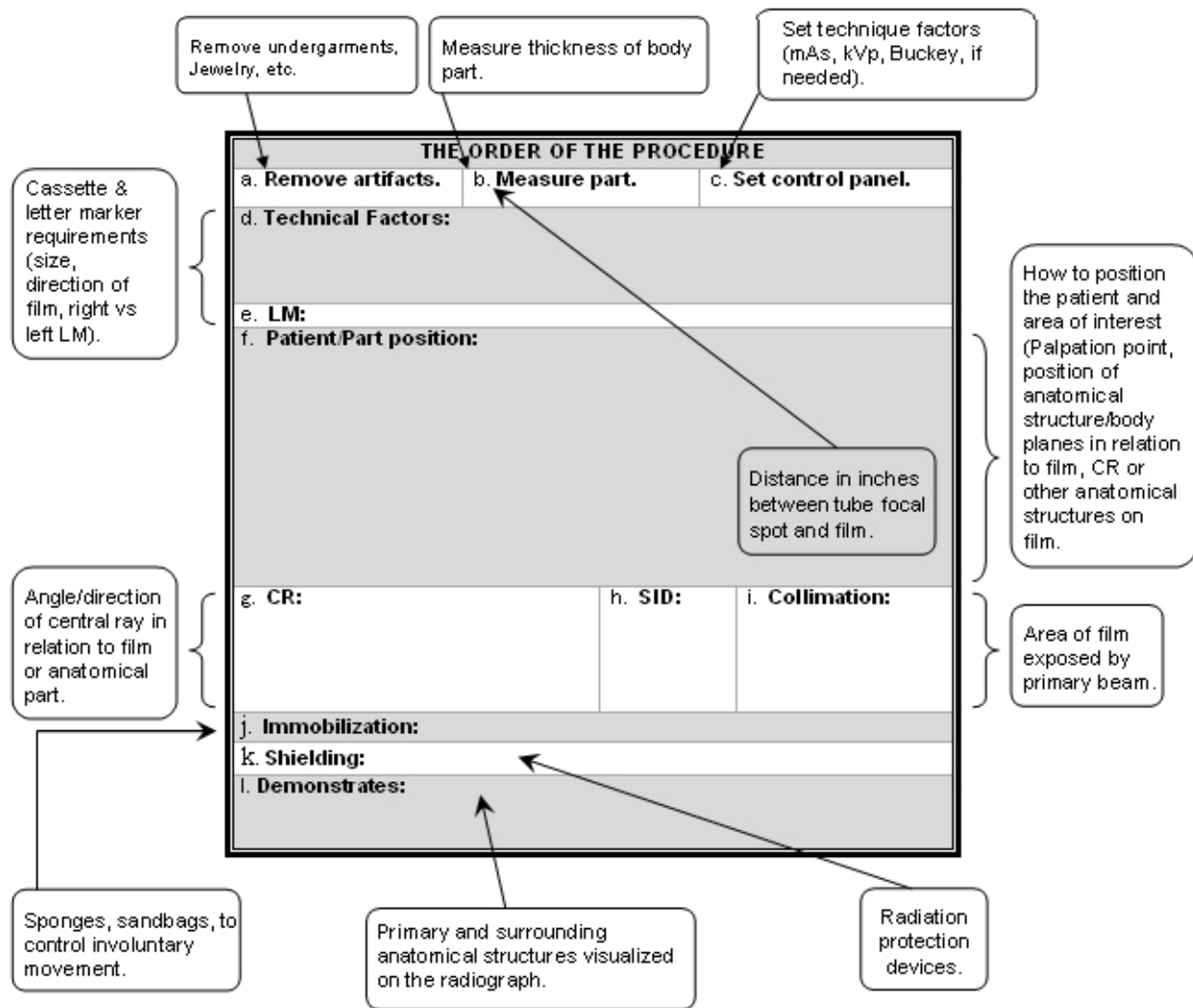


Figure 5-2. The standardized order of procedure information explained.

f. **Study Strategies.** Look over the illustrations, noting the general features of the position and the anatomical structures. Next, go over the list of specifications carefully. Approach it as you would a laundry or shopping list, ticking off the items in your mind as you proceed down the list. If you have studied this material before, try to recall what you have learned previously as you work your way down the list of specifications. After reading over the list a few times, cover the list with your hands, look at the illustration, and ask yourself, “Okay, what is the technical factors for this AP forearm?”

g. **More Study Strategies.** Now, go back to the illustrations and try to link up the *visual* information in the drawing with the *descriptive* information in the text (order of procedure/laundry list of specifications). Finally, zero in on and review several times, the two key elements of every position: the alignment or position to be assumed by the patient/ the part position reference (paragraph e) and the central ray (CR) (paragraph f). Once these essentials are fixed in your memory, the other details will fall into place more easily.

h. **The Order of Procedure (Position Specifications).** The information generally included in the order of procedure is explained in figure 5-2. Note that items a, b, c are the same for all positions. No position specific information is provided because it will depend on the anatomy to be demonstrated.

**5-2. PATIENT DRESS AND REMOVAL OF ARTIFACTS**

a. General information about patient dress and removal of artifacts is covered here instead of in the specifications for each position since these guidelines apply to all the positions in general (figure 5-3).

<b>PROJECTION</b>	<b>ARTIFACTS &amp; CLOTHING</b>
<b>Hand</b> .....	No wristwatches, bracelets, rings.
<b>Wrist/Forearm</b> .....	No wristwatches/bracelets; sleeves rolled up.
<b>Humerus</b> .....	Male patient stripped to waist.
<b>Chest</b> .....	Female patient –
	✓ No undergarments (shoulder to waist).
	✓ No necklaces or pendants.
	✓ Dons gown.
<b>Abdomen/Pelvis</b> .....	Removes undergarments (girdles), waist chains. Dons gown.
<b>Knee/Femur</b> .....	Removes pants, dons gown.

Figure 5-3. Artifacts/clothing to be removed (or donned).

b. In some cases, of course, it may not be desirable or possible to remove artifacts. If you receive a trauma patient wearing a cervical collar, for example, a necklace cannot be removed since removing it might cause further injury to the patient. Some artifacts cannot be removed. For example, if you are doing a skull series on a patient with a glass eye or an ear implant, the artifact cannot be removed. The same would apply for a hip prosthesis. In such cases, you would simply have to make accommodations, working around these potential obstacles. You will have to position the patient so that an unobstructed view may still be obtained.

### **5-3. MEASURING THE PART**

For each of the positions presented, step b of the order of procedure (figure 5-1, bottom) will simply indicate *measure the part*. Measuring the part means measuring the thickness of the body part in order to select the appropriate technique factors. You must measure the thickness of the body part from the point at which the central ray will enter up through the exit site of the CR. For a PA hand, for example, you would measure the thickness of the patient's hand from the posterior surface to the anterior surface through the head of the third metacarpal.

#### **MEASURING THE PART**

Measure the thickness of the body part from the point at which the central ray (CR) enters, up through the exit site of the CR.

### **5-4. SETTING THE CONTROL PANEL**

Step c of the order of procedure (figure 5-1, bottom) will simply have the entry, *set control panel*. (This has been covered in Lesson 2.) Essentially, setting the control panel means placing the correct technical factors, such as kVp and mAs on the control panel for the part being radiographed.

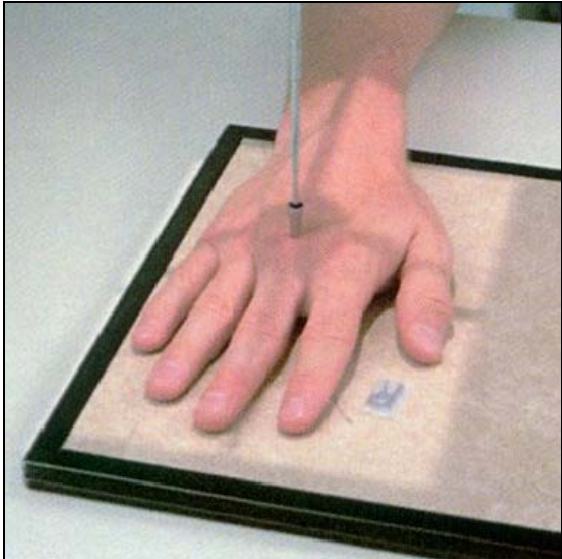
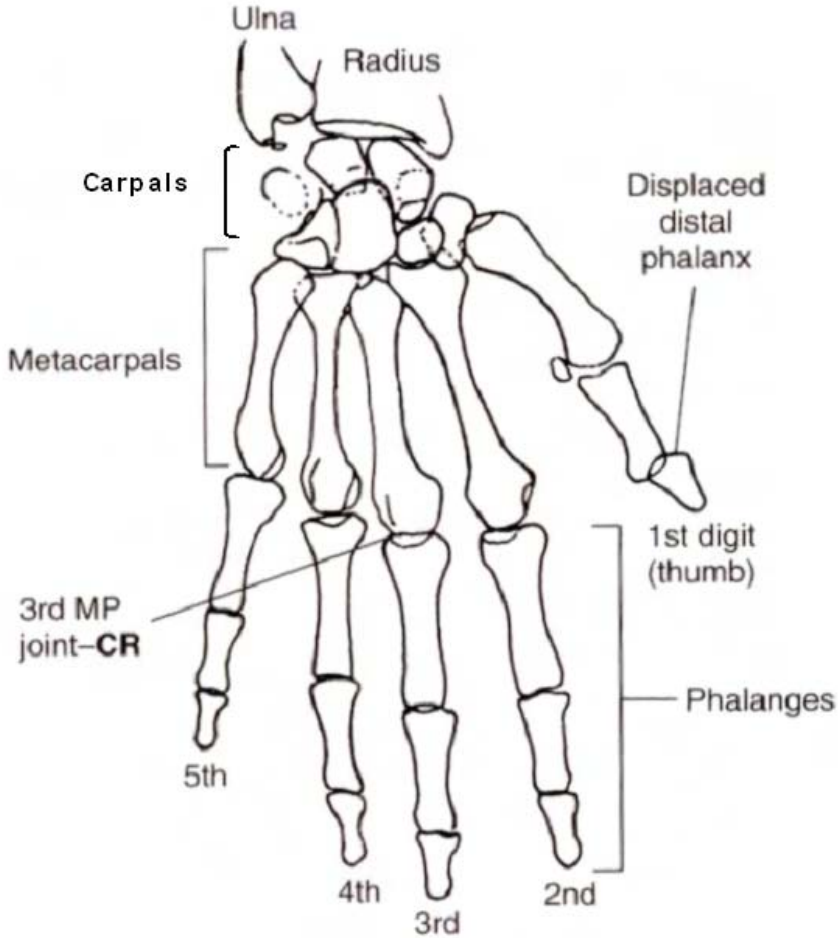
### **5-5. SOURCE TO IMAGE RECEPTOR DISTANCE**

Set the source to image receptor distance as indicated in item h of the order of procedure (figure 5-1, bottom).

#### **SOURCE TO IMAGE RECEPTOR DISTANCE (SID)**

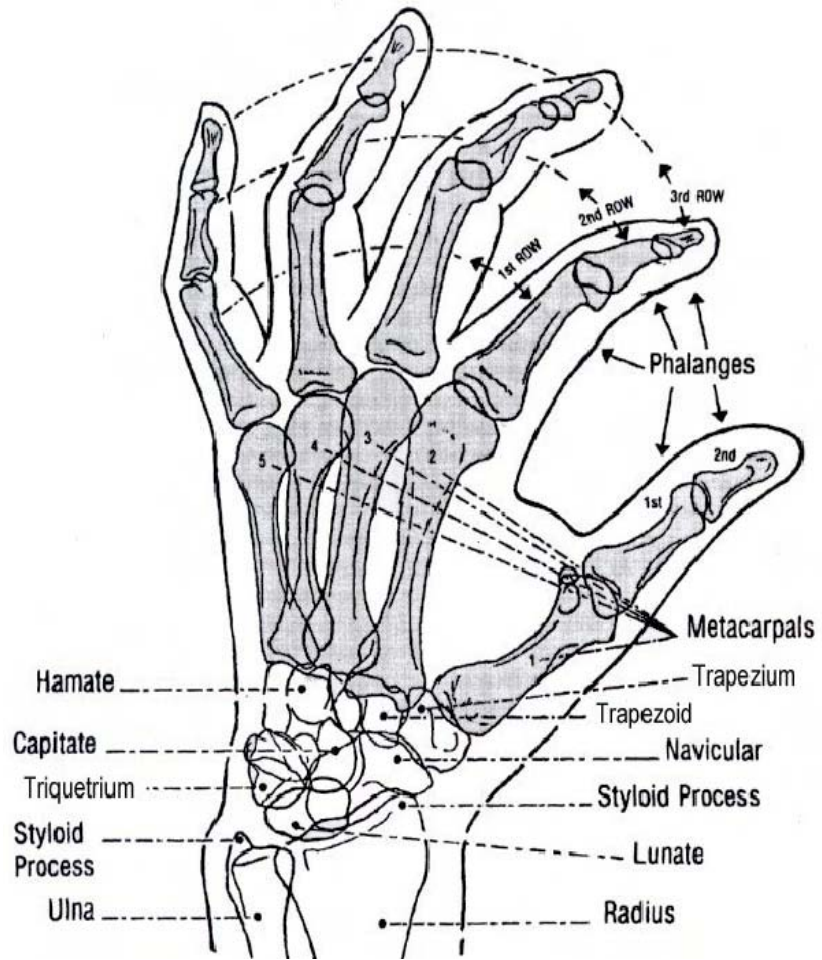
The SID is measured either to the tabletop or to the Bucky

5-6. POSTEROANTERIO HAND





5-7. OBLIQUE HAND



## THE ORDER OF THE PROCEDURE

a. **Remove artifacts.**

b. **Measure part.**

c. **Set control panel.**

d. **Technical Factors: Film size:**

1. 10 x 12" (24 x 30 cm) cassette, CW.
2. Divide film in half CW.
3. Detail screen tabletop
4. 50-60KVP range

e. **LM:**

f. **Patient/Part position:** Patient seated at end of table with elbow flexed about 90 degrees with hand and forearm resting on table.

1. Pronate hand on cassette and align long axis of hand and forearm to long axis of portion of film being exposed.
2. Center hand and wrist to half of film.
3. Rotate entire hand and wrist laterally 45 degrees and support with a radiolucent wedge or step block as shown so all digits are separated and parallel to film.

g. **CR:** perpendicular to film, directed to the **second MP** joint.

h. **SID:**  
Minimum  
40"

i. **Collimation:** Collimate on four sides to outer margins of hand and wrist.

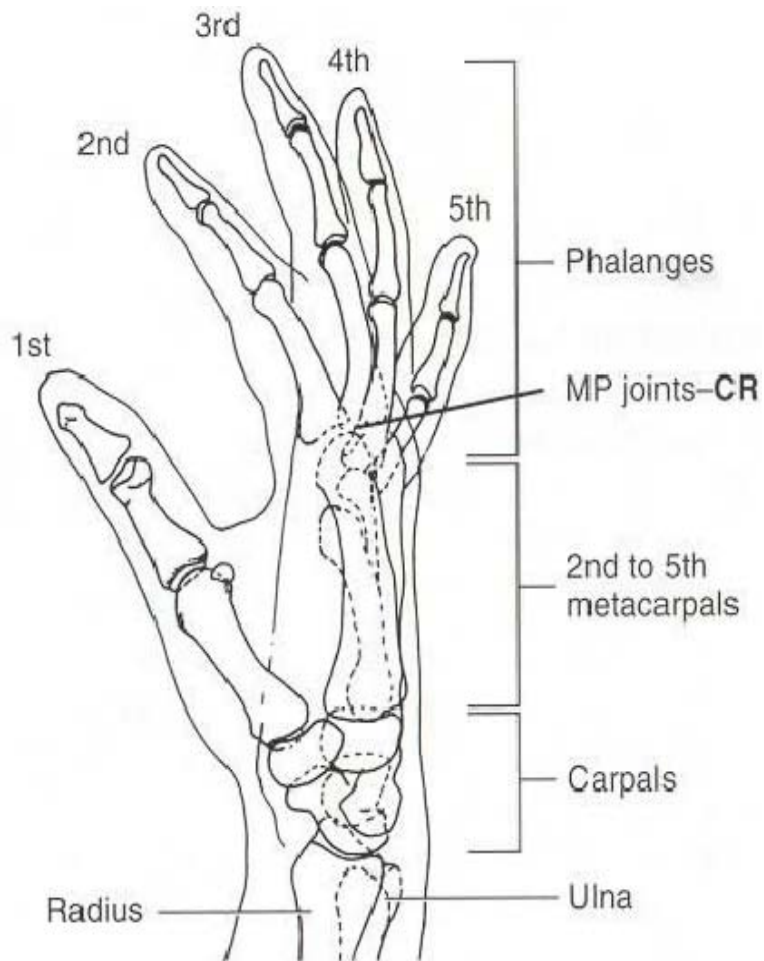
j. **Immobilization:**

k. **Shielding:** Place lead shield over patient's lap to shield gonads.

l. **Demonstrates:** Phalanges, metacarpals, carpals and all joints in the OBL position.



## 5-8. LATERAL HAND



## THE ORDER OF THE PROCEDURE

- a. **Remove artifacts.**      b. **Measure part.**      c. **Set control panel.**

c. **Technical Factors:** 1. Film size: 8 x 10" (18 x 24 cm) cassette, LW.  
2. Detail screen, tabletop.  
3. 54 - 64 kVp range.

d. **LM:**

e. **Patient/Part position:** Patient seated at end of table with elbow flexed about 90 degrees with hand and forearm resting on table.

1. Align long axis of hand and forearm to long axis of film with center of film to MP joints.
2. Rotate hand and wrist into lateral position with thumb side up.
3. Spread fingers and thumb into a "fan" position and support each digit on radiolucent step block as shown (see page 120 of Bontrager). Ensure all digits including thumb are parallel to film and that the metacarpals are not oblique but remain in the true LAT position.

f. **CR:** CR perpendicular to film, directed to the 2<sup>nd</sup> MP joint.      g. **SID:** Minimum 40"      h. **Collimation:** Collimate on four sides to outer margins of hand and wrist.

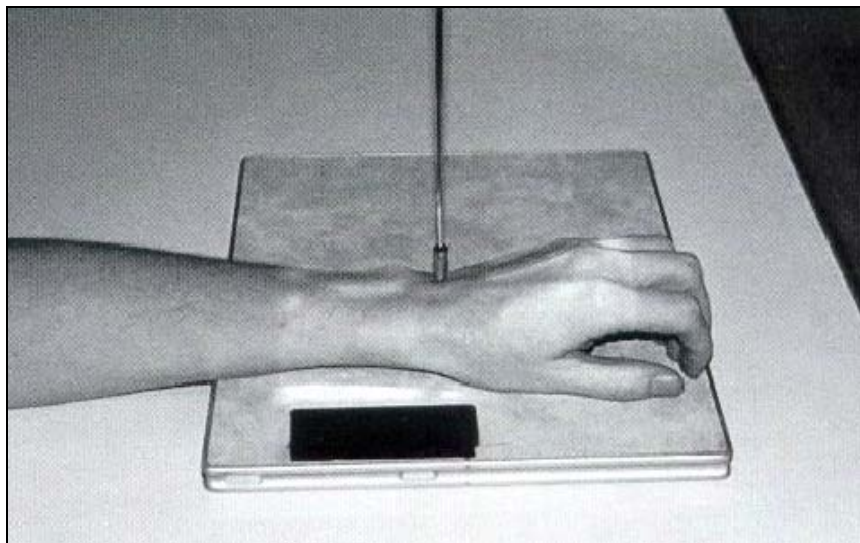
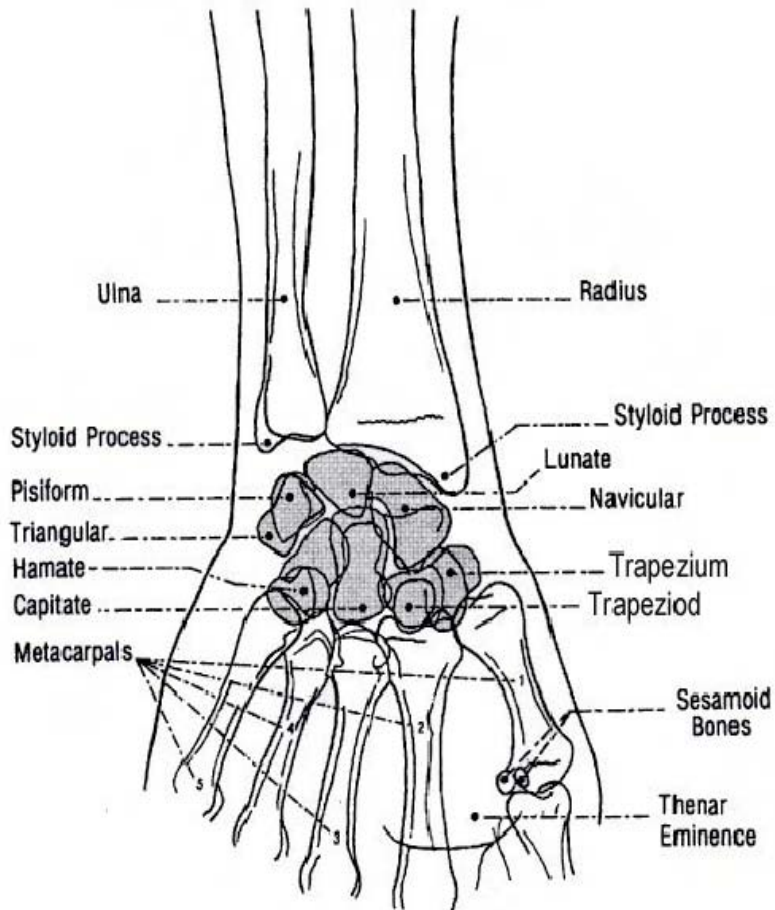
i. **Immobilization:**

j. **Shielding:** Place lead shield over patient's lap to shield gonads.

k. **Demonstrates:** Phalanges, metacarpals and carpals superimposed in a LAT position, except for the thumb, which is shown in the true PA projection.

## Section II. THE WRIST AND FOREARM

### 5-9. POSTERANTERIOR WRIST



## THE ORDER OF THE PROCEDURE

a. **Remove artifacts.**

b. **Measure part.**

c. **Set control panel.**

d. **Technical Factors:** Film size-10 x 12" (24 x 30 cm) crosswise

1. Divide film in half crosswise
1. Detail screen table top
2. 60 kVp range

e. **LM:**

f. **Patient/Part position:** Patient seated at end of table with elbow flexed about 90 degrees with hand and wrist resting on cassette, palm down.

1. Drop shoulder or raise table height so shoulder, elbow and wrist are on the same horizontal plane.
2. Align long axis of hand and forearm to center of the long axis of the unmasked half of the cassette, with carpal area to center of unmasked film.
3. With hand pronated, slightly clench fist to place wrist and carpal area in close contact with cassette.

g. **CR:** CR perpendicular to film, directed to mid carpal area.

h. **SID:**  
Minimum 40"

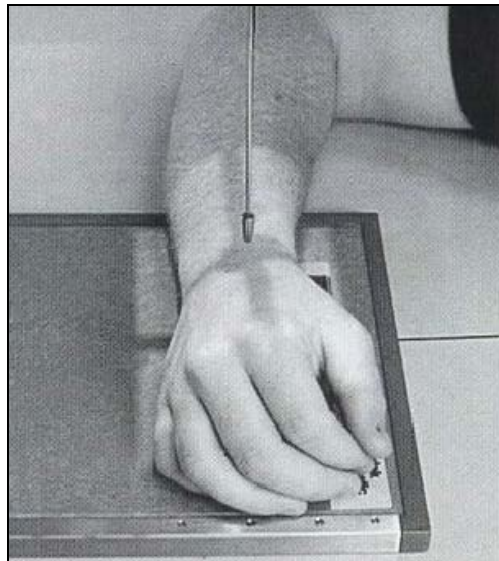
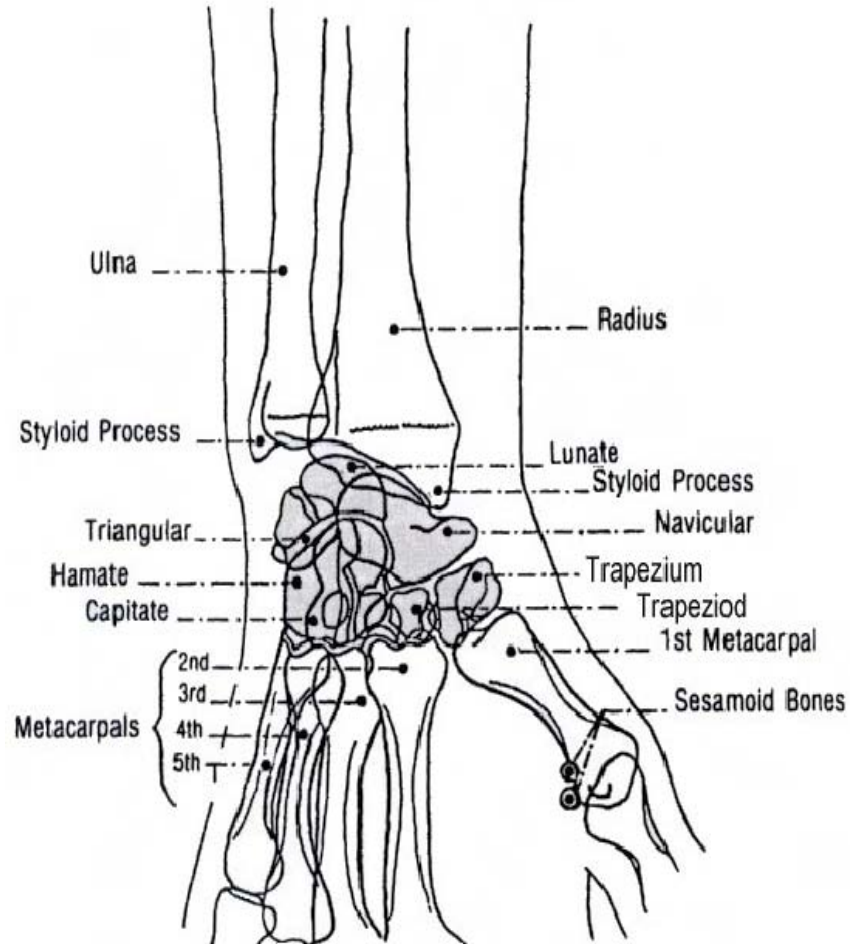
i. **Collimation:** Collimate on all four sides of wrist, including distal radius, ulna, and metacarpal area

j. **Immobilization: Pre exposure instructions:** Hold still; don't move

k. **Shielding:** Place lead shield over patient's lap to shield gonads.

l. **Demonstrates:** Mid and proximal metacarpals, carpals, distal radius, ulna and associated joints of the wrist in the true PA position.

## 5-10. OBLIQUE WRIST



## THE ORDER OF THE PROCEDURE

a. **Remove artifacts.**

b. **Measure part.**

c. **Set control panel.**

d. **Technical Factors:** Film size-10 x 12" (24 x 30 cm) crosswise

1. Divide film in half crosswise
2. Detail screen table top
3. 60 kVp range

e. **LM:**

f. **Patient/Part position:** Patient seated at end of table with elbow flexed about 90 degrees with hand and wrist resting on cassette, palm down.

1. Drop shoulder or raise table height so shoulder, elbow and wrist are on the same horizontal plane.
2. Align hand and wrist to the center of, and to the long axis of the unmasked half of the cassette.
3. From pronated position rotate hand and wrist laterally 45 degrees.
4. For stability place a 45 degree support under the thumb side of hand to support hand and wrist in a 45 degree oblique position, or partially flex fingers to arch hand and lightly rest fingertips on cassette.

g. **CR:** CR perpendicular to film, directed to mid carpal area.

h. **SID:** Minimum 40"

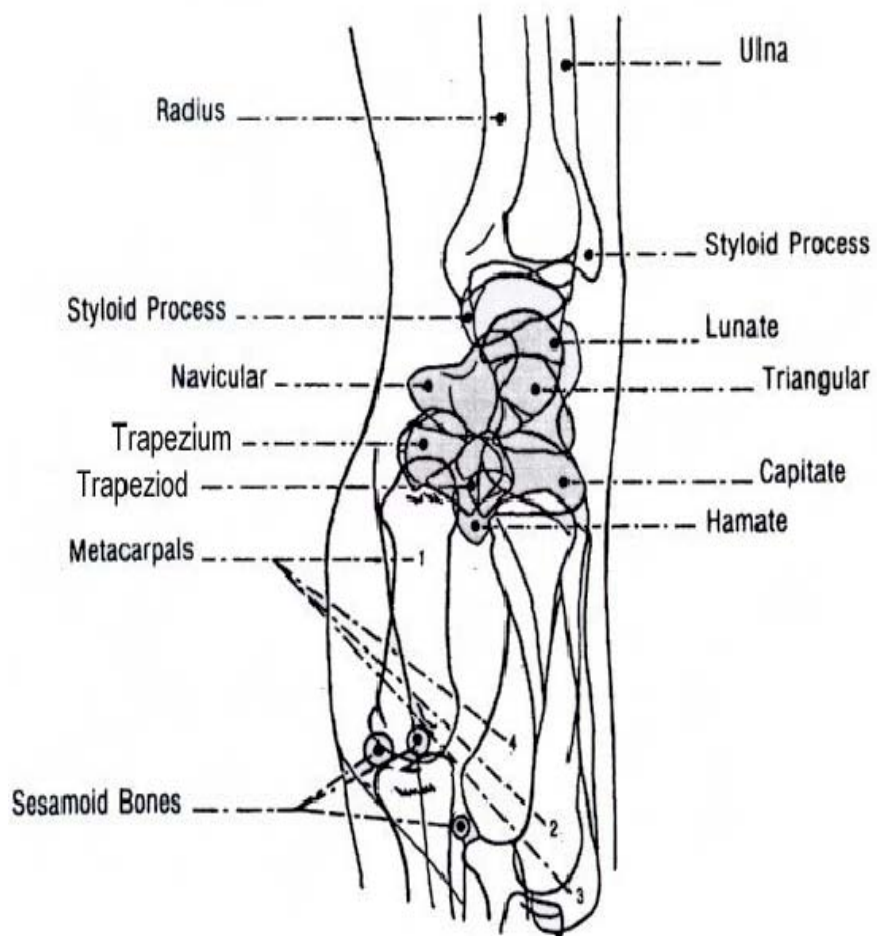
i. **Collimation:** Collimate to wrist on all four sides, include distal radius, ulna, and metacarpal area.

j. **Immobilization: Pre exposure instructions:** Hold still; don't move.

k. **Shielding:** Place lead shield over patients lap to shield gonads.

l. **Demonstrates:** Mid and proximal metacarpals, carpals, (especially trapezium and scaphoid ) distal radius, ulna and associated joints of the wrist in the true oblique position.

## 5-11. LATERAL WRIST



## THE ORDER OF THE PROCEDURE

a. **Remove artifacts.**

b. **Measure part.**

c. **Set control panel.**

d. **Technical Factors:** Film size- 10 x 12" (24 x 30 cm)

1. Divide film in half crosswise
2. Detail screen table top
3. 60 kVp range ( increase 4 kVp from PA an Oblique )

e. **LM:**

f. **Patient/Part position:** Patient seated at end of table with both arm and forearm resting on table with elbow flexed about 90 degrees and wrist and hand on cassette in thumb up lateral position.

1. Drop shoulder or raise table height so shoulder, elbow and wrist are on the same horizontal plane.
2. Align long axis of hand and forearm to center of the long axis of the cassette.
3. Adjust the hand and wrist into the true lateral position with the fingers comfortably flexed; or if support is needed to prevent motion, use a radiolucent support block and sandbag and place block against extended hand and fingers as shown.

g. **CR:** CR perpendicular to film, directed to mid wrist joint.

h. **SID:**  
Minimum 40"  
SID

i. **Collimation:** Collimate on four sides to include distal radius, ulna, and at least to mid-metacarpal area.

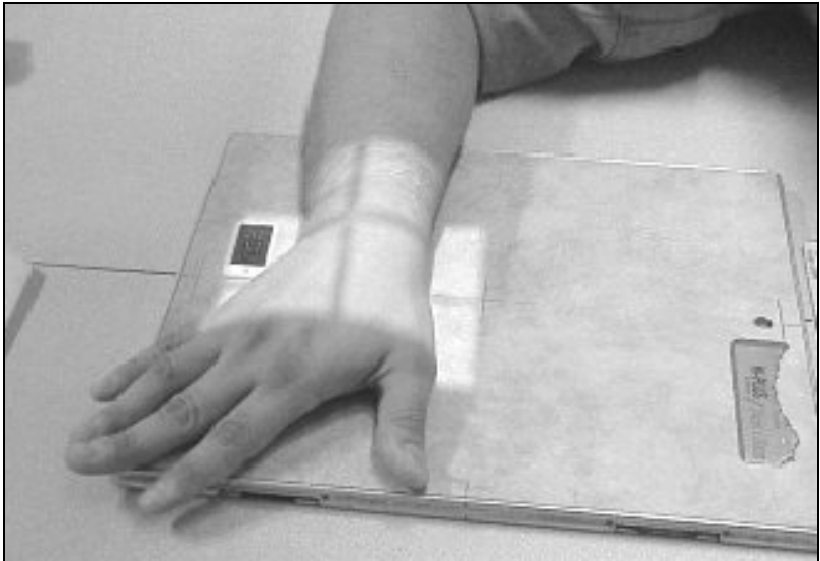
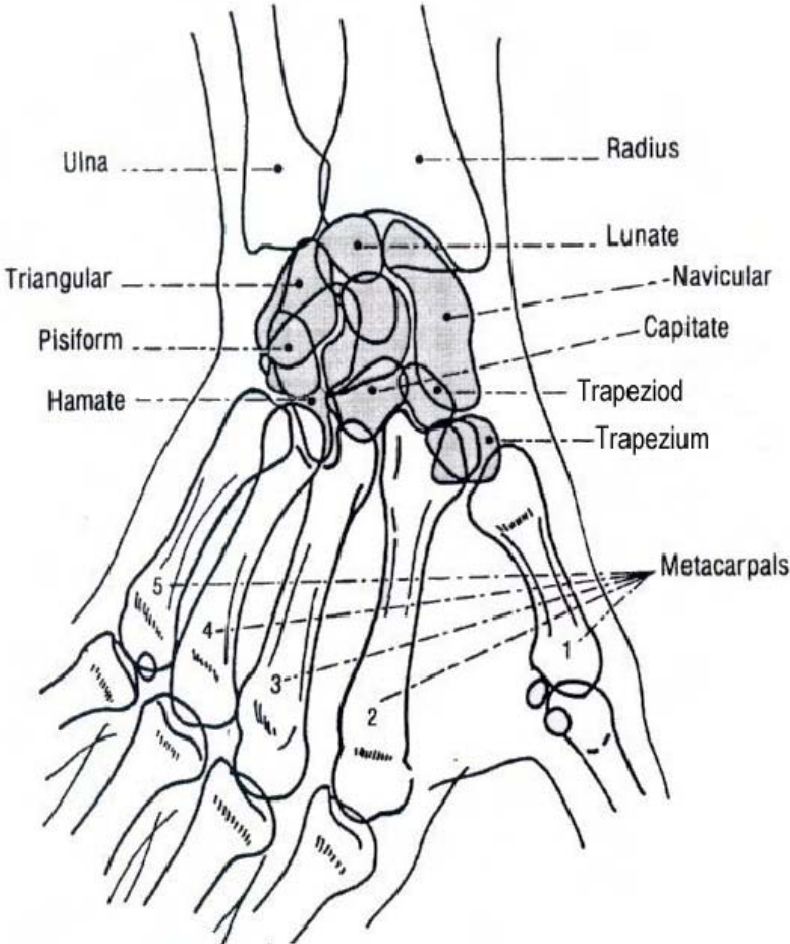
j. **Immobilization: Pre exposure instructions:** Hold still; don't move.

k. **Shielding:** Place lead shield over patient's lap to shield gonads.

l. **Demonstrates:** Superimposed proximal metacarpals, carpals, distal radius, ulna and wrist joint in the true lateral position.



5-12. POSTERANTERIOR WRIST WITH ULNAR FLEXION



## THE ORDER OF THE PROCEDURE

a. **Remove artifacts.**

b. **Measure part.**

c. **Set control panel.**

d. **Technical Factors:** Film size- 10 x 12" (24 x 30 cm)

1. Divide film in half crosswise
2. Detail screen table top
3. 60 kVp range

e. **LM:**

f. **Patient/Part position:** Patient seated at end of table with elbow flexed about 90 degrees with hand and wrist resting on cassette, palm down.

1. Drop shoulder or raise table height so shoulder, elbow and wrist are on the same horizontal plane.
2. Align long axis of hand and forearm to center of the long axis of the cassette, with carpal area to center of film.
3. With hand pronated, wrist and carpal area in close contact with cassette.
4. Without moving forearm, gently evert (move toward ulnar side, or towards 5<sup>th</sup> digit) as far as patient can tolerate without lifting or obliquing distal forearm.

g. **CR:** Angle CR 15 – 20 degrees proximally (along long axis of forearm towards elbow) to direct CR perpendicular to scaphoid.

h. **SID:**  
Minimum 40"  
SID

i. **Collimation:** Collimate on four sides to outer margins of hand and wrist.

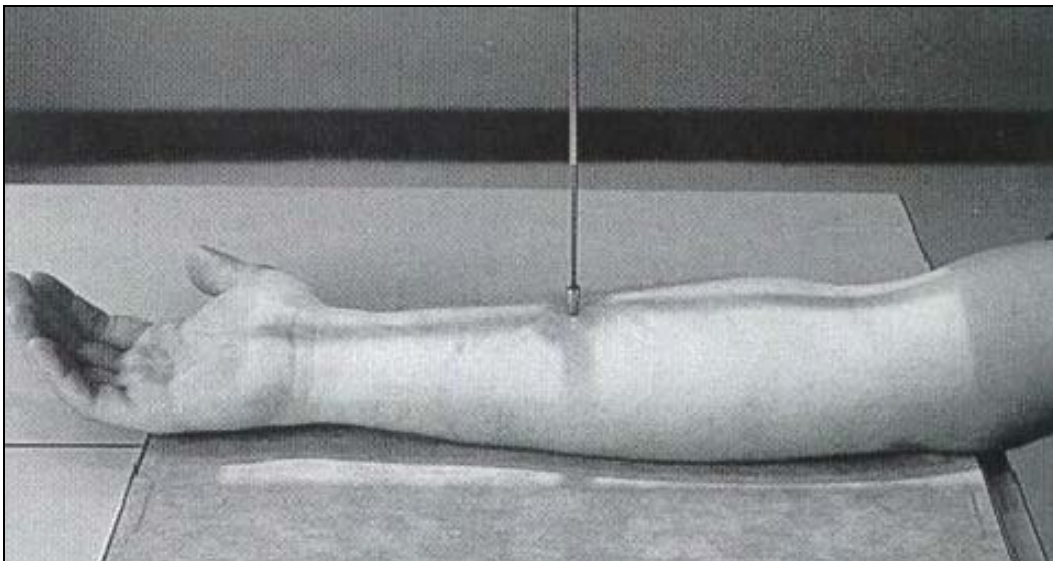
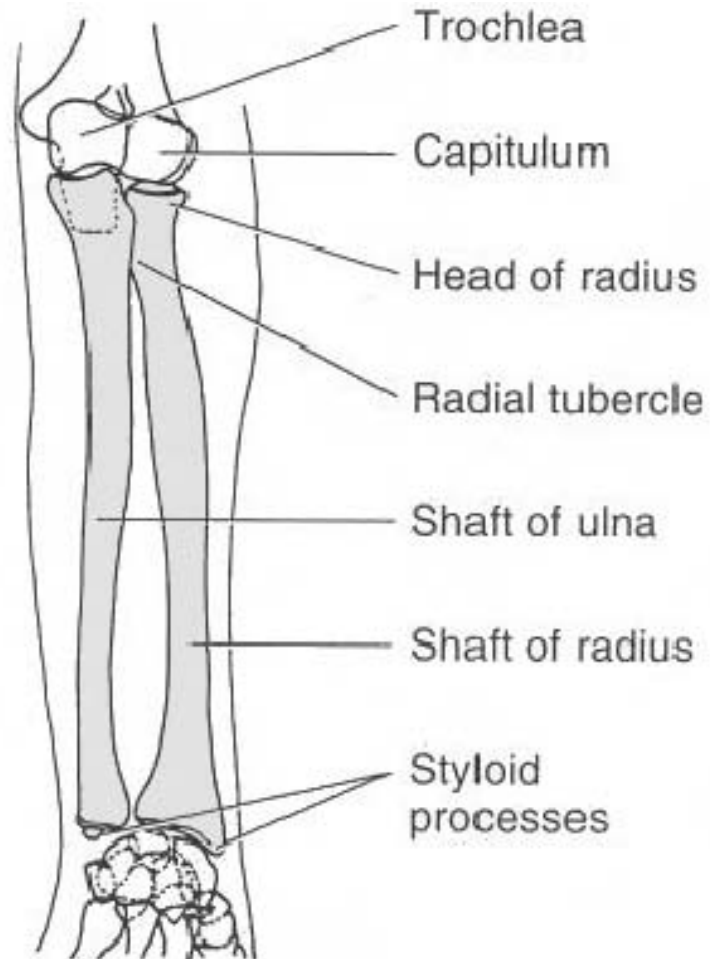
Center CR to scaphoid ( $\frac{3}{4}$  in. medial and  $\frac{3}{4}$  in. distal to the lateral styloid process).

j. **Immobilization:** : **Pre exposure instructions:** Hold still; don't move.

k. **Shielding:** Place lead shield over patients lap to shield gonads.

l. **Demonstrates:** Scaphoid without foreshortening with opened spaces between adjacent carpals. Also to a lesser degree visualizes the trapezium and trapezoid.

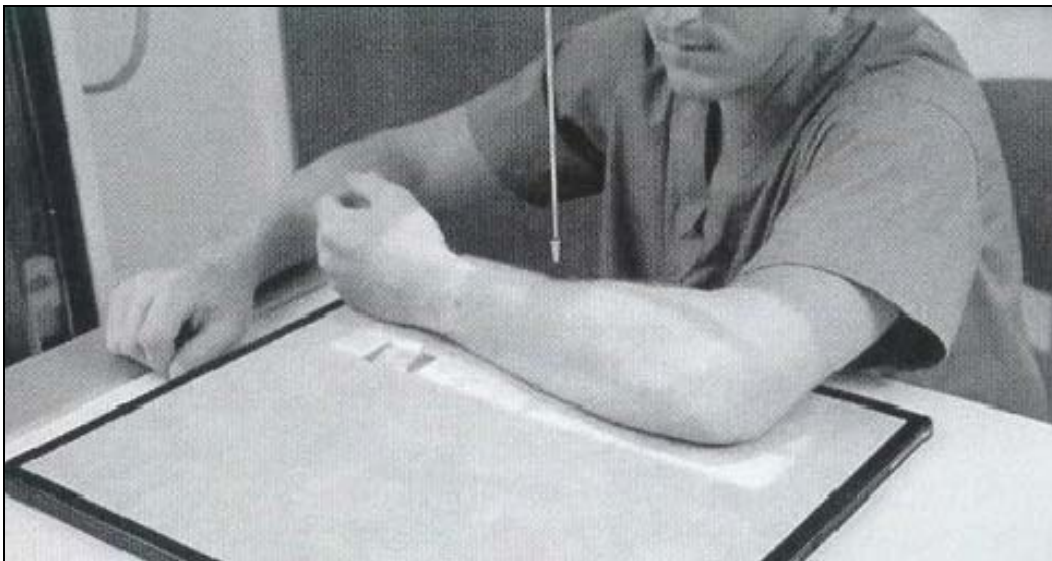
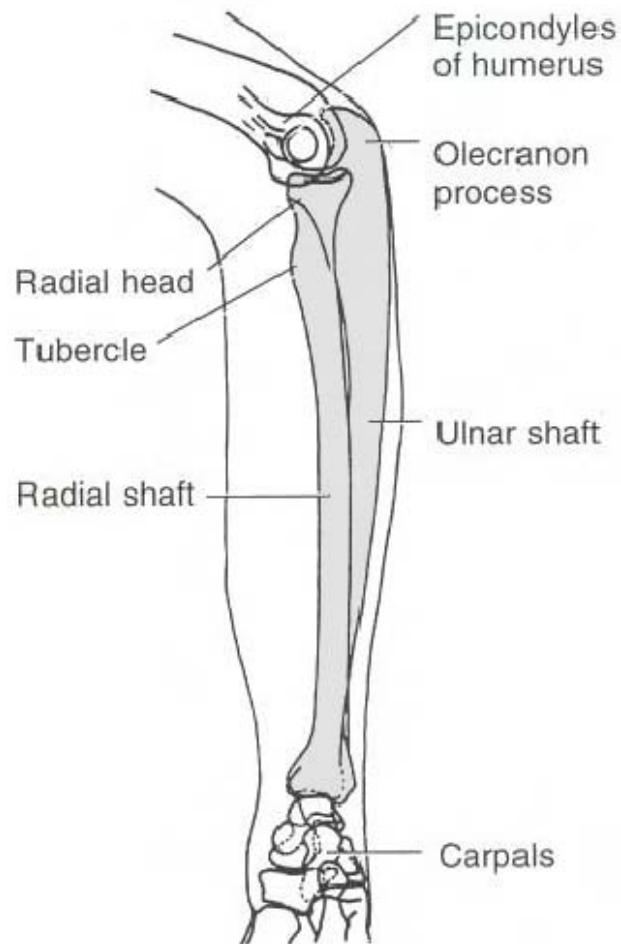
### 5-13. AP FOREARM



## THE ORDER OF THE PROCEDURE

- a. **Remove artifacts.**      b. **Measure part.**      c. **Set control panel.**
- d. **Technical Factors:** Film size-14 x 17 inches lengthwise.
- a) Divide in half lengthwise.
  - b) Detail screen, tabletop.
- e. **LM:**
- f. **Patient/Part position:** patient seated at end of table with hand and arms fully extended. (palm up or supinated).
- a) Drop shoulder to place entire upper limb on same plane.
  - b) Align and center forearm to the long axis of unmasked portion of film.
  - c) Have patient lean laterally as necessary to place entire wrist, forearm and elbow in as near a true AP position as possible. (Styloid processes and epicondyles will be equidistant to film borders).
- g. **CR:** CR perpendicular to film, directed to mid forearm.      h. **SID:** Minimum 40"      i. **Collimation:** Collimate both lateral borders to the actual forearm area; and at both ends collimate to avoid cutting off anatomy at either joint.
- Ensure that a minimum of 1" distal to wrist and 1" proximal to elbow joint are included on the film.
- j. **Immobilization:**      **Pre exposure instructions:** Hold still; don't move.
- k. **Shielding:** Place lead shield over patient's lap to shield gonads.
- l. **Demonstrates:** Entire radius and ulna, proximal row of carpals, elbow and distal end of humerus in the AP projection.

## 5-14. LATERAL FOREARM



## THE ORDER OF THE PROCEDURE

a. **Remove artifacts.**

b. **Measure part.**

c. **Set control panel.**

d. **Technical Factors:** 14 x 17" (35 x 43 cm) lengthwise.

a) Divide in half lengthwise.

b) Detail screen, tabletop.

e. **LM:**

f. **Patient/Part position:** Patient seated at the end of table with elbow flexed 90 degrees.

a) Drop shoulder to place entire upper limb on same horizontal plane.

c) Align and center forearm to the long axis of the unmasked portion of the film.

d) Rotate hand and wrist into true lateral (thumb up)

e) position and support hand to prevent motion. (Ensure that the distal radius and ulna are directly superimposed).

g. **CR:** CR perpendicular to film, directed to mid forearm.

h. **SID:**  
Minimum 40"

i. **Collimation:** Collimate both lateral borders to the actual forearm area; and at both ends collimate to avoid cutting off any Anatomy at the joints.

Ensure that 1" distal to wrist and 1" proximal to elbow joint are included on the film.


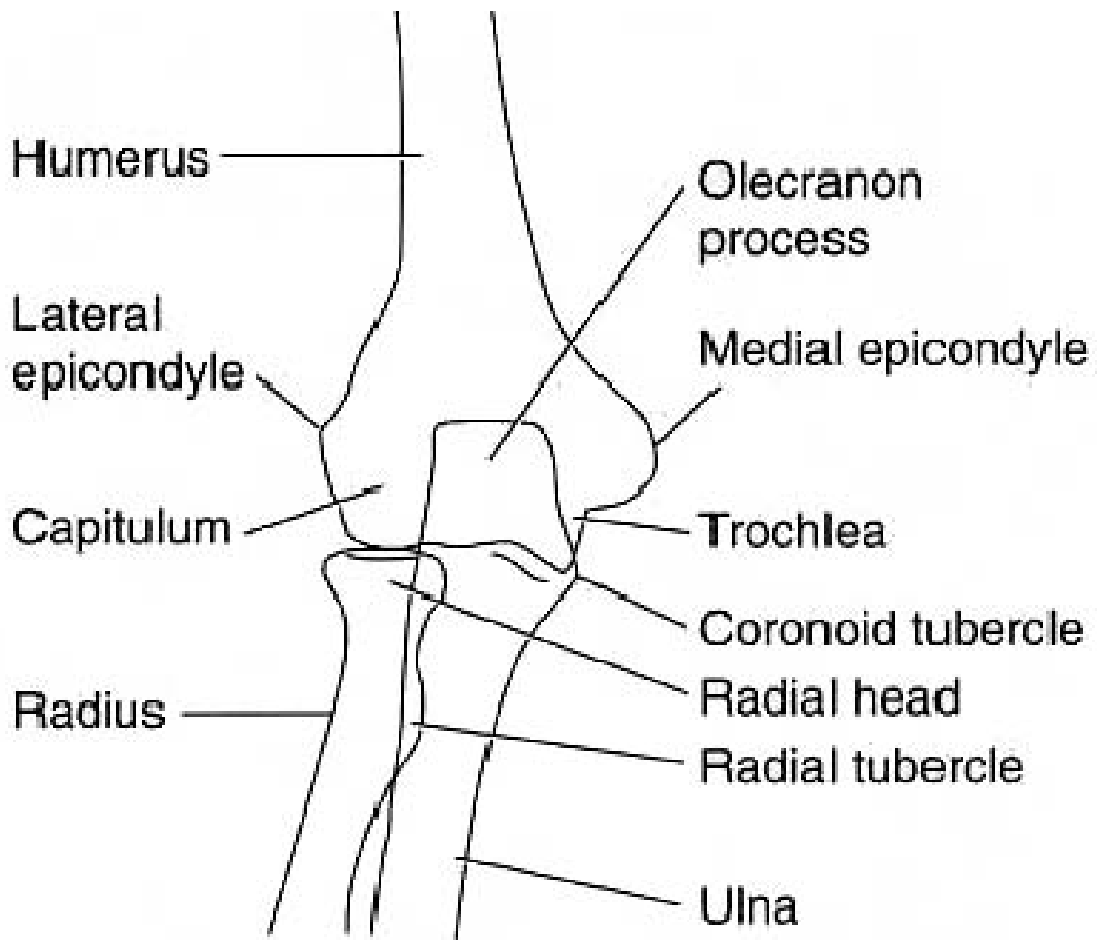
j. **Immobilization: Pre exposure instruction:** Hold still; don't move.

k. **Shielding:** Place lead shield over patient's gonads.

l. **Demonstrates:** Entire radius and ulna, proximal row of carpals, elbow and distal humerus in lateral projection.

### Section III. THE ELBOW

#### 5-15. ANTEROPOSTERIO ELBOW

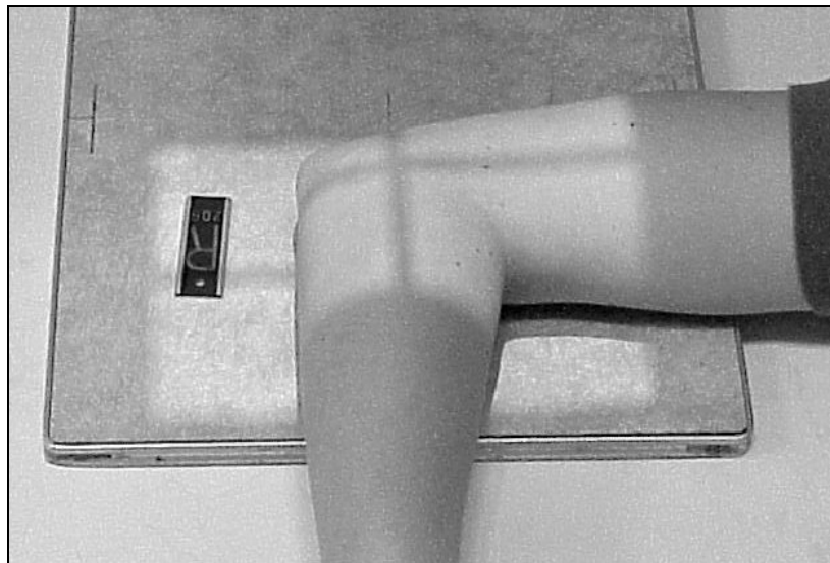
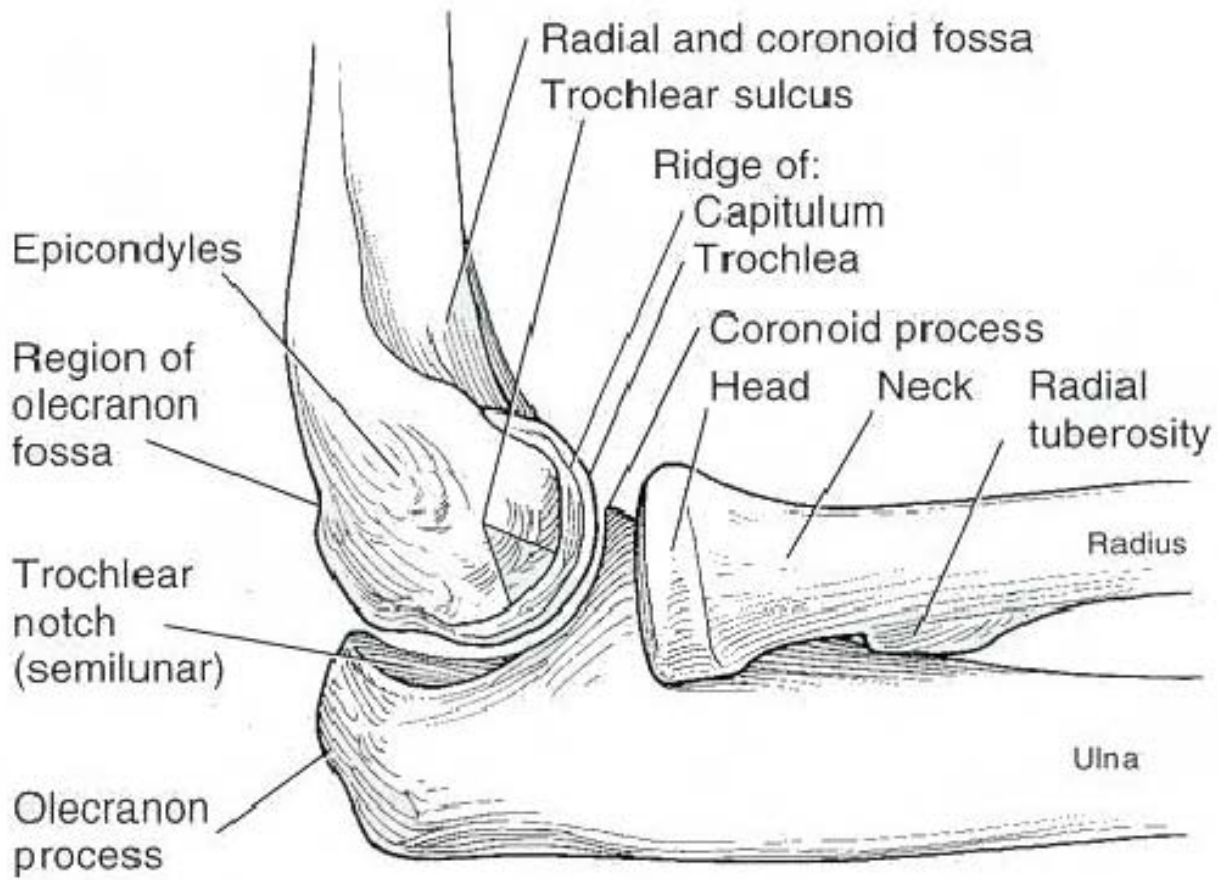


## THE ORDER OF THE PROCEDURE

- a. **Remove artifacts.**                      b. **Measure part.**                      c. **Set control panel.**
- d. **Technical Factors:** Film size-10 x 12" (24 x 30 cm) crosswise.
- a) Divide in half crosswise.
  - b) Detail screen, tabletop.
- e. **LM:**
- f. **Patient/Part position:** Patient seated at end of table with elbow fully extended, wrist, elbow and shoulder on same horizontal plane.
- a) Fully extended: Extend elbow, supinate hand and align arm and forearm to center of unmasked portion of film.
  - b) Ensure elbow joint is to center of unmasked film.
  - c) Have patient lean laterally as necessary for true AP Projection, Epicondyles must be parallel to film.
  - d) Palpate epicondyles to ensure equal distance from film borders and support hand as necessary to prevent motion.
- g. **CR:** CR perpendicular to film, directed to mid elbow joint. Which is midpoint of a line between epicondyles.
- h. **SID:** Minimum 40in. (102 cm) SID.
- i. **Collimation:** On all four sides to area of interest.
- j. **Immobilization: Pre Exposure instruction:** Hold still; don't move.
- k. **Shielding:** Secure lead shield at waist to protect patient's gonads.
- l. **Demonstrates:** Distal humerus, elbow joint space, and proximal radius and ulna in the AP projection.



5-16. LATERAL ELBOW



## THE ORDER OF THE PROCEDURE

a. **Remove artifacts.**

b. **Measure part.**

c. **Set control panel.**

d. **Technical Factors:** Film size-10 x 12" (24 x 30 cm) crosswise.

- a) Divide in half crosswise.
- b) Detail screen, tabletop.

e. **LM:**

f. **Patient/Part position:** Patient seated at the end of the table with elbow flexed at 90 degrees.

- a) Center elbow joint to center of film with forearm extended off of lateral border.
- b) Ensure epicondyles are perpendicular to center of unmasked portion of film.
- c) Drop shoulder so humerus and forearm are on same plane.
- d) Rotate hand and wrist in true lateral position, thumb side up.

g. **CR:** CR perpendicular to the film directed to mid elbow joint (mid epicondyles).

h. **SID:**  
Minimum 40 in  
(102cm)

i. **Collimation:** Collimate on four sides to area of interest

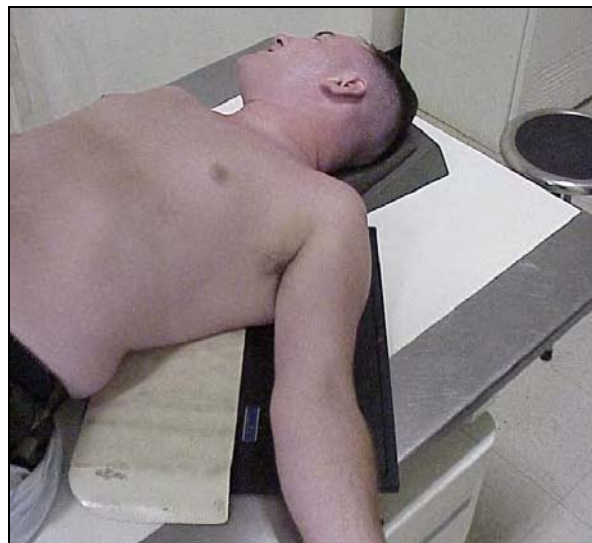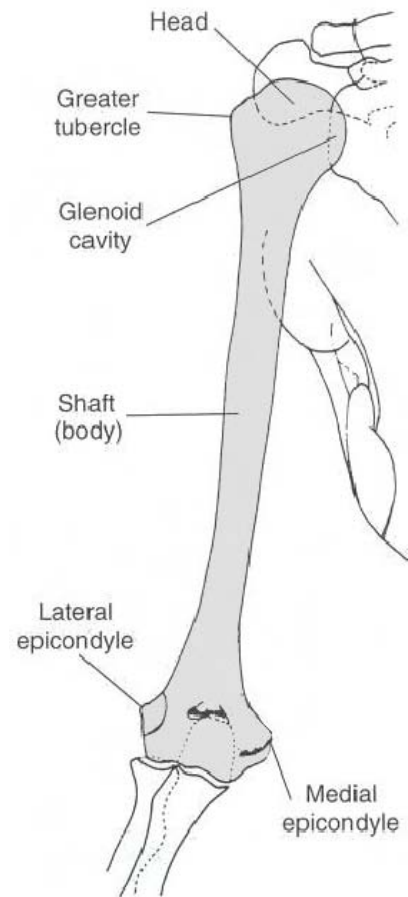
j. **Immobilization:** Pre exposure instructions: Hold still; don't move

k. **Shielding:** : Secure lead shield at waist to protect patient's gonads.

l. **Demonstrates:** Lateral view of distal humerus and proximal forearm. Clearly visualizes olecranon process with epicondyles superimposed.

## Section IV. THE HUMERUS

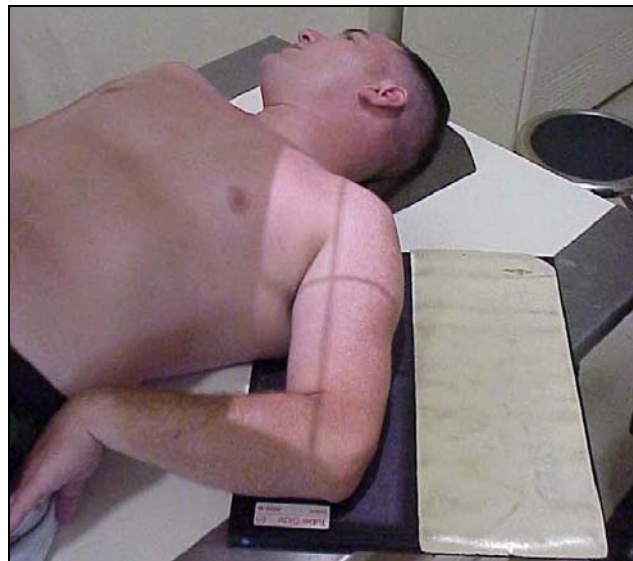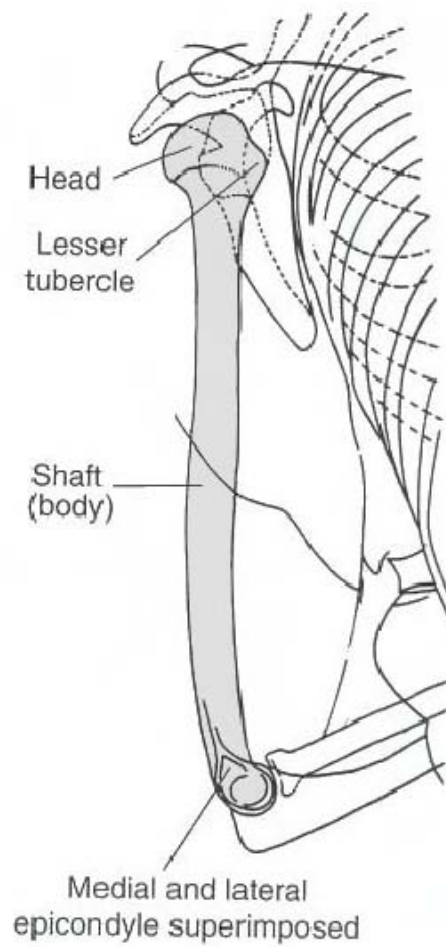
### 5-17. FULL LENGTH AP HUMERUS



## THE ORDER OF THE PROCEDURE

- a. **Remove artifacts.**                      b. **Measure part.**                      c. **Set control panel.**
- d. **Technical Factors:** Film Size: Half of a 14 x 17" (35 x 43 cm) LW
- a) NB
  - b) Minimize anode-heel effect if possible
- e. **LM:** Place corresponding LM on cassette
- f. **Patient/Part position:** Patient spine or Erect the shoulder and elbow joints are the same distance from ends of the film
- a) Rotate body toward affected side as needed to bring the shoulder and proximal humerus in contact with cassette
  - b) Align humerus to long axis of the unmasked half of film, unless diagonal placement is needed to include both shoulder and elbow joints
  - c) Extend hand and forearm as far as can be tolerated
  - d) Abduct arm slightly and gently supinate hand so that epicondyles of elbow are parallel to the film
- g. **CR:** CR perpendicular to film, directed to midpoint of humerus
- h. **SID:** 40"
- i. **Collimation:** Collimate on four sides to soft tissue borders of humerus.
- Collimation field should include both joints and up to 1" of the proximal forearm
- j. **Immobilization:** Sandbag in palm of hand
- k. **Respiration:** Suspend respiration during exposure
- l. **Shielding:** Secure or place lead shield over pelvic area
- m. **Demonstrates:** Frontal view of entire humerus to include the Proximal Humerus, Greater tuberosity, Lesser tuberosity, Surgical neck, Glenoid Fossa, Coracoid Process, AC Articulation, Distal Humerus, Condyles, Epicondyles, Shaft of humerus, Proximal Forearm, Radius and the Ulna

## 5-18. FULL LENGTH LATERAL HUMERUS

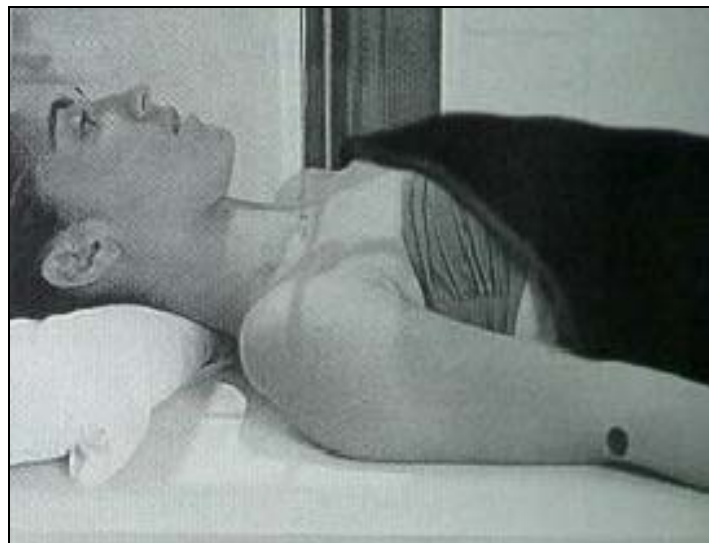
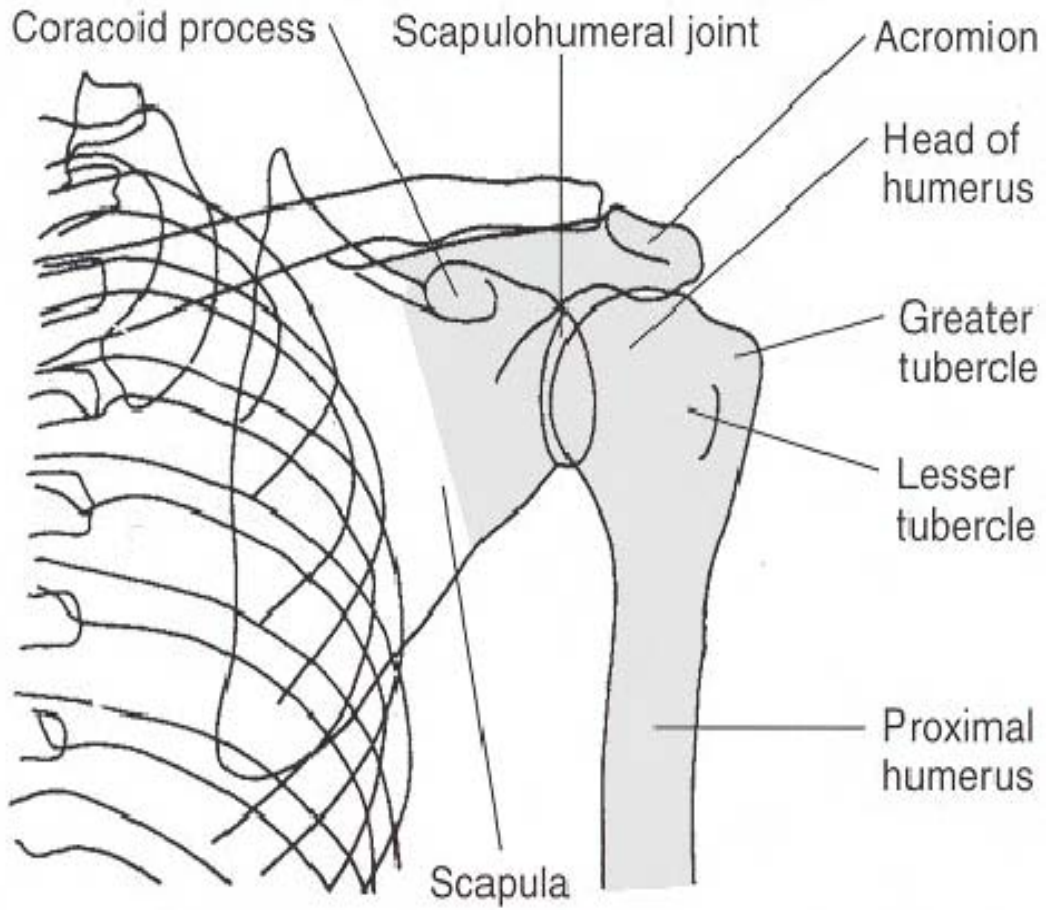


## THE ORDER OF THE PROCEDURE

- a. **Remove artifacts.**                      b. **Measure part.**                      c. **Set control panel.**
- d. **Technical Factors:** Film Size: Half of a 14 x 17" (35 x 43 cm) LW
- a) NB
  - b) Minimize anode-heel effect if possible
- e. **LM:** Place corresponding LM on cassette
- f. **Patient/Part position:** Supine or erect Shoulder and elbow joints are the same distance from ends of the film
- a) Rotate body toward affected side as needed to bring the shoulder and proximal humerus in contact with cassette
  - b) Align humerus to long axis of the unmasked half of film, unless diagonal placement is needed to include both shoulder and elbow joints
  - c) Extend elbow, internally rotate arm into true lateral
  - d) Epicondyles should be directly superimposed as viewed from the x-ray tube for a true lateral
- g. **CR:** CR perpendicular to film, directed to mid point of humerus      h. **SID:** 40"      i. **Collimation:**  
Collimate on four sides to soft tissue borders of humerus  
Collimation field should include both joints and up to 1" of the proximal forearm
- j. **Immobilization:** Sandbag against turned out palm      k. **Respiration:** Suspend respiration during exposure
- l. **Shielding:** Secure or place lead shield over pelvic area
- m. **Demonstrates:** Lateral view of entire humerus to include the, Proximal Humerus, Greater tuberosity, Lesser tuberosity, Surgical neck, Glenoid Fossa, Coracoid Process, AC Articulation, Distal Humerus, Condyles, Epicondyles, Shaft of humerus, Proximal Forearm, Radius and the Ulna

Section V. THE SHOULDER

5-19. ANTEROPOSTERIO SHOULDER WITH EXTERNAL ROTATION



## THE ORDER OF THE PROCEDURE

a. **Remove artifacts.**

b. **Measure part.**

c. **Set control panel.**

d. **Technical Factors:** Film size – 10 x 12" (24 x 30 cm) crosswise-may be used lengthwise if injury includes proximal ½ of humerus -8 x 10" for pediatrics

Moving or stationary grid

e. **LM:**

f. **Patient/Part position:** May be taken erect or supine (erect is usually less painful for patient if condition allows).

Rotate body slightly toward affected side if necessary to place shoulder in contact with cassette or tabletop (approximately 15-20 degrees)

Position patient so that top of film is 2 in (5 cm) above top of shoulder (acromion process) and coracoid process is over midline of cassette.

Abduct extended arm slightly, then **externally rotate arm** (supinate hand) until epicondyles of distal humerus are **parallel** to the film.

g. **CR: Perpendicular** to film, directed to center of cassette

h. **SID :**  
Minimum 40 in.  
(102 cm) SID

i. **Collimation:** On all four sides, with lateral and upper borders adjusted to soft tissue margins.

j. **Immobilization:** Sandbag in palm of hand

k. **Respiration:** Suspend respiration during exposure

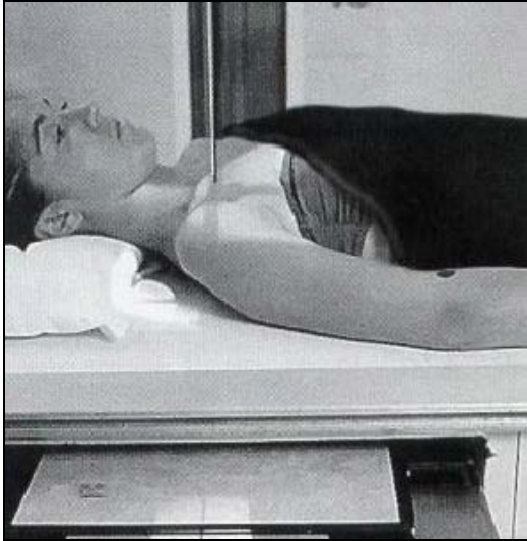
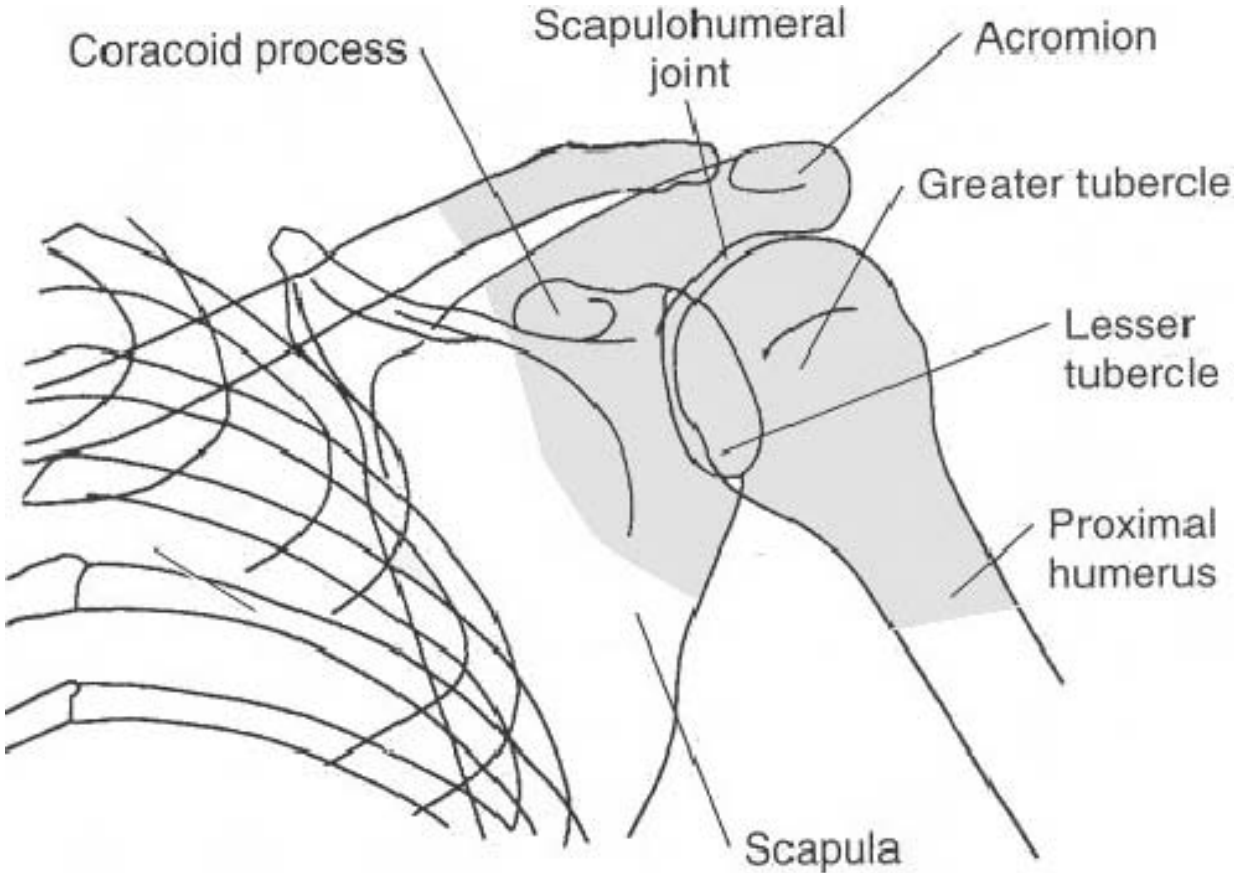
k. **Shielding:** Secure lead shield at waist to shield pelvic area.

l. **Demonstrates:** Frontal view of proximal humerus and lateral 2/3 of the clavicle and upper scapula, to include the relationship of humeral head to glenoid cavity.

Possible calcium deposits in muscles, tendons or bursal structures.



5-20. ANTEROPOSTERIO SHOULDER WITH INTERNAL ROTATION



## THE ORDER OF THE PROCEDURE

a. **Remove artifacts.**

b. **Measure part.**

c. **Set control panel.**

d. **Technical Factors:** Film size – 10 x 12" (24 x 30 cm) crosswise may be used lengthwise if injury includes proximal ½ of humerus - 8X10 for pediatrics  
Moving or stationary grid

e. **LM:**

f. **Patient/Part position:** May be taken erect or supine (erect is usually less painful for patient if condition allows).

- a) Rotate body slightly toward affected side if necessary to place shoulder in contact with cassette or tabletop (approximately 15-20 degrees).
- b) Position patient so that top of film is 2 inches (5 cm) above top of shoulder (**acromion process**) and the coracoid process is over the midline of the cassette.
- c) Abduct extended arm slightly, then **internally rotate arm** (pronate hand) until epicondyles of distal humerus are **perpendicular** to the film.

g. **CR:** CR **perpendicular** to film, directed over **coracoid process**.

h. **SID:**  
Minimum 40 in.  
(102 cm) SID

i. **Collimation:** On all four sides, with lateral and upper borders adjusted soft tissue margins.

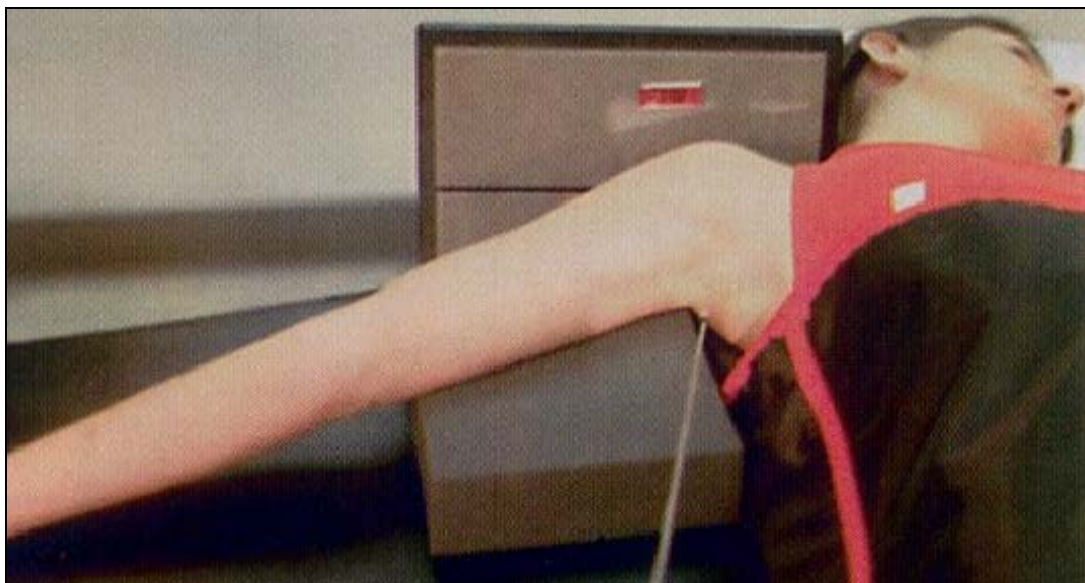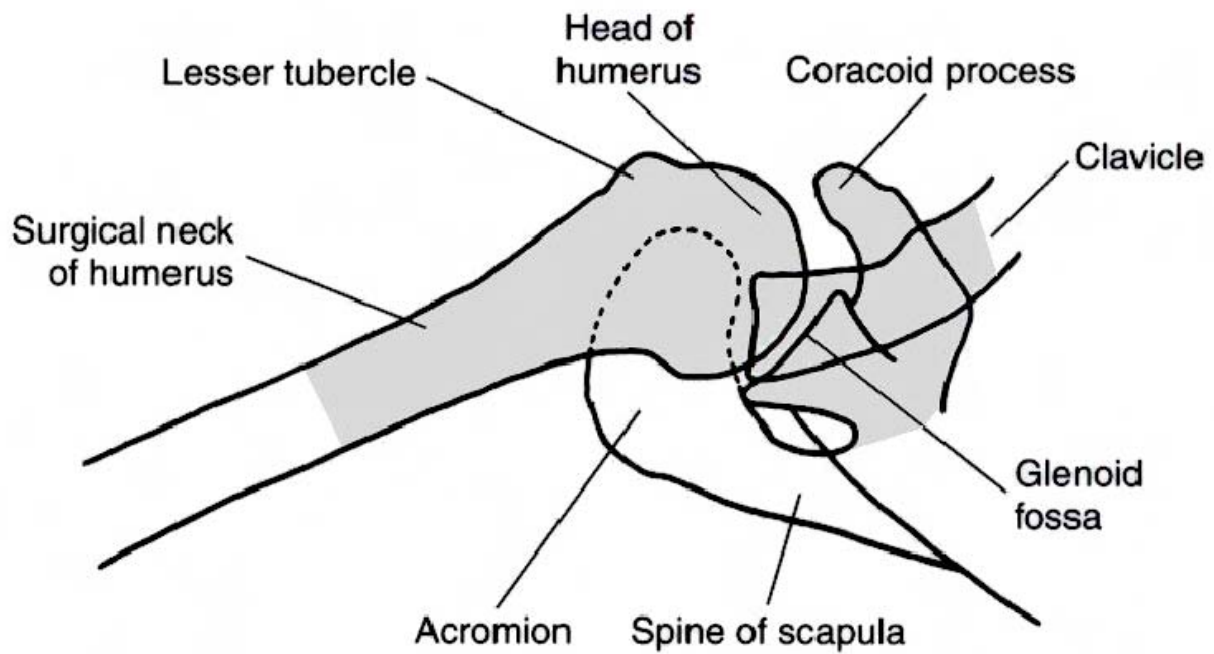
j. **Immobilization:** Sandbag against turned out palm

k. **Respiration:** Suspended respiration during exposure.

l. **Shielding:** Secure lead shield at waist to shield pelvic area.

m. **Demonstrates:** Lateral view of proximal humerus and lateral 2/3 of the clavicle and upper scapula, to include the relationship of humeral head to glenoid cavity.  
Possible calcium deposits in muscles, tendons or bursal structures.

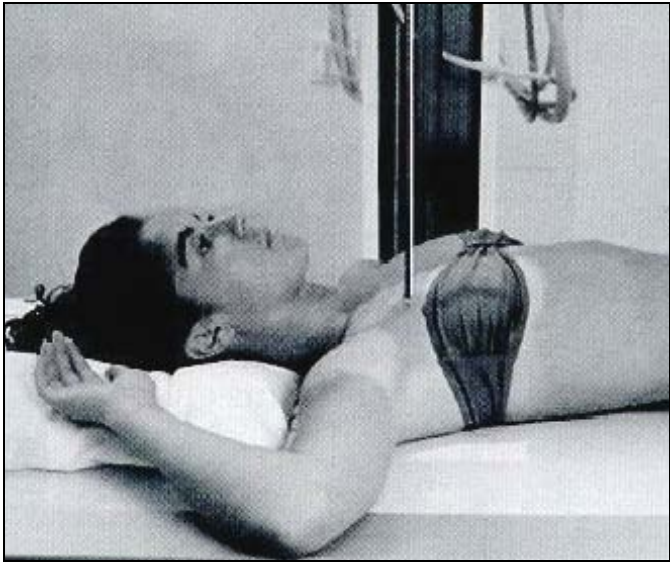
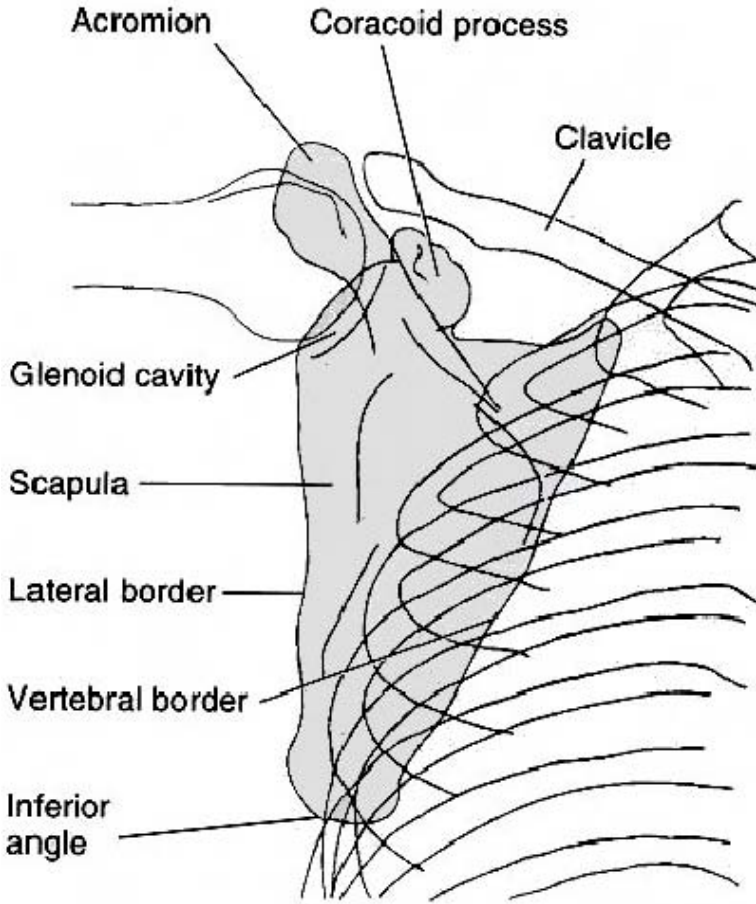
## 5-21. INFERIORSUPERIOR AXIAL PROJECTION OF SHOULDER





Section VI. THE SCAPULA

5-22. ANTEROPOSTERIO SCAPULA



## THE ORDER OF THE PROCEDURE

a. **Remove artifacts.**

b. **Measure part.**

c. **Set control panel.**

d. **Technical Factors:**

1. Film size: 10 x 12" (24 x 30 cm) LW
2. Bucky
3. Minimum of 3 sec. exposure time with breathing technique

e. **LM:**

f. **Patient/Part position:** Erect or supine

1. Posterior surface of shoulder in direct contact with table top without rotation of thorax
2. Position patient so that the center point of the film is to mid-scapula area, which is 2" inferior to the coracoid process
3. Gently abduct arm 90 degrees and supinate hand

g. **CR:** Direct CR to mid-scapula, 2" inferior to coracoid process, perpendicular to film

h. **SID:** 40" to the Bucky

i. **Collimation:** Collimate on four sides to area of scapula

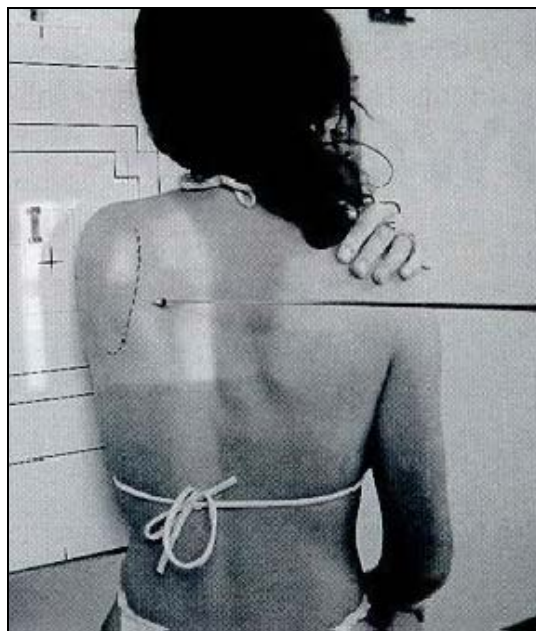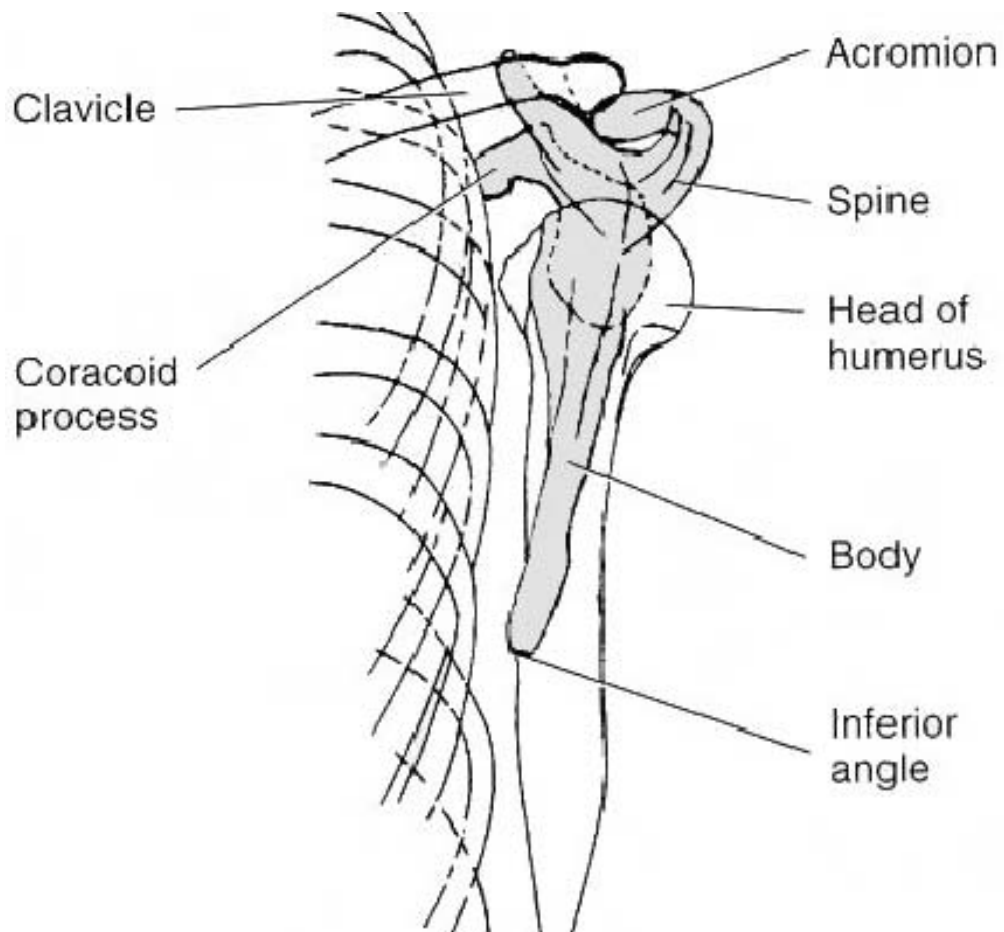
j. **Immobilization:**

k. **Respiration:** Breathing technique is preferred if patient can cooperate, ask patient to gently breathe short shallow breaths without moving affected shoulder or arm.

l. **Shielding:** Place gonadal shield over pelvic area

m. **Demonstrates:** Frontal view of scapula with lateral border free from rib superimposition

### 5-23. LATERAL SCAPULA



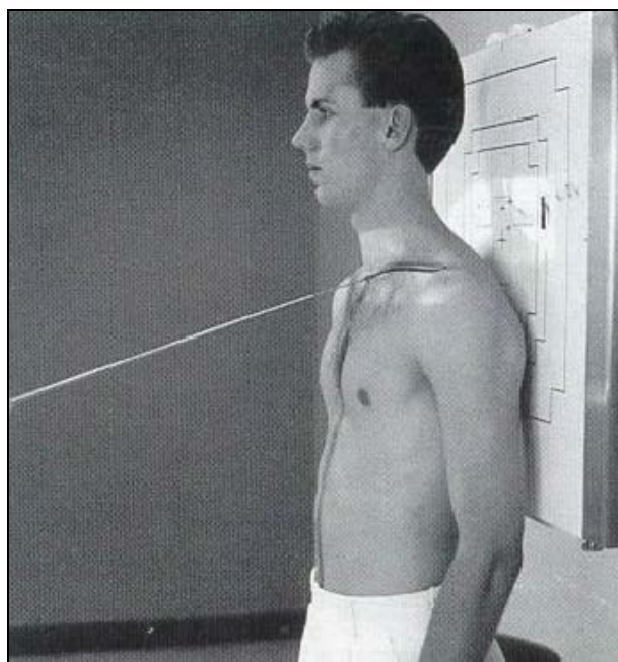
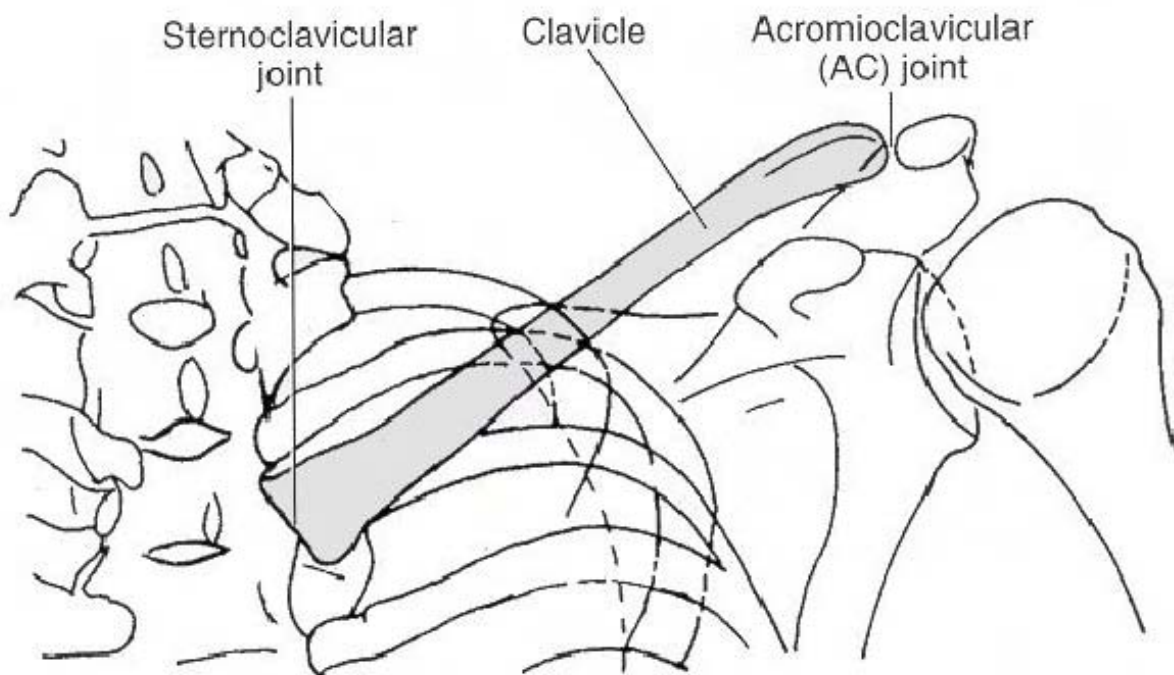
## THE ORDER OF THE PROCEDURE

- a. **Remove artifacts.**                      b. **Measure part.**                      c. **Set control panel.**
- d. **Technical Factors:** Films size: 10 x 12" (24 x 30 cm) LW, Bucky
- e. **LM:**
- f. **Patient/Part position:** Erect or recumbent position
1. Patient facing cassette in an anterior oblique position
  2. Have patient reach across front of chest and grasp opposite shoulder
  3. Palpate borders of scapula and rotate patient until the scapula is in a true lateral position
  4. The average patient will be rotated 30 to 40 degrees from the lateral position
  5. Align scapula to midline of cassette
- g. **CR:** Direct CR to mid vertebral border of scapula, perpendicular to film                      h. **SID:** 40" to the Bucky                      i. **Collimation:** : Collimate to area of scapula
- j. **Immobilization:**                      k. **Respiration:** Suspend respiration during exposure
- l. **Shielding:** Secure gonadal shield around waist
- m. **Demonstrates:** Lateral scapula projected clear of the rib cage  
A fracture of the body of the scapula is best demonstrated in this position



## Section VII. THE CLAVICAL AND ACROMIOCLAVICULAR JOINTS

### 5-24. ANTEROPOSTERIO CLAVICAL



## THE ORDER OF THE PROCEDURE

a. **Remove artifacts.**

b. **Measure part.**

c. **Set control panel.**

d. **Technical Factors:** Film size: 10 x 12" (24 x 30 cm) CW, Bucky

e. **LM:**

f. **Patient/Part position:** Patient erect or supine with arms at sides

1. Posterior surface of shoulder should be in contact with cassette on table top, without rotation of body
2. Center clavicle to center of cassette considering cephalic CR angle
3. Chin raised looking straight ahead

g. **CR:** CR to mid-clavicle, AP - 20 degrees cephalic

h. **SID:** 40" to the Bucky

i. **Collimation:** : Collimate to area of clavicle, ensuring that both the acromioclavicular and sternoclavicular joints are included

j. **Immobilization:**

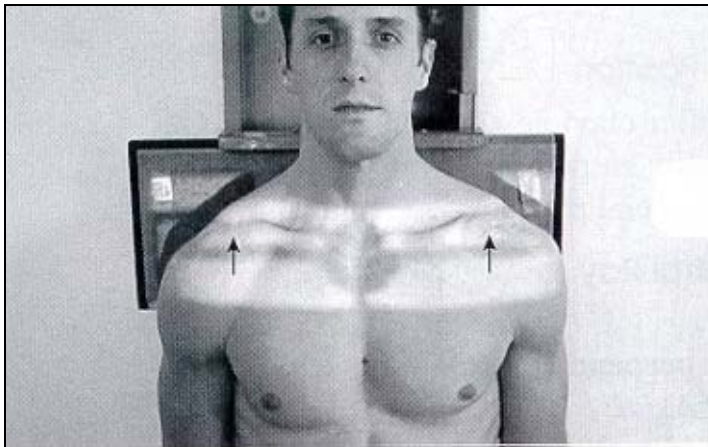
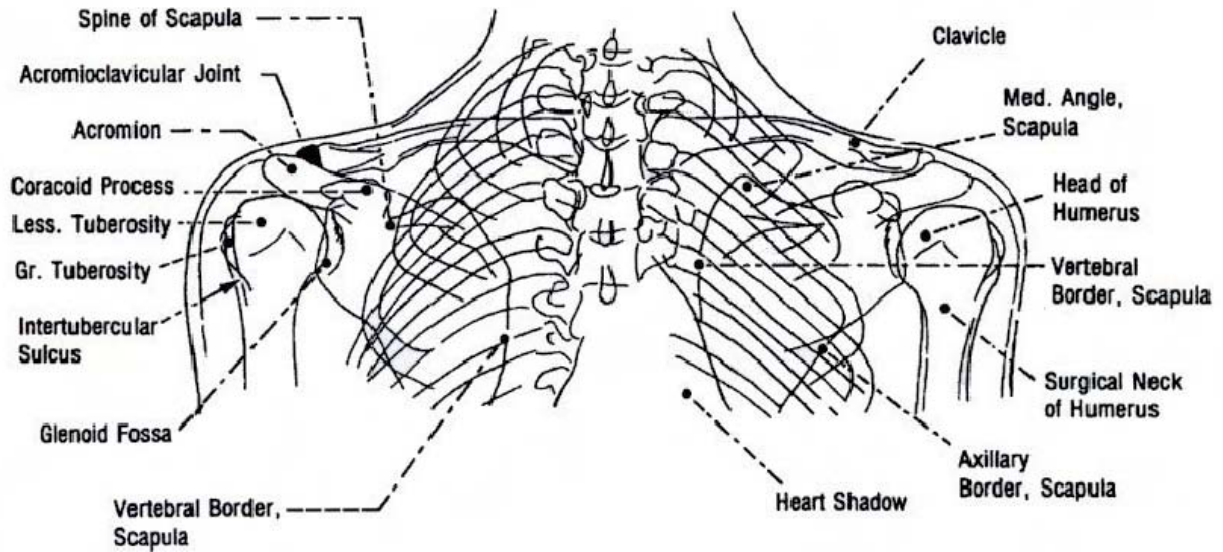
k. **Respiration:** Suspend respiration at end of exhalation

l. **Shielding:** Place gonadal shielding over pelvic area

m. **Demonstrates:** Clavicle, Acromioclavicular joint and the Sternoclavicular joint

## 5-25. ACROMIOCLAVICULAR JOINTS

### Acromioclavicular Joints (with and without weights)



W/O WEIGHTS



WITH WEIGHTS

## THE ORDER OF THE PROCEDURE

- a. **Remove artifacts.**                      b. **Measure part.**                      c. **Set control panel.**
- d. **Technical Factors:** Film size: One 14 x 17" (35 x 43 cm) CW, divided in half
- a) Non-Bucky
  - b) For broad shouldered patients, use two 8 x 10" cassettes CW placed side by side and exposed simultaneously to include both AC joints on one exposure
- e. **LM:** Place corresponding LM and "WW/WOW" marker on cassette
- f. **Patient/Part position:** Erect, posterior surface of shoulders against unmasked half of cassette with equal weight on both feet
- a) Arms at side, no rotation of shoulders or pelvis, looking straight ahead
  - b) With both shoulders against cassette, adjust height to place the center of the unmasked half of the cassette to the level of the AC joints
- g. **CR:** HP, direct CR to mid point between AC joints perpendicular to film                      h. **SID:** 72" Non-Bucky                      i. **Collimation:** : Collimate with a long narrow light field to area of interest (7 x 17")
- j. **Immobilization:**                      k. **Respiration:** Suspend respiration during exposure
- l. **Shielding:** Secure gonadal shield around waist
- m. **Demonstrates:** Both AC joint spaces
- Note: For the "with weights" position, you need to place equal weights in the patient's hands to pull the shoulders down (usually 5 lbs.)

**Continue with Exercises**

## EXERCISES, LESSON 5

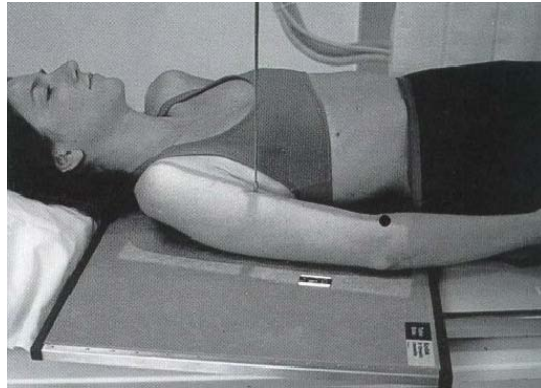
**MULTIPLE CHOICE.** For exercises 1 through 8, select the ONE word or phrase that BEST completes the statement or BEST answers the question.

1. The correct film run down (FRD) for a PA hand is:
  - a. 8x10 CW (B).
  - b. 8x10 LW (NB).
  - c. 1/2 of 10x12 CW (NB).
  - d. 1/2 of 10x12 LW (B).
  
2. The correct central ray for an oblique hand is:
  - a. The Third MP joint to the center of the film.
  - b. The second MP joint to the center of the film.
  - c. The Styoids to the center of the film.
  - d. Mid point of the third Metacarpal to the center of the film.
  
3. While the lateral hand demonstrates a number of anatomical structures in a LAT position, the \_\_\_\_\_ is(are) shown in the true PA projection.
  - a. Phalanges.
  - b. Thumb.
  - c. Metacarpals.
  - d. Carpals.

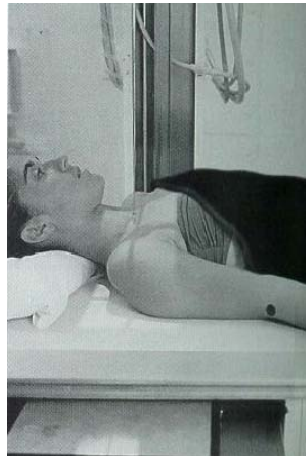4. What is the central ray for the ulnar flexion?
  - a. 15-20 degrees towards the elbow.
  - b. HP.
  - c. VPd. 15-20 degrees towards metacarpals.
  
5. The part position for the oblique wrist is:
  - a. CR perpendicular, directed to the carpal area.
  - b. The styloids parallel the film with the hand flexed the ulna; the part centered.
  - c. Patient seated at the end of the table with hand and arm fully extended.
  - d. Align hand and wrist to the center of the long axis of the cassette. From a pronated position, rotate hand and wrist laterally 45 degrees.
  
6. For an X-ray of the hand, wrist, and elbow, the CR, SID, and CF remain constant, as indicated in:
  - a. CR: VP; SID: 40"; CF: FFC.
  - b. CR: HP; SID: 45"; CF: FFC.
  - c. CR: VP; SID: 30"; CF: FFC.
  - d. CR: HP; SID: 50"; CF: FFC.

**IDENTIFICATION.** For exercises 7 through 12, the picture on the right represents the proper patient and part positioning. Indicate the name of that position in the space provided.

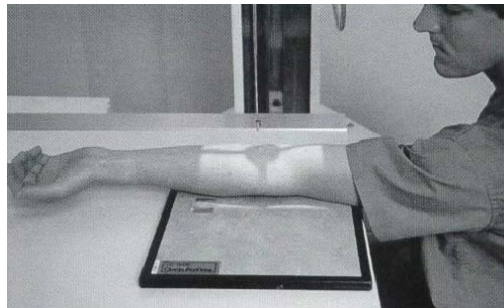
7. \_\_\_\_\_




8. \_\_\_\_\_



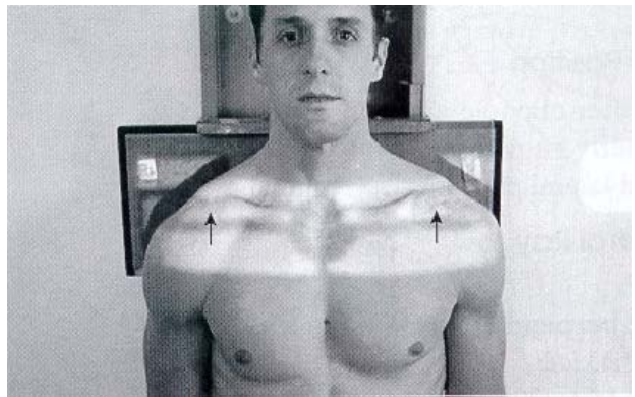
9. \_\_\_\_\_



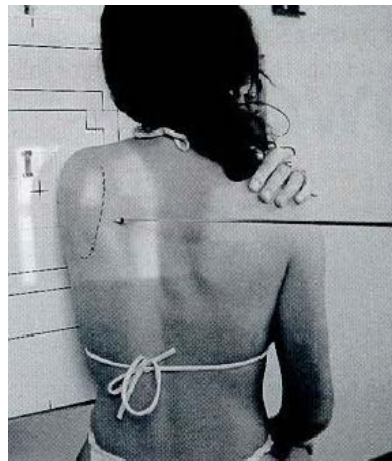10. \_\_\_\_\_



11. \_\_\_\_\_



12. \_\_\_\_\_





**MATCHING.** For exercises 13 through 18, match the position with the anatomical structure(s) that the position demonstrates. Enter the letter that corresponds to your choice in the space provided. There is one extra alternative that will not be used

- |  |   |
|--|---|
| 13. ____ AP shoulder with external rotation            | a. Possible separation of AC joints.  |
|  | b. Lateral view of the head and neck of proximal humerus.                           |
| 14. ____ Lateral scapula                               | c. Full length humerus in lat. position, lesser tubercle in profile.                |
|  | d. Oblique view of carpals.   |
| 15. ____ AP clavicle                                   | e. Lat. scapula free of rib cage.   |
| 16. ____ Inferiorsuperior axial projection of shoulder | f. Frontal view of proximal humerus and Lat. 2/3 of the clavicle and upper scapula. |
| 17. ____ Acromioclavicular joints with weights         | g. Clavicle and acromioclavicular joints.   |
| 18. ____ Lateral humerus                               |   |

**MULTIPLE CHOICE.** For exercises 19 through 24, select the ONE word or phrase that BEST completes the statement or BEST answers the question.

19. For the AP shoulder-internal rotation, the correct part position is:
- a. Shoulder joint centered, abduct extended arm slightly, then externally rotate arm until epicondyles are parallel to film.
  - b. Position patient so that the coracoids process is at mid point of cassette. Top of film 2 inches above top of shoulder; internally rotate arm until epicondyles are perpendicular to film.
  - c. Position the patient so that the coronoids are centered to the film with the epicondyles are perpendicular to the film.
  - d. Position the patient so that the coronoids are centered to the film with the epicondyles are parallel to the film.

20. For X-ray of the AP scapula, the film size, CR, SID, and CF are:
- a. Film Size: 10x12CW (NB); CR: HP; SID: 72 inches; CF: FFC.
  - b. Film Size: 14x17LW (B); CR: VP; SID: 40 inches; CF: FFC.
  - c. Film Size: 10x12LW (B); CR: VP; SID: 40 inches CF: FFC.
  - d. Film Size: 8x10LW (NB); CR: VP; SID: 40 inches; CF: FFC.
21. What breathing technique is used when radiographing an AP scapula?
- a. Suspended breathing after expiration.
  - b. Suspended breathing after inspiration.
  - c. Hold still; don't move.
  - d. Gently breathe short shallow breaths.
22. What is the angle and direction of the central ray when radiographing the PA clavicle?
- a. HP.
  - b. 20 degrees, cephalic.
  - c. 30 degrees, caudad.
  - d. 45 degrees, caudad.
23. The source to image distance for radiographing the acrioclavicular joint is:
- a. 40 inches to the Bucky.
  - b. 38 inches to the tabletop.
  - c. 40 inches to the tabletop.
  - d. 72 inches to the wall buck.

24. Which of the following is **NOT** applicable when radiographing acromioclavicular joints?
- a. Patient erect, posterior surface of the shoulder against unmask half of cassette with equal weight on both feet.
  - b. Center AC joint to center of film.
  - c. Take two views, one with weights and one without weights.
  - d. Adjust the height to place the center of the unmasked half of the cassette to the level of the AC joints.

**Check Your Answers on Next Page**

## SOLUTIONS, LESSON 5

Be sure to re-read and study the paragraph(s) pertaining to any exercises you might have answered incorrectly. The relevant paragraph(s) is (are) listed after each of the answers below.

1. c (para 5-6)
2. b (para 5-7)
3. b (para 5-8)
4. a (para 5-12)
5. d (para 5-10)
6. a (sect I, II,III )
7. Lateral humerus (para 5-18)
8. External rotation Anteroposterio shoulder (para 5-19)
9. AP elbow (para 5-15)
10. AP scapula (para5-22)
11. Acromioclavicular joints (para 5-25)
12. Lateral scapula (para 5-23)
13. f (para 5-19)
14. e (para 5-23)
15. g (para 5-24)
16. b (para 5-21)
17. a (para 5-25)
18. c (para 5-18)
19. b (para 5-20)
20. c (para 5-22)
21. d (para 5-22)
22. b (para 5-24)
23. d (para 5-25)
24. b (para 5-25)

**End of Lesson 5**

## APPENDIX

### GLOSSARY OF TERMS

#### A

**anatomic position:** point of reference for all descriptions of body part relationships; position is body erect, feet together, arms at sides, palms forward.

**angled central ray:** a central ray that forms less than a ninety degree angle with the film.

**anode:** the positive end of the X-ray tube, the target where the electrons are stopped.

**anode film distance:** see "source-to-image receptor distance."

**anterior (ventral):** refers to the front part of body or organ.

**anteriorposterior projection (AP):** a projection of the X-ray beam from an anterior surface to a posterior surface.

**artifact:** anything not intended to be imaged on the radiograph; items other than the anatomy of the patient.

**aspect:** the side or surface facing a given direction, for example, the dorsal aspect.

#### B

**base of support:** an imaginary line created by those body parts that are in contact with the floor or other horizontal surface, which keeps the body from toppling over and provides stability in movements such as lifting, pushing, or pulling.

**body alignment:** the lining up of body segments (pelvis, thorax, and head) in proper relationship to each other to maintain proper body balance.

**body position:** the manner in which the patient is placed in relation to the surrounding space; the body described in terms of the part closest to the film.

**body mechanics:** the safe and efficient use of the body in movement; proper body alignment, movement, and balance.

**Bucky (Potter-Bucky Diaphragm):** sliding tray-like device found just below the X-ray table that reduces secondary (scatter) radiation reaching the film.

## C

**center of gravity:** the point around which the weight of the body is balanced (usually in the lower pelvis or abdomen, depending upon body build).

**cathode:** the negative end of the X-ray tube; the source from which the electrons flow.

**caudad:** see "caudal."

**caudal:** refers to parts away from the head of the body.

**central:** refers to the mid area or main part of an organ.

**central ray (CR):** central or principal beam of rays emanating from the X-ray tube.

**central ray (CR) angle:** the angle and direction of the central ray in relation to the film or anatomical part.

**cephalic:** refers to parts that are toward the head of the body.

**collimation:** the limiting of a beam of radiation to the required dimensions.

**conefield:** the area of the beam of radiation striking the film.

**contrast (scale):** a noticeable difference between adjacent radiographic densities seen as varying shades of gray on the radiograph.

**coronal plane:** see "frontal plane."

**cranial:** see "cephalic."

## D

**decubitus position:** position in which the patient is lying down.

**demonstrate:** to obtain a clear radiographic image of the primary and surrounding anatomical structures that are of clinical interest.

**distal:** refers to parts farthest from the center, midline, or trunk; away from the source or beginning.

**dorsal:** see "posterior."

**dorsal decubitus position:** supine position, lying on the back.

**dorsal recumbent:** see "dorsal decubitus."

**dorsoplantar foot:** view of the back part of the foot.

**draw sheet:** a single sheet that is folded in half and placed under the patient and over the middle third of the bed; used in moving a patient who is unable to assist.

## E-F

**film (radiographic) density:** the quantity of blackness (exposure) appearing on a radiograph; a photo-radiographic property that affects image visibility; without density, contrast could not be achieved and the film would be clear.

**focal spot-to-film distance:** see "source-to-image receptor distance."

**frontal (coronal) plane:** the plane that divides the body into anterior and posterior portions.

**frontal projection:** an anteroposterior (AP) or posteroanterior (PA) projection.

**full field coverage (FFC):** total exposure of the area of the film cassette that is used; no coning down.

## G-H-I

**inferior:** see "caudal."

**in tandem with:** one behind the other.

## J-K

**kilovolt:** a unit of electromotive force equal to 1,000 volts of electricity.

**kilovoltage peak (kVp):** the very highest voltage occurring at any time during an electrical cycle; the peak kilovoltage used in making any X-ray exposure.

## L

**lateral:** refers to parts away from the median plane of the body, away from the middle of a part, or to the right or left.

**lateral decubitus:** lying on one's side.

**lateral recumbent:** see "lateral decubitus."

**line of gravity:** an imaginary vertical line that passes through the center of gravity.

## M

**medial:** refers to parts toward the median plane of the body or toward the middle of a pad.

**mesial:** see "medial."

**method:** a procedure for positioning the body with reference to anatomical landmarks, film position, and central ray to body position.

**milliamperage (mA):** the number of electrons flowing from the cathode end of the X-ray tube to the anode end of the X-ray tube, measured in thousandths of an ampere.

**milliamperere seconds (mAs):** the milliamperage (number of electrons flowing through the X-ray tube) multiplied by the duration of exposure in seconds.

## N

**normal breathing:** the patient is instructed to breathe naturally without any special self-monitoring or external prompts applied.

## O

**oblique body position:** the body part is rotated so that the frontal (coronal) plane is somewhere between a PA (or AP) and lateral projection.

**order of procedure:** a logical sequence of steps for performing preliminary steps so as to accomplish the examination as efficiently as possible.

## P

**palpation point:** anatomical structure(s) that serve as a kind of landmark or guide for correctly demonstrating the body part on the cassette.

**posterior (dorsal):** refers to the back part of the body or organ.

**projection:** the process of recording a body part on an image receptor (film); the path to the central ray from the X-ray tube to the film.



**posteroanterior (PA) projection:** a projection of the X-ray beam from a posterior surface

**projection:** to an anterior surface.

**proximal:** refers to parts nearest the center, midline, or trunk; near the beginning or source.

## Q-R

**radiograph:** an X-ray film containing an image of an anatomical structure.

**radiographic examination:** encompasses positioning the anatomical structure (body part), exposing, and processing the film.

**recumbent:** lying down or reclining.

**routine:** a series of related projections of an anatomical structure, required for right angle viewing or a general survey of the anatomical part to be demonstrated.

## S

**scale:** see "contrast."

**scatter radiation:** a form of secondary radiation created when the radiation has been deviated in direction during passage through thick body parts.

**source-to-image receptor distance (SID):** distance in inches between the X-ray tube focal spot and the film; also referred to as: anode-film distance and focal spot-film distance.

**straight central ray:** the principal beam of rays emanating from the X-ray tube forms a 90° angle with the film; may be horizontal perpendicular or vertical perpendicular.

**superior:** situated farther up, farther from the bottom of base position; also the upper surface of an organ or structure. See "cephalic."

**suspended expiration:** patient is instructed to take a deep breath, blow it all the way out, and then hold it out.

**suspended inspiration:** the patient is told to take a deep breath and hold it.

**suspended respiration:** the patient is instructed to stop breathing.

## T

**tube focal spot:** the area on the anode target where cathode electrons strike to produce X-rays.

## U-V

**ventral:** see "anterior."

**ventral decubitus:** prone, lying face down on one's abdomen.

**ventral recumbent:** see "ventral decubitus."

**view:** the image as seen from the vantage of the image receptor; the way the film "sees" the part.

**visualize:** see "demonstrate."

**voltage:** the electrical pressure, measured in volts, that causes electricity to move.

## W-X-Y-Z

**X-ray film:** emulsion composed of silver bromide crystals suspended in a gelatin substance and spread evenly upon a transparent, blue-tinted, polyester support base.

**End of Appendix**